

CLINICAL PRACTICE GUIDELINE

# 2025 ACC/AHA/HRS/ISACHD/SCAI Guideline for the Management of Adults With Congenital Heart Disease



A Report of the American College of Cardiology/American Heart Association  
Joint Committee on Clinical Practice Guidelines

Developed in Collaboration With and Endorsed by the Heart Rhythm Society,  
International Society for Adult Congenital Heart Disease,  
and Society for Cardiovascular Angiography and Interventions

## Writing Committee Members

Michelle Gurvitz, MD, MS, FACC, *Chair*  
Eric V. Krieger, MD, FACC, *Co-Vice-Chair*  
Stephanie Fuller, MD, MS, FACC, FAHA, *Co-Vice-Chair*  
Leslie L. Davis, PhD, ANP-BC, FACC, FAHA, *JC Liaison*†  
Michelle M. Kittleson, MD, PhD, FACC, *JC Liaison*†‡

Jamil A. Aboulhosn, MD, FACC, FSCAI§  
Elisa A. Bradley, MD, FACC  
Jonathan Buber, MD, FACC  
Curt J. Daniels, MD, FACC  
Konstantinos Dimopoulos, MD, MSc, PhD  
Alexander Egbe, MBBS, MPH, FACC  
Tracy R. Geffrion, MD, MPH  
Anitha John, MD, PhD, FACC, FAHA  
Paul Khairy, MDCM, PhD||  
Yuli Y. Kim, MD, FACC¶  
Jacqueline Kreutzer, MD, FACC, FAHA, FSCAI  
Matthew J. Lewis, MD, MPH  
Jonathan N. Menachem, MD  
Jeremy P. Moore, MD, MS, FACC, FHRS, CCDS, CEPS-P

Kathryn A. Osteen, PhD, RN, CMSRN, CNE#  
Puja B. Parikh, MD, MPH, FACC, FSCAI\*\*††  
Arwa Saidi, MBBCh, MEd, FACC  
Katherine B. Saliccioli, MD, FACC  
Rachel L. Schunder, MA‡‡  
Anne Marie Valente, MD, FACC, FAHA  
Rachel M. Wald, MD

Writing committee members are required to recuse themselves from voting on sections to which their specific relationships with industry and other entities may apply; see [Appendix 1](#) for recusal information.

†ACC/AHA Joint Committee on Clinical Practice Guidelines liaison.

‡Former Joint Committee on Clinical Practice Guidelines member; current member during the writing effort.

§Society for Cardiovascular Angiography and Interventions representative.

||Heart Rhythm Society representative.

¶International Society for Adult Congenital Heart Disease representative.

#Patient representative.

\*\*ACC/AHA Joint Committee on Performance Measures representative.

††Former Joint Committee on Performance Measures member; current member during the writing effort.

‡‡AHA/ACC joint staff representative.

This document was approved by the American College of Cardiology Clinical Policy Approval Committee and the American Heart Association Science Advisory and Coordinating Committee in August 2025, and the American College of Cardiology Science and Quality Committee and the American Heart Association Executive Committee in October 2025.

The American College of Cardiology requests that this document be cited as follows: Gurvitz M, Krieger EV, Fuller S, Davis LL, Kittleson MM, Aboulhosn JA, Bradley EA, Buber J, Daniels CJ, Dimopoulos K, Egbe A, Geffrion TR, John A, Khairy P, Kim YY, Kreutzer J, Lewis MJ, Menachem JN, Moore JP, Osteen KA, Parikh PB, Saidi A, Saliccioli KB, Schunder RL, Valente AM, Wald RM. 2025 ACC/AHA/HRS/ISACHD/SCAI guideline for the management of adults with congenital heart disease: a report of the American College of Cardiology/American Heart Association Joint Committee on Clinical Practice Guidelines. *J Am Coll Cardiol.* 2026;87(7):822-976.

This article has been copublished in *Circulation*.

Copies: This document is available on the websites of the American College of Cardiology ([www.acc.org](http://www.acc.org)) and the American Heart Association ([professional.heart.org](http://professional.heart.org)). For copies of this document, please contact the Elsevier Inc. Reprint Department via fax (212-633-3820) or email ([reprints@elsevier.com](mailto:reprints@elsevier.com)).

Permissions: Multiple copies, modification, alteration, enhancement, and/or distribution of this document are not permitted without the express permission of the American College of Cardiology. Requests may be completed online via the Elsevier site (<http://www.elsevier.com/about/policies/author-agreement/obtaining-permission>).

<b>Peer Review Committee Members</b>	Karen Stout, MD, FACC, <i>Chair</i> <hr/> Rafael Alonso-Gonzalez, MD, MSc Luke J. Burchill, MBBS, PhD Rachael Cordina, MBBS, PhD Stephen J. Dalgner, MD Valeria Duarte, MD Edward J. Hickey, MD Jeannette P. Lin, MD, FACC	David C. Mauchley, MD Paula Miller, MSN, RN# Andrew R. Pistner, MD, FACC Anitra W. Romfh, MD Ada C. Stefanescu Schmidt, MD, MSc, FACC, FSCAI‡ Zachary L. Steinberg, MD, FACC Daniel Tobler, MD¶ Shane F. Tsai, MD, FHRS   Fred M. Wu, MD, FACC
--------------------------------------	---	--

<b>ACC/AHA Joint Committee on Clinical Practice Guidelines Members</b>	Catherine M. Otto, MD, FACC, FAHA, <i>Chair</i> Sunil V. Rao, MD, FACC, FSCAI, <i>Chair-Elect</i> Joshua A. Beckman, MD, MS, FAHA, FACC, <i>Immediate Past Chair</i> ‡ <hr/> Anastasia Arnbruster, PHARM D, FACC‡ Vanessa Blumer, MD, FACC Leslie L. Davis, PhD, RN, ANP-BC, FACC, FAHA Sharlene M. Day, MD, FAHA Dave L. Dixon, PHARM D, FACC, FAHA Victor A. Ferrari, MD, FACC Stephen E. Fremes, MD, FACC Mario Gaudino, MD, FACC, FAHA Adrian F. Hernandez, MD, MHS Hani Jneid, MD, FACC, FAHA, FSCAI	Heather M. Johnson, MD, MS, FAHA, FACC‡ William Schuyler Jones, MD, FACC Sadiya S. Khan, MD, MSc, FACC, FAHA Michelle M. Kittleson, MD, PhD, FACC, FAHA‡ Venu Menon, MD, FACC, FAHA Debabrata Mukherjee, MD, MS, FACC, FAHA, MSCAI‡ Daniel Muñoz, MD, FACC Kristen K. Patton, MD, FACC, FAHA Garima Sharma, MD, MBBS, FACC, FAHA Daichi Shimbo, MD Boback Ziaieian, MD, PhD, FACC, FAHA‡
--	---	--

‡Former Joint Committee on Clinical Practice Guidelines member; current member during the writing effort.

**ABSTRACT**

**AIM** The “2025 ACC/AHA/HRS/ISACHD/SCAI Guideline for the Management of Adults With Congenital Heart Disease” provides recommendations to guide clinicians on the evaluation and treatment of adult patients with congenital heart disease. It incorporates new evidence to replace the “2018 AHA/ACC Guideline for the Management of Adults With Congenital Heart Disease.”

**METHODS** A comprehensive literature search was conducted with a focus on literature published from 2017 to 2024; in some instances, older literature was also collected and reviewed. Clinical studies, systematic reviews and meta-analyses, and other evidence conducted on human participants and published in English were identified from MEDLINE (via PubMed), EMBASE, the Cochrane Library, Agency for Healthcare Research and Quality, and CINAHL for selected searches.

**STRUCTURE** Recommendations from the “2018 AHA/ACC Guideline for the Management of Adults With Congenital Heart Disease” have been updated with new evidence to guide clinicians.

**TABLE OF CONTENTS**

<b>ABSTRACT</b> .....	823	<b>PREAMBLE</b> .....	831
<b>WHAT IS NEW</b> .....	825	<b>1. INTRODUCTION</b> .....	833
<b>TOP TAKE-HOME MESSAGES</b> .....	831	<b>1.1. Methodology and Evidence Review</b> .....	833
		<b>1.2. Composition of the Writing Committee</b> .....	833

1.3. Guideline Review and Approval	833	4.2.2. Congenital Mitral Stenosis, Including Shone Complex	880
1.4. Scope of the Guideline	833	4.2.3. Subaortic Stenosis	881
1.5. Class of Recommendations and Level of Evidence	836	4.2.4. Congenital Diseases of the Aortic Valve	883
<b>2. DEFINITIONS AND CLASSIFICATIONS</b>	836	4.2.5. Supravalvar Aortic Stenosis	885
2.1. Definitions	836	4.2.6. Coarctation of the Aorta	886
2.1.1. Anatomic Terms	836	<b>4.3. Right-Sided Lesions</b>	890
2.2. The ACHD Anatomic and Physiological Classification System	836	4.3.1. Ebstein Anomaly	890
2.3. Abbreviations	839	4.3.2. Valvular Pulmonary Stenosis	893
<b>3. GENERAL PRINCIPLES</b>	839	4.3.3. Management of Double-Chambered Right Ventricle	896
3.1. Care Access and Delivery in the ACHD Population	839	4.3.4. Isolated Branch Pulmonary Artery Stenosis	897
3.1.1. Transition Education and Transfer of Care	840	4.3.5. Tetralogy of Fallot	899
3.1.2. The ACHD Program and Cardiologists	841	4.3.6. Pulmonary Atresia With Intact Ventricular Septum	906
3.2. Expertise for Noncardiac Surgery	843	4.3.7. Management of Right Ventricle-to-Pulmonary Artery Conduits	906
3.3. Mental Health and Neurocognitive Assessment	844	<b>4.4. Complex Lesions</b>	909
3.4. Expertise for Cardiac Surgery and Invasive Cardiac Procedures	846	4.4.1. Dextro-Transposition of the Great Arteries	909
3.5. Management of Cyanosis	847	4.4.2. Management of CCTGA	918
3.6. Heart Failure and Transplantation	850	4.4.3. Truncus Arteriosus	920
3.6.1. Heart Failure	850	4.4.4. Double-Outlet Right Ventricle	921
3.6.2. Heart Transplantation and MCS	852	4.4.5. Fontan Palliation of Single-Ventricle Physiology	921
3.7. Genetic Syndromes Screening	853	4.4.6. Eisenmenger Syndrome	929
3.8. Reproductive Health, Pregnancy, and Contraception	855	<b>4.5. Coronary Artery Anomalies</b>	934
3.9. Ionizing Radiation Exposure	857	4.5.1. Anomalous Aortic Origin of a Coronary Artery	934
3.10. Exercise Testing and Sports	858	4.5.2. Anomalous Coronary Artery Arising From the Pulmonary Artery	936
3.10.1. Exercise Testing	858	4.5.3. Coronary Artery Fistula	937
3.10.2. Physical Activity, Exercise, and Sports Participation	859	<b>4.6. Vascular Rings and Pulmonary Artery Slings</b>	938
<b>4. SPECIFIC CONDITIONS</b>	860	<b>EVIDENCE GAPS AND FUTURE DIRECTIONS</b>	938
4.1. Shunt Lesions	860	<b>KEY WORDS</b>	970
4.1.1. Atrial Septal Defect	861	<b>REFERENCES</b>	941
4.1.2. Ventricular Septal Defect	866	<b>APPENDIX 1</b>	
4.1.3. Atrioventricular Septal Defect	870	Author Relationships With Industry and Other Entities	971
4.1.4. Anomalous Pulmonary Venous Connections	872	<b>APPENDIX 2</b>	
4.1.5. Patent Ductus Arteriosus	875	Reviewer Relationships With Industry and Other Entities	975
4.2. Left-Sided Lesions	878		
4.2.1. Cor Triatriatum Sinister	878		

**WHAT IS NEW**

**Table 1** highlights new and/or substantially revised practice-changing recommendations since the last

iteration of the guideline; it is not a comprehensive list of all updates. Some of these recommendations have corresponding footnotes not included in this table.

<b>TABLE 1 What Is New</b>			
<b>New or Revised</b>	<b>Section Title</b>	<b>2018 Recommendation</b>	<b>2025 Recommendation</b>
New	3.1.2. The ACHD Program and Cardiologists	N/A	COR 1: Patients in adult congenital heart disease (ACHD) anatomic-physiological (AP) class IA should have at least 1 evaluation by an ACHD cardiologist to develop a plan of care.
New	3.2. Expertise for Noncardiac Surgery	N/A	COR 1: In patients with ACHD AP classifications IC-D, IIB-D, and IIIA-D who undergo noncardiac procedures, postprocedural care should involve collaboration with an ACHD cardiologist to incorporate expert opinion, provide guideline-based medical therapy (GDMT), and improve outcomes.
New	3.2. Expertise for Noncardiac Surgery	N/A	COR 1: In patients with ACHD AP classifications IC-D, IIC-D, and IIIA-D, anesthesia for noncardiac procedures should be administered by, or in collaboration or consultation with, an anesthesiologist with ACHD expertise to reduce the likelihood of perioperative complications.
New	3.4. Expertise for Cardiac Surgery and Invasive Cardiac Procedures	N/A	COR 1: In patients with ACHD who undergo invasive cardiac procedures, preprocedural involvement of an ACHD cardiologist is recommended to risk-stratify the patient, determine appropriate procedure location, guide periprocedural planning and support, and assist in preprocedural clinical optimization to improve outcomes.
New	3.4. Expertise for Cardiac Surgery and Invasive Cardiac Procedures	N/A	COR 1: In patients with ACHD undergoing invasive cardiac procedures, postprocedural care should involve collaboration with an ACHD cardiologist to incorporate expert opinion, provide guideline-based therapy, and improve outcomes.
New	3.4. Expertise for Cardiac Surgery and Invasive Cardiac Procedures	N/A	COR 1: In patients with ACHD AP classifications IC-D, IIA-D, and IIIA-D, anesthesia for invasive cardiac procedures should be administered by, or in collaboration or consultation with, an anesthesiologist who has congenital heart disease expertise to reduce the likelihood of perioperative complications.
New	3.4. Expertise for Cardiac Surgery and Invasive Cardiac Procedures	N/A	COR 2a: In patients with ACHD who undergo invasive cardiac procedures for acquired cardiovascular disease, it can be beneficial for operators with expertise in procedural treatment of acquired disease to collaborate with ACHD experts.
New	Section 3.5. Management of Cyanosis is new.		
New	Section 3.6.1. Heart Failure contains all new recommendations.		
New	Section 3.6.2. Heart Transplantation and MCS contains all new recommendations.		
New	3.7. Genetic Syndromes Screening	N/A	COR 2a: In adults with congenital heart disease and a family history of congenital heart disease or clinical features associated with a genetic syndrome, referral for genetic evaluation is reasonable to guide management.
New	3.8. Reproductive Health, Pregnancy, and Contraception	N/A	COR 2a: For patients with ACHD who are considering assisted reproductive technology, discussions involving an ACHD cardiologist can be beneficial to increase patients' knowledge about their options and the associated risks.
New	3.8. Reproductive Health, Pregnancy, and Contraception	N/A	COR 3 No Benefit: Routine cesarean delivery has no benefit and may cause harm in pregnant patients with ACHD in the absence of an obstetric indication or high-risk cardiac condition.
New	3.10.2. Physical Activity, Exercise, and Sports Participation	N/A	COR 2a: In patients with ACHD, participation in competitive sports is reasonable following a comprehensive evaluation by an ACHD specialist that incorporates functional status and individualized assessment of risks and benefits.
Revised	The 2018 guideline had a section dedicated to severe pulmonary hypertension and Eisenmenger syndrome. In the 2025 guideline, these pulmonary hypertension recommendations are within the different shunt lesion sections, and Eisenmenger syndrome is a stand-alone section.		
New	4.1.1. Atrial Septal Defect	N/A	COR 1: Adults with an unrepaired atrial septal defect (ASD) and pulmonary arterial hypertension (PAH) should undergo risk assessment and management in consultation with pulmonary hypertension specialists to improve outcomes.

*Continued on the next page*

**TABLE 1** Continued

New or Revised	Section Title	2018 Recommendation	2025 Recommendation
Revised	4.1.1. Atrial Septal Defect	COR 2b: Percutaneous or surgical closure may be considered for adults with ASD when net left-to-right shunt (Qp:Qs) is $\geq 1.5:1$ , pulmonary artery (PA) systolic pressure is $\geq 50\%$ of systemic arterial systolic pressure, and/or pulmonary vascular resistance (PVR) is greater than one-third of the systemic resistance.	COR 1: In adults with an isolated unrepaired secundum ASD, transcatheter closure is usually preferred to surgical repair to reduce length of stay and recovery time.
New	4.1.1. Atrial Septal Defect	N/A	COR 1: In adults with an unrepaired ASD and evidence of (or strong suspicion for) paradoxical embolism, ASD closure is recommended to prevent recurrent embolism.
New	4.1.1. Atrial Septal Defect	N/A	COR 2a: In adults with an unrepaired ASD, significant left-to-right shunt (Qp:Qs $\geq 1.5$ ), right ventricular (RV) dilation, PAH (PVR 5-8 Wood units), and without significant left ventricular (LV) disease, closure can be beneficial if PVR $< 5$ Wood units can be achieved with targeted PAH therapy, to improve medium-term functional status.
New	4.1.2. Ventricular Septal Defect	N/A	COR 1: Patients with an unrepaired ventricular septal defect (VSD) should be assessed for the presence of PAH to guide decisions about medical therapy and repair.
New	4.1.2. Ventricular Septal Defect	N/A	COR 1: In adults with a perimembranous VSD being considered for repair, evaluation to exclude right ventricular outflow tract (RVOT) obstruction or double-chambered right ventricle (DCRV) is recommended to improve management planning.
New	4.1.2. Ventricular Septal Defect	N/A	COR 1: Adults with a VSD (repaired or unrepaired) and PAH should be followed by specialists with expertise in ACHD and pulmonary hypertension to reduce morbidity and mortality.
New	4.1.2. Ventricular Septal Defect	N/A	COR 3 No Benefit: In adults with a VSD, Qp:Qs $< 1.5$ , and no other indications, closure should not be performed to avoid unnecessary perioperative risks.
Revised	4.1.3. Atrioventricular Septal Defect	COR 2a: Cardiac catheterization can be useful in adults with atrioventricular septal defect (AVSD) when pulmonary hypertension is suspected.	COR 1: Adults with an unrepaired AVSD or those with residual shunts after prior repair should be assessed for the presence of PAH to guide medical therapy and assess suitability for repair.
New	4.1.3. Atrioventricular Septal Defect	N/A	COR 1: Adults with an AVSD (repaired or unrepaired) and PAH should be managed by pulmonary hypertension specialists and by clinicians with pulmonary hypertension expertise to improve outcomes.
revised	4.1.3. Atrioventricular Septal Defect	COR 2a: Operation for discrete left ventricular outflow tract (LVOT) obstruction in adults with AVSD is reasonable with a maximum gradient of $\geq 50$ mm Hg, a lesser gradient if heart failure (HF) symptoms are present, or if concomitant moderate-to-severe mitral or atrial regurgitation are present.	COR 1: In adults with repaired AVSD and LVOT obstruction with symptoms attributable to the obstruction, or LV systolic dysfunction (LV ejection fraction $< 50\%$ ), surgical repair is recommended to improve functional status and preserve ventricular function.
Revised	4.1.3. Atrioventricular Septal Defect	COR 1: Surgery for primary repair of AVSD or closure of residual shunts in adults with repaired AVSD is recommended when there is a net left-to-right shunt (Qp:Qs $\geq 1.5:1$ ), PA systolic pressure $< 50\%$ systemic, and PVR less than one-third systemic.	COR 1: In adults with an unrepaired AVSD or those with residual shunts after previous repair, significant left-to-right shunt (Qp:Qs $\geq 1.5$ ), and/or significant or progressive atrial/ventricular dilatation with no PAH (PVR $\leq 2$ Wood units), closure of the AVSD or residual shunt is recommended to improve functional class and clinical outcomes.
New	4.1.4. Anomalous Pulmonary Venous Connections	N/A	COR 1: For adults with anomalous pulmonary venous connections (APVCs) who do not have an indication for repair, routine cardiac imaging is recommended for serial evaluation of RV size and function and for assessment of pulmonary hypertension.
New	4.1.4. Anomalous Pulmonary Venous Connections	N/A	COR 1: For adults with repaired APVCs and dyspnea on exertion and/or reduced functional capacity, cardiac magnetic resonance (CMR) or computed tomography (CT) angiography is recommended to evaluate for venous obstruction or residual shunt.
New	4.1.4. Anomalous Pulmonary Venous Connections	N/A	COR 3 No Benefit: For adults with APVCs who have a normal to mildly enlarged right ventricle and whose Qp:Qs is $< 1.5$ , surgical repair is not indicated, given the absence of data to support benefit.
New	Section 4.1.5. Patent Ductus Arteriosus contains all new recommendations.		

Continued on the next page

**TABLE 1** Continued

New or Revised	Section Title	2018 Recommendation	2025 Recommendation
Revised	4.2.1. Cor Triatriatum Sinister	COR 1: Adults presenting with cor triatriatum sinister should be evaluated for other congenital abnormalities, particularly ASD, VSD, and APVC.	COR 2a: In adults with unrepaired cor triatriatum sinister, transesophageal echocardiography and/or cross-sectional imaging can be useful to identify the size and location of the membrane orifice and to assess for the presence of associated congenital cardiac defects.
Revised	4.2.1. Cor Triatriatum Sinister	COR 1: Surgical repair is indicated for adults with cor triatriatum sinister for symptoms attributable to the obstruction or substantial gradient across the membrane.	COR 2a: In asymptomatic adults with unrepaired cor triatriatum sinister and severe membrane obstruction, surgical resection can be useful to prevent the sequelae of left atrial hypertension.
New	4.2.1. Cor Triatriatum Sinister	N/A	COR 1: In adults with unrepaired cor triatriatum sinister and atrial fibrillation or atrial flutter, prior stroke, or left atrial thrombus, chronic anticoagulation is recommended to prevent embolic stroke, whether or not conventional thromboembolic risk factors are present.
New	4.2.1. Cor Triatriatum Sinister	N/A	COR 2a: In adults with unrepaired cor triatriatum sinister and atrial fibrillation or atrial flutter, a rhythm control strategy can be beneficial to avoid clinical decompensation.
New	4.2.2. Congenital Mitral Stenosis, Including Shone Complex	N/A	COR 1: Adults with multiple left-sided obstructive lesions (Shone complex) and suspected pulmonary hypertension should undergo invasive hemodynamic assessment to identify and classify pulmonary hypertension.
New	4.2.4. Congenital Diseases of the Aortic Valve	N/A	COR 1: Adults with a bicuspid aortic valve who have an aortic diameter >4 cm at the level of the sinuses or the ascending aorta, or who have risk factors for aortic dissection, should undergo lifelong surveillance for progression of thoracic aortic disease to improve early detection of aortic growth.
New	4.2.4. Congenital Diseases of the Aortic Valve	N/A	COR 1: In adults with a congenitally abnormal aortic valve who meet indications for valve replacement, surgical and transcatheter options should be reviewed by heart valve and ACHD expert teams in a shared decision-making process to determine a management plan.
New	4.2.6. Coarctation of the Aorta	N/A	COR 2a: In adults with coarctation of the aorta who present with exertional symptoms, evaluation for coronary artery disease is reasonable to guide management.
Revised	4.3.1. Ebstein Anomaly	COR 2a: Electrophysiological study with or without catheter ablation can be useful in the diagnostic evaluation of adults with Ebstein anomaly and ventricular preexcitation but without supraventricular tachycardia.	COR 1: In adults with Ebstein anomaly, an electrophysiological study is recommended for patients with symptomatic arrhythmia or asymptomatic ventricular preexcitation to assess for substrates for ablation, including multiple or high-risk accessory pathways.
New	4.3.2. Valvular Pulmonary Stenosis	N/A	COR 1: In asymptomatic adults with moderate or severe valvular pulmonary stenosis and at least moderate tricuspid regurgitation or any RV dysfunction, pulmonary valve intervention is recommended to reduce pressure overload and improve valvular function.
New	4.3.2.1. Isolated Pulmonary Regurgitation After Repair of Pulmonary Stenosis	N/A	COR 1: In adults with moderate or greater pulmonary regurgitation resulting from treated isolated valvular pulmonary stenosis, CMR imaging is recommended to establish anatomy, quantify the degree of regurgitation, and measure RV volumes and systolic function.
New	4.3.3. Management of Double-Chambered Right Ventricle	N/A	COR 2a: In adults with RV dysfunction or symptoms attributed to DCRV, cardiac catheterization is reasonable to characterize anatomy and severity.
New	4.3.3. Management of Double-Chambered Right Ventricle	N/A	COR 2a: In adults with DCRV and moderate or greater RVOT obstruction, diagnostic assessment with CMR (or, if contraindicated, cardiac CT) can be beneficial to characterize the anatomy.
Revised	4.3.4. Isolated Branch Pulmonary Artery Stenosis	COR 2a: In adults with peripheral or branch PA stenosis, PA dilation and stenting can be useful.	COR 1: In adults with symptoms related to peripheral or branch PA stenosis, pulmonary branch balloon angioplasty and/or stent implantation is recommended to improve hemodynamics and symptoms.
New	4.3.5 Tetralogy of Fallot	N/A	COR 1: In adults with repaired tetralogy of Fallot (TOF), echocardiography is recommended for assessment of pulmonary and tricuspid valve dysfunction, right atrial size, ventricular size and function, residual VSDs, and estimation of RV systolic pressure to characterize residual hemodynamic sequelae.

Continued on the next page

**TABLE 1** Continued

New or Revised	Section Title	2018 Recommendation	2025 Recommendation
New	4.3.5 Tetralogy of Fallot	N/A	COR 1: In adults with repaired TOF and native RVOT anatomy being considered for transcatheter pulmonary valve replacement, cardiac CT is recommended to determine anatomic suitability.
New	4.3.5. Tetralogy of Fallot	N/A	COR 2a: In adults with repaired TOF and appropriate implantable cardioverter-defibrillator (ICD) therapies for monomorphic ventricular tachycardia, adjunctive catheter ablation is reasonable to reduce ventricular tachyarrhythmia burden.
New	4.3.5. Tetralogy of Fallot	N/A	COR 2a: In adults with repaired TOF with moderate or greater pulmonary valve dysfunction and progressive ventricular systolic dysfunction, pulmonary valve replacement (surgical or transcatheter) is reasonable to preserve ventricular function.
New	4.3.7. Management of Right Ventricle-to-Pulmonary Artery Conduits	N/A	COR 2a: In adults with a right ventricle-to-pulmonary artery (RV-to-PA) conduit being considered for transcatheter intervention, preprocedural coronary CT is reasonable to assess conduit calcification, anatomic characteristics, and coronary artery proximity to guide procedural planning.
Revised	4.3.7. Management of Right Ventricle-to-Pulmonary Artery Conduits	COR 2a: RV-to-PA conduit intervention is reasonable for adults with an RV-to-PA conduit and moderate or greater PR or moderate or greater stenosis with reduced functional capacity or arrhythmia.	COR 1: For adults with an RV-to-PA conduit, severe stenosis and/or severe regurgitation, and symptoms or worsening functional capacity or a sustained arrhythmia, conduit intervention should be performed to improve cardiovascular status.
New	4.4.1.1. Patients With dextro-Transposition of the Great Arteries and Atrial Switch	N/A	COR 1: Adults with dextro-transposition of the great arteries (d-TGA) and atrial switch who present with progressive exercise intolerance or HF should undergo cardiopulmonary exercise testing to assess for potential intervention targets, including arrhythmia and desaturation.
Revised	4.4.1.1. Patients With dextro-Transposition of the Great Arteries and Atrial Switch	COR 2a: Assessment for a communication through the interatrial baffle or venous stenosis is reasonable for adults with d-TGA with atrial switch, particularly if transvenous pacemaker/ICD implantation is considered or leads are already present.	COR 1: Adults with d-TGA and atrial switch with progressive exercise intolerance, HF, pulmonary hypertension, worsening atrial or ventricular tachyarrhythmia, pathway obstruction, or baffle leak should undergo invasive hemodynamic assessment to identify targets for medical, percutaneous, or surgical intervention.
New	4.4.1.1. Patients With dextro-Transposition of the Great Arteries and Atrial Switch	N/A	COR 1: Adults with d-TGA and atrial switch who require permanent pacemaker or an ICD should undergo preprocedural imaging, in addition to intraprocedural contrast venography, to detect baffle stenosis and residual baffle leaks.
New	4.4.1.1. Patients With dextro-Transposition of the Great Arteries and Atrial Switch	N/A	COR 2a: For adults with d-TGA and atrial switch, biomarkers and validated disease-specific risk scores can be useful to identify patients at high risk for adverse cardiac events, prompting closer follow-up and referral to specialized HF transplant centers.
Revised	4.4.1.1. Patients With dextro-Transposition of the Great Arteries and Atrial Switch	COR 1: Ambulatory monitoring for bradycardia or sinus node dysfunction is recommended for adults with d-TGA with atrial switch, especially if treated with beta blockers or other rate-slowing agents.	COR 2a: In adults with d-TGA and atrial switch with new or progressive symptoms of HF, it is reasonable to obtain a resting electrocardiogram and outpatient ambulatory rhythm monitoring, to ensure timely diagnosis and treatment of tachyarrhythmia or bradyarrhythmia.
New	4.4.1.1. Patients With dextro-Transposition of the Great Arteries and Atrial Switch	N/A	COR 1: Adults with d-TGA and atrial switch who have symptoms attributable to a baffle leak should undergo closure of the leak to improve symptoms and quality of life.
New	4.4.1.1. Patients With dextro-Transposition of the Great Arteries and Atrial Switch	N/A	COR 1: In adults with d-TGA and atrial switch who have symptoms attributable to systemic or pulmonary venous pathway stenosis or liver congestion, intervention to relieve the stenosis is indicated to improve symptoms and prognosis.
New	4.4.1.1. Patients With dextro-Transposition of the Great Arteries and Atrial Switch	N/A	COR 1: Adults with d-TGA and atrial switch who have worsening symptoms of exercise intolerance, HF, or arrhythmia refractory to treatment should be referred to a HF program for assessment for mechanical support and transplantation in consultation with an ACHD cardiologist, to improve quality of life and prolong survival.
Revised	4.4.1.1. Patients With dextro-Transposition of the Great Arteries and Atrial Switch	COR 1: GDMT with appropriate attention to the need for anticoagulation is recommended to promptly restore sinus rhythm for adults with d-TGA with atrial switch repair presenting with atrial arrhythmia.	COR 2a: In adults with d-TGA and atrial switch who have sustained intra-atrial reentrant arrhythmias or atrial fibrillation, oral anticoagulation can be useful to prevent embolic events.

Continued on the next page

**TABLE 1** Continued

New or Revised	Section Title	2018 Recommendation	2025 Recommendation
New	4.4.1.1. Patients With dextro-Transposition of the Great Arteries and Atrial Switch	N/A	COR 2a: Adults with d-TGA and atrial switch who require transvenous lead placement can benefit from catheter-based interventions to address residual baffle leaks or obstruction before lead placement, to reduce the risk for systemic thromboembolism and/or future baffle occlusion.
Revised	4.4.1.2. Arterial Switch Operation	COR 2a: Physiological tests of myocardial perfusion for adults with d-TGA after arterial switch can be beneficial for assessing symptoms suggestive of myocardial ischemia.	COR 1: In adults with an arterial switch operation and symptoms concerning for myocardial ischemia, coronary evaluation with coronary angiography, cross-sectional imaging, and/or functional coronary assessment for an anatomic etiology should be performed.
New	4.4.1.2. Arterial Switch Operation	N/A	COR 1: In adults with an arterial switch operation and evidence of myocardial ischemia, coronary revascularization should be performed to reduce symptoms and improve outcomes.
New	4.4.1.2. Arterial Switch Operation	N/A	COR 2a: In asymptomatic adults with an arterial switch operation who have moderate or greater supraaortic or branch PA stenosis—in addition to RV hypertension, RV dysfunction, progressive tricuspid regurgitation, and/or objective decline in exercise capacity—intervention can be useful to relieve obstruction.
New	Section 4.4.1.3. Patients With d-TGA and Rastelli Repair contains all new recommendations.		
New	4.4.2. Management of CCTGA	N/A	COR 1: In adults with congenitally corrected transposition of the great arteries (CCTGA), periodic transthoracic echocardiography is recommended to assess chamber function, systemic tricuspid valve function, and associated anatomic lesions such as septal defects and LVOT stenosis.
New	4.4.2. Management of CCTGA	N/A	COR 2a: In adults with CCTGA without symptoms, periodic ambulatory rhythm monitoring is reasonable to screen for high-grade atrioventricular block.
New	4.4.2. Management of CCTGA	N/A	COR 2a: In symptomatic adults with CCTGA and high-grade atrioventricular block, physiological pacing (CRT or conduction system pacing) is reasonable to relieve symptoms.
New	4.4.5. Fontan Palliation of Single-Ventricle Physiology	N/A	COR 1: In adults with Fontan circulation and evidence of progressive Fontan circulatory failure, formal evaluation by a HF/transplant cardiologist with experience in heart transplantation in the adult Fontan population is recommended.
New	4.4.5. Fontan Palliation of Single-Ventricle Physiology	N/A	COR 1: In adults with Fontan circulation, imaging and laboratory evaluation of the liver should be performed at least annually to screen for hepatocellular carcinoma and for evidence of progressive Fontan-associated liver disease.
New	4.4.5. Fontan Palliation of Single-Ventricle Physiology	N/A	COR 1: In adults with Fontan circulation and new or progressive symptoms, hypoxemia, declining functional status, or evidence of progressive or new-onset noncardiac organ dysfunction, hemodynamic evaluation with cardiac catheterization is recommended to guide therapy.
New	4.4.5. Fontan Palliation of Single-Ventricle Physiology	N/A	COR 1: In adults with Fontan circulation and newly progressive or severe hypoxemia or hypotension, evaluation with advanced cardiac imaging (CMR, CT, transesophageal echocardiography) is recommended to rule out thrombus or emboli in the Fontan or pulmonary vasculature.
New	4.4.5. Fontan Palliation of Single-Ventricle Physiology	N/A	COR 1: In adults with Fontan circulation undergoing CT angiography to rule out thrombus or emboli in the Fontan or pulmonary vasculature, imaging should be performed using protocols to avoid false-negative or false-positive results.
New	4.4.5. Fontan Palliation of Single-Ventricle Physiology	N/A	COR 2a: In adults with Fontan circulation, consultation by a hepatologist, in collaboration with an ACHD cardiologist, is reasonable to facilitate interpretation of hepatic testing, diagnose and treat complications related to portal hypertension, and participate in timing and management decisions specific to organ transplantation.
New	4.4.5. Fontan Palliation of Single-Ventricle Physiology	N/A	COR 2a: In adults with Fontan circulation, liver biopsy can be helpful to delineate the degree of hepatic fibrosis or cirrhosis before consideration of transplantation.
New	4.4.5. Fontan Palliation of Single-Ventricle Physiology	N/A	COR 1: In adults with Fontan circulation and sinus node dysfunction requiring pacemaker placement, atrial-based pacing with programming to minimize ventricular pacing is recommended to improve patient symptoms and to avoid pacing-induced cardiomyopathy.

Continued on the next page

**TABLE 1** Continued

New or Revised	Section Title	2018 Recommendation	2025 Recommendation
New	4.4.5. Fontan Palliation of Single-Ventricle Physiology	N/A	COR 1: In adults with Fontan circulation with new-onset atrial flutter or atrial fibrillation, timely cardioversion (pharmacological or electrical) is recommended to prevent clinical decompensation.
New	4.4.5. Fontan Palliation of Single-Ventricle Physiology	N/A	COR 1: Adults with Fontan circulation referred for cardiac transplantation should undergo pretransplantation review by a committee with broad multidisciplinary representation to improve patient selection and posttransplant outcomes.
New	4.4.5. Fontan Palliation of Single-Ventricle Physiology	N/A	COR 2a: In adults with Fontan circulation and atrioventricular block whose burden of ventricular pacing is likely to be high (ie, >40%), apical site pacing is preferred over nonapical sites to improve transplant-free survival.
New	4.4.5. Fontan Palliation of Single-Ventricle Physiology	N/A	COR 2a: In adults with Fontan circulation, formal exercise programs and/or cardiac rehabilitation (appropriate to the patient's ability) can be beneficial in improving functional capacity.
New	4.4.5. Fontan Palliation of Single-Ventricle Physiology	N/A	COR 2a: In adults with Fontan circulation and hemodynamically significant stenosis of the Fontan or PAs, catheter-based stenting of the stenosis to reduce Fontan pressure and improve flow is reasonable to improve hemodynamics.
New	4.4.5. Fontan Palliation of Single-Ventricle Physiology	N/A	COR 2a: In symptomatic adults with Fontan circulation, or those with evidence of systemic ventricular volume overload, closure of aortopulmonary collaterals to improve symptoms and reduce the likelihood of pathologic ventricular remodeling can be useful.
Revised	4.4.5. Fontan Palliation of Single-Ventricle Physiology	COR 2a: In adults after Fontan palliation, it is reasonable to perform biochemical and hematological testing on an annual basis, especially for liver and renal function.	COR 1: In adults with Fontan circulation, annual laboratory evaluation is recommended to assess for evidence of organ-system dysfunction or hematologic abnormality.
Revised	4.4.5. Fontan Palliation of Single-Ventricle Physiology	COR 2b: Antiplatelet therapy or anticoagulation with a vitamin K antagonist may be considered in adults after Fontan palliation without known or suspected thrombus, thromboembolic events, or prior arrhythmia.	COR 1: In adults with Fontan circulation and the absence of high-risk features (history of thromboembolism, sustained atrial flutter/fibrillation, or atriopulmonary Fontan) or bleeding contraindications, treatment with either aspirin or anticoagulation is recommended to reduce the probability of thromboembolic disease.
New	Section 4.4.5.1. HLHS/Norwood Repair is new.		
New	4.4.6. Eisenmenger Syndrome	N/A	COR 3 Harm: Adults with Eisenmenger syndrome should be advised against pregnancy to decrease the risk associated with excess maternal morbidity and mortality.
Revised	4.4.6. Eisenmenger Syndrome	COR 2a: Bosentan is a reasonable therapy to treat symptomatic adults with Eisenmenger syndrome with 1 of the following: shunts other than ASD/VSD (eg, PDA, aortopulmonary window), or complex congenital heart lesions or Down syndrome.	COR 1: In adults with Eisenmenger syndrome and an LV ejection fraction >40% who are symptomatic or have reduced exercise capacity, initial monotherapy with PAH-directed therapy is recommended to improve symptoms, hemodynamics and overall survival.
Revised	4.4.6. Eisenmenger Syndrome	COR 2a: It is reasonable to use phosphodiesterase type 5 (PDE-5) inhibitors (eg, sildenafil, tadalafil) to treat symptomatic adults with Eisenmenger syndrome with ASD, VSD, or great artery shunt.	COR 1: In adults with Eisenmenger syndrome and an LV ejection fraction >40% who are symptomatic or have reduced exercise capacity, initial monotherapy with PAH-directed therapy is recommended to improve symptoms, hemodynamics, and overall survival.
Revised	4.4.6. Eisenmenger Syndrome	COR 2a: In symptomatic adults with Eisenmenger syndrome, bosentan and PDE-5 inhibitors are reasonable in combination if symptomatic improvement does not occur with either medication alone.	COR 1: In adults with Eisenmenger syndrome and an LV ejection fraction >40% who remain symptomatic or have worsening exercise capacity on a single PAH therapy, dual combination therapy with an endothelin receptor antagonist and a PDE-5 inhibitor is recommended to improve symptoms, hemodynamics, and overall survival.
New	4.4.6. Eisenmenger Syndrome	N/A	COR 1: In adults with Eisenmenger syndrome who present with atrial arrhythmias, prompt restoration and maintenance of sinus rhythm is recommended to avoid hemodynamic deterioration.
New	4.4.6. Eisenmenger Syndrome	N/A	COR 2a: In adults with Eisenmenger syndrome, a regular exercise program in combination with directed PAH therapy can be effective in improving exercise capacity.
New	4.4.6. Eisenmenger Syndrome	N/A	COR 3 No Benefit: Adults with Eisenmenger syndrome should not be routinely prescribed oral anticoagulation given the high bleeding risk and lack of long-term survival benefit.

Continued on the next page

**TABLE 1** Continued

New or Revised	Section Title	2018 Recommendation	2025 Recommendation
New	4.4.6. Eisenmenger Syndrome	N/A	COR 3 Harm: In adults with Eisenmenger syndrome, closure of any intracardiac or vascular shunt should not be performed given the increased perioperative risks and risks for short- and long-term morbidity and mortality.
New	4.4.6. Eisenmenger Syndrome	N/A	COR 3 Harm: In adults with Eisenmenger syndrome and intracardiac shunts who meet indications for permanent pacing or an ICD, endocardial leads may be potentially harmful given the increased risk for systemic thromboembolism.
New	4.5.1. Anomalous Aortic Origin of a Coronary Artery	COR 2a: Surgery is reasonable for anomalous aortic origin of the left coronary artery from the right sinus in the absence of symptoms or ischemia.  COR 2a: Surgery for anomalous aortic origin of a coronary artery is reasonable in the setting of ventricular arrhythmias.	COR 2a: In adults with asymptomatic anomalous origin of the left coronary artery, surgery is reasonable in the presence of high-risk anatomy.
New	Section 4.6. Vascular Rings and Pulmonary Artery Slings is new.		

COR indicates Class of Recommendation.

**TOP TAKE-HOME MESSAGES**

- Adults with congenital heart disease benefit from routine care at adult congenital heart disease (ACHD) centers and in collaboration with ACHD cardiologists. Multidisciplinary teams are useful for complex-care decision-making.
- Patients with anatomic or physiologically moderate or complex ACHD who undergo cardiac or noncardiac procedures are recommended to have an ACHD cardiologist involved in their care to offer expert guidance on procedures, anesthesia, and post-procedural management.
- The possibility of endocarditis is important to evaluate in acute or subacute malfunction of bioprosthetic pulmonary valves, and endocarditis has been added to the physiological classification system (subacute bacterial endocarditis in the past year is stage D).
- Most pregnant patients with ACHD can undergo vaginal delivery safely, with appropriate risk stratification and monitoring.
- Updated recommendations for tetralogy of Fallot include (a) referral for pulmonary valve replacement in patients with repaired tetralogy of Fallot, according to right ventricular end-systolic volume criteria (>80 mL/m<sup>2</sup>) and other metrics rather than end-diastolic volume; and (b) new approaches to arrhythmia management, including ablation of ventricular tachycardia.
- Strategies for patients with secundum atrial septal defect and pulmonary arterial hypertension now include recommendations for closure for many pa-

tients with a significant left-to-right shunt and pulmonary vascular resistance ≤2 Wood units or >2 to <5 Wood units.

- Rhythm control is typically preferred over rate control for atrial arrhythmias in complex patients, such as those with a systemic right ventricle or Fontan circulation.
- New recommendations on guideline-directed medical therapy for heart failure in patients with ACHD include people with a systemic right or left ventricle and discussions of pacing strategies for a systemic right ventricle and Fontan circulation.
- Patients with Eisenmenger syndrome can be treated with pulmonary vasodilators, using either phosphodiesterase-5 inhibitors or endothelin receptor antagonists as initial therapy.
- Fontan screening for liver disease includes recommendations for at least annual imaging and laboratory evaluation, including alpha-fetoprotein, and at least 1 consultation with a hepatologist.

**PREAMBLE**

Since 1980, the American College of Cardiology (ACC) and American Heart Association (AHA) have translated scientific evidence into clinical practice guidelines with recommendations to improve cardiovascular health. These guidelines, which are based on systematic methods to evaluate and classify evidence, provide a foundation for the delivery of quality cardiovascular care. The ACC and AHA sponsor the development and publication of clinical practice guidelines without commercial support,

and members volunteer their time to the writing and review efforts. Guidelines are official policy of the ACC and AHA. For some guidelines, the ACC and AHA collaborate with other organizations.

### Intended Use

Clinical practice guidelines provide recommendations applicable to patients with or at risk of developing cardiovascular disease. The focus is on medical practice in the United States, but these guidelines are relevant to patients throughout the world. Although guidelines may be used to inform regulatory or payer decisions, the intent is to improve quality of care and align with patients' interests. Guidelines are intended to define practices meeting the needs of patients in most, but not all, circumstances and should not replace clinical judgment.

### Clinical Implementation

Management, in accordance with guideline recommendations, is effective only when followed by both practitioners and patients. Adherence to recommendations can be enhanced by shared decision-making between clinicians and patients, with patient engagement in selecting interventions on the basis of individual values, preferences, and associated conditions and comorbidities.

### Methodology and Modernization

The ACC/AHA Joint Committee on Clinical Practice Guidelines (Joint Committee) continuously reviews, updates, and modifies guideline methodology on the basis of published standards from organizations, including the National Academy of Medicine (formerly the Institute of Medicine),<sup>1,2</sup> and on the basis of internal reevaluation. Similarly, the presentation and delivery of guidelines are reevaluated and modified in response to evolving technologies and other factors to optimally facilitate dissemination of information to health care professionals at the point of care.

Numerous modifications to the guidelines have been implemented to make them shorter and enhance "user friendliness." Guidelines are written and presented in a modular, "knowledge chunk" format in which each chunk includes a table of recommendations, a brief synopsis, recommendation-specific supportive text and, when appropriate, flow diagrams or additional tables. Hyperlinked references are provided for each modular knowledge chunk to facilitate quick access and review.

In recognition of the importance of cost-value considerations, in certain guidelines, when appropriate and feasible, an assessment of value for a drug, device, or intervention may be performed in accordance with the ACC/AHA methodology.<sup>3</sup>

To ensure that guideline recommendations remain current, new data will be reviewed on an ongoing basis by

the writing committee and staff. When applicable, recommendations will be updated with new evidence or new recommendations will be created when supported by published evidence-based data. Going forward, targeted sections/knowledge chunks will be revised dynamically after publication and timely peer review of potentially practice-changing science. The previous designations of "full revision" and "focused update" will be phased out. For additional information and policies on guideline development, readers may consult the ACC/AHA guideline methodology manual<sup>4</sup> and other methodology articles.<sup>5-7</sup>

### Selection of Writing Committee Members

The Joint Committee strives to ensure that the guideline writing committee contains requisite content expertise and is representative of the broader cardiovascular community by selection of experts across a spectrum of backgrounds, representing different geographic regions, sexes, races, ethnicities, intellectual perspectives/biases, and clinical practice settings. Organizations and professional societies with related interests and expertise are invited to participate as collaborators.

### Relationships With Industry and Other Entities

The ACC and AHA have rigorous policies and methods to ensure that documents are developed without bias or improper influence. The complete policy on relationships with industry and other entities (RWI) can be found [online](#). [Appendix 1](#) of the guideline lists writing committee members' comprehensive and relevant RWI.

### Evidence Review and Evidence Review Committees

In developing recommendations, the writing committee uses evidence-based methodologies that are based on all available data.<sup>5,6</sup> Literature searches focus on randomized controlled trials (RCTs) but also include registries, nonrandomized comparative and descriptive studies, case series, cohort studies, systematic reviews, and expert opinion. Only key references are cited.

An independent evidence review committee is commissioned when there are  $\geq 1$  questions deemed of utmost clinical importance that merit formal systematic review to determine which patients are most likely to benefit from a drug, device, or treatment strategy, and to what degree. Criteria for commissioning an evidence review committee and formal systematic review include absence of a current authoritative systematic review, feasibility of defining the benefit and risk in a time frame consistent with the writing of a guideline, relevance to a substantial number of patients, and likelihood that the findings can be translated into actionable recommendations. Evidence review committee members may include methodologists, epidemiologists, clinicians, and

biostatisticians. Recommendations developed by the writing committee on the basis of the systematic review are marked “<sup>SR</sup>.”

### Guideline-Directed Medical Therapy

The term guideline-directed medical therapy (GDMT) encompasses clinical evaluation, diagnostic testing, and both pharmacological and procedural treatments. For these and all recommended drug treatment regimens, the reader should confirm dosage with product insert material and evaluate for contraindications and interactions. Recommendations are limited to drugs, devices, and treatments approved for clinical use in the United States.

*Catherine M. Otto, MD, FACC, FAHA  
Chair, ACC/AHA Joint Committee on  
Clinical Practice Guidelines*

## 1. INTRODUCTION

### 1.1. Methodology and Evidence Review

The recommendations listed in this guideline are, whenever possible, evidence based. An initial extensive evidence review—which included literature derived from research involving human subjects, published in English, and indexed in MEDLINE (through PubMed), EMBASE, the Cochrane Library, the Agency for Healthcare Research and Quality, and other selected databases relevant to this guideline—was conducted from May 2024 to September 2024. Key search words included but were not limited to the following: adult congenital heart disease; aortic coarctation; aortic valve stenosis; cardiac catheterization; cardiac surgical procedures; congenital heart disease; cor triatriatum; coronary vessel anomalies; diagnostic imaging; discrete subaortic stenosis; ductus arteriosus, patent; Ebstein anomaly; follow-up studies; heart defects, congenital; heart septal defects, ventricular; mortality; pulmonary valve stenosis; reoperation; surgery; survival rate; tetralogy of Fallot; therapy; transposition of great vessels; treatment outcome; and ventricular outflow obstruction.

Additional relevant studies, which were published through July 2025 during the guideline writing process, were also considered by the writing committee and added to the evidence tables when appropriate. The final [Evidence Table](#) summarizes the evidence used by the writing committee to formulate recommendations. References selected and published in the present document are representative and not all-inclusive.

### 1.2. Composition of the Writing Committee

The writing committee consisted of adult congenital heart disease (ACHD) cardiologists from adult and pediatric training backgrounds, congenital cardiac surgeons, ACHD interventional cardiologists, heart failure

cardiologists, ACHD electrophysiologists, advanced practice nurses, and a patient advocate. The writing committee included representatives from the AHA, ACC, Heart Rhythm Society (HRS), International Society for Adult Congenital Heart Disease (ISACHD), and Society for Cardiovascular Angiography and Interventions (SCAI). [Appendix 1](#) of the present document lists writing committee members' comprehensive and relevant RWI.

The AHA and ACC also engaged a contract developmental editor, Steven DeMaio, to review the entire guideline for style, standards, voice, and clarity. We gratefully acknowledge Mr. DeMaio's contribution.

### 1.3. Guideline Review and Approval

The Joint Committee appointed a peer review committee to review the document. The peer review committee was comprised of individuals nominated by the ACC, AHA, and the collaborating organizations. Reviewers' RWI information was distributed to the writing committee and is published in this document ([Appendix 2](#)).

This document was approved for publication by the governing bodies of the AHA and the ACC and was endorsed by the HRS, ISACHD, and SCAI.

### 1.4. Scope of the Guideline

The scope of the “2025 ACC/AHA/HRS/ISACHD/SCAI Guideline for the Management of Adults With Congenital Heart Disease” is to serve as a full revision and replacement of the “2018 AHA/ACC Guideline for the Management of Adults With Congenital Heart Disease.” This revision incorporates new data to develop recommendations. Congenital heart disease encompasses a range of structural cardiac abnormalities present before birth attributable to abnormal fetal cardiac development but does not include inherited disorders that may have cardiac manifestations, such as Marfan syndrome or hypertrophic cardiomyopathy. Also not included are anatomic variants, such as patent foramen ovale. Valvular heart disease may be congenital, so management overlaps with the “2020 ACC/AHA Guideline for the Management of Patients With Valvular Heart Disease,” particularly for bicuspid aortic valve (BAV) disease. Where overlap exists, this document focuses on the diagnosis and treatment of congenital valve disease when it differs from acquired valve disease, whether because of anatomic differences, presence of concomitant lesions, or differences to consider given the relatively young age of patients with ACHD. Aortopathy associated with BAV is discussed in the “2022 ACC/AHA Guideline for the Diagnosis and Management of Aortic Disease.” Thresholds for intervention in patients with conotruncal abnormalities, however, should not be extrapolated from those guidelines. This guideline is not intended to apply to children (<18 years of age) with congenital heart disease or adults

**TABLE 2** Associated AHA/ACC Publications

Title	Organization	Publication Year (Reference)
<b>Guidelines</b>		
Valvular heart disease	ACC/AHA	2020 <sup>2</sup>
Chest pain	AHA/ACC/ASE/CHEST/SAEM/SCCT/SCMR	2021 <sup>3</sup>
Coronary artery revascularization	ACC/AHA/SCAI	2021 <sup>4</sup>
Heart failure	AHA/ACC/HFSA	2022 <sup>5</sup>
Aortic disease	ACC/AHA	2022 <sup>6</sup>
Chronic coronary disease	AHA/ACC/ACCP/ASPC/NLA/PCNA	2023 <sup>7</sup>
Atrial fibrillation	ACC/AHA/ACCP/HRS	2023 <sup>8</sup>
<b>Other Relevant Documents</b>		
Genetic basis for congenital heart disease: revisited	AHA	2018 <sup>9</sup>
Appropriate use criteria for multimodality imaging during the follow-up care of patients with congenital heart disease	ACC/AHA/ASE/HRS/ISACHD/SCAI/SCCT/SCMR/SOPE	2020 <sup>10</sup>
Advances in managing transition to adulthood for adolescents with congenital heart disease: a practical approach to transition program design	AHA	2022 <sup>11</sup>
Arrhythmias in repaired tetralogy of Fallot	AHA	2022 <sup>12</sup>
Psychological outcomes and interventions for individuals with congenital heart disease	AHA	2022 <sup>13</sup>
Dual-organ transplantation: indications, evaluation, and outcomes for heart-kidney and heart-liver transplantation	AHA	2023 <sup>14</sup>
Neurodevelopmental outcomes for individuals with congenital heart disease: updates in neuroprotection, risk-stratification, evaluation, and management	AHA	2024 <sup>15</sup>

ACC indicates American College of Cardiology; ACCP, American College of Clinical Pharmacy; AHA, American Heart Association; ASE, American Society of Echocardiography; ASPC, American Society for Preventive Cardiology; CHEST, American College of Chest Physicians; HFSA, Heart Failure Society of America; HRS, Heart Rhythm Society; ISACHD, International Society for Adult Congenital Heart Disease; NLA, National Lipid Association; PCNA, Preventive Cardiovascular Nurses Association; SAEM, Society for Academic Emergency Medicine; SCAI, Society for Cardiovascular Angiography and Interventions; SCCT, Society of Cardiovascular Computed Tomography; SCMR, Society for Cardiovascular Magnetic Resonance; and SOPE, Society of Pediatric Echocardiography.

with acquired valvular heart disease, heart failure, or other cardiovascular diseases.

Patients with ACHD are a heterogeneous population, both in underlying anatomy and physiology as well as surgical repair or palliation. Consequently, although the prevalence of ACHD is increasing, the population of patients with a given congenital abnormality or specific repair may be relatively small. Despite the difficulty in studying ACHD populations, there is a growing body of high-quality data in these patients to guide the care of this population. Whenever feasible, these data were used to develop recommendations. Recommendations are made based on the available data; however, when important clinical issues lacked data, first principles, extrapolation from data in other populations, and expert consensus are used to guide care. Patients with ACHD may have concomitant diseases to which other existing guidelines apply, such as coronary artery disease, heart failure, and arrhythmias. The data from acquired heart disease populations may apply to some patients with ACHD, and those circumstances are acknowledged in these recommendations and referenced accordingly. Patients with ACHD who are cared for in ACHD centers have better outcomes than those cared for in centers without ACHD expertise,<sup>1</sup> and

this need for specialized care is noted throughout the guideline. These recommendations are intended to provide guidance to a wide variety of providers caring for patients with ACHD, including general, pediatric, and ACHD cardiologists, as well as surgeons, primary care providers, and other health care professionals.

In developing this guideline, the writing committee reviewed previously published guidelines and related scientific statements. **Table 2** contains a list of these publications deemed pertinent to this writing effort. It is intended for use as a resource, obviating the need to repeat existing guideline recommendations. Some recommendations have been carried forward from previously published guidelines. If unchanged, those recommendations remain current. Any changes to the formatting or content of these recommendations are defined as:

- Modified: formatting changes (eg, minor modifications such as PICO[TS] [patient population, intervention, comparator, outcome, time, setting] structure)
- Adapted: substantive changes (eg, major adaptations, such as a change in Class of Recommendation (COR), Level of Evidence (LOE), drug or device classification).

**TABLE 3** Applying the American College of Cardiology/American Heart Association Class of Recommendation and Level of Evidence to Clinical Strategies, Interventions, Treatments, or Diagnostic Testing in Patient Care\* (Updated December 2024)

CLASS (STRENGTH) OF RECOMMENDATION	LEVEL (QUALITY) OF EVIDENCE‡
<p><b>Class 1 (STRONG) Benefit &gt;&gt;&gt; Risk</b></p> <p><b>Suggested phrases for writing recommendations:</b></p> <ul style="list-style-type: none"> <li>• Is recommended</li> <li>• Is indicated/useful/effective/beneficial</li> <li>• Should be performed/administered/other</li> <li>• Comparative-Effectiveness Phrases†:                             <ul style="list-style-type: none"> <li>- Treatment/strategy A is recommended/indicated in preference to treatment B</li> <li>- Treatment A should be chosen over treatment B</li> </ul> </li> </ul>	<p><b>Level A</b></p> <ul style="list-style-type: none"> <li>• High-quality evidence‡ from more than 1 RCT</li> <li>• Meta-analyses of high-quality RCTs</li> <li>• One or more RCTs corroborated by high-quality registry studies</li> </ul>
<p><b>Class 2a (MODERATE) Benefit &gt;&gt; Risk</b></p> <p><b>Suggested phrases for writing recommendations:</b></p> <ul style="list-style-type: none"> <li>• Is reasonable</li> <li>• Can be useful/effective/beneficial</li> <li>• Comparative-Effectiveness Phrases†:                             <ul style="list-style-type: none"> <li>- Treatment/strategy A is probably recommended/indicated in preference to treatment B</li> <li>- It is reasonable to choose treatment A over treatment B</li> </ul> </li> </ul>	<p><b>Level B-R (Randomized)</b></p> <ul style="list-style-type: none"> <li>• Moderate-quality evidence‡ from 1 or more RCTs</li> <li>• Meta-analyses of moderate-quality RCTs</li> </ul> <p><b>Level B-NR (Nonrandomized)</b></p> <ul style="list-style-type: none"> <li>• Moderate-quality evidence‡ from 1 or more well-designed, well-executed nonrandomized studies, observational studies, or registry studies</li> <li>• Meta-analyses of such studies</li> </ul>
<p><b>Class 2b (WEAK) Benefit ≥ Risk</b></p> <p><b>Suggested phrases for writing recommendations:</b></p> <ul style="list-style-type: none"> <li>• May/might be reasonable</li> <li>• May/might be considered</li> <li>• Usefulness/effectiveness is unknown/unclear/uncertain or not well-established</li> </ul>	<p><b>Level C-LD (Limited Data)</b></p> <ul style="list-style-type: none"> <li>• Randomized or nonrandomized observational or registry studies with limitations of design or execution</li> <li>• Meta-analyses of such studies</li> <li>• Physiological or mechanistic studies in human subjects</li> </ul> <p><b>Level C-EO (Expert Opinion)</b></p> <ul style="list-style-type: none"> <li>• Consensus of expert opinion based on clinical experience</li> </ul>
<p><b>Class 3: No Benefit (MODERATE) Benefit = Risk (Generally, LOE A or B use only)</b></p> <p><b>Suggested phrases for writing recommendations:</b></p> <ul style="list-style-type: none"> <li>• Is not recommended</li> <li>• Is not indicated/useful/effective/beneficial</li> <li>• Should not be performed/administered/other</li> </ul>	<p>COR and LOE are determined independently (any COR may be paired with any LOE).</p> <p>A recommendation with LOE C does not imply that the recommendation is weak. Many important clinical questions addressed in guidelines do not lend themselves to clinical trials. Although RCTs are unavailable, there may be a very clear clinical consensus that a particular test or therapy is useful or effective.</p>
<p><b>Class 3: HARM (STRONG) Risk &gt; Benefit</b></p> <p><b>Suggested phrases for writing recommendations:</b></p> <ul style="list-style-type: none"> <li>• Potentially harmful</li> <li>• Causes harm</li> <li>• Associated with excess morbidity/mortality</li> <li>• Should not be performed/administered/other</li> </ul>	<p>* The outcome or result of the intervention should be specified (an improved clinical outcome or increased diagnostic accuracy or incremental prognostic information).</p> <p>† For comparative-effectiveness recommendations (COR 1 and 2a; LOE A and B only), studies that support the use of comparator verbs should involve direct comparisons of the treatments or strategies being evaluated.</p> <p>‡ The method of assessing quality is evolving, including the application of standardized, widely-used, and preferably validated evidence grading tools; and for systematic reviews, the incorporation of an Evidence Review Committee.</p> <p>COR indicates Class of Recommendation; EO, expert opinion; LD, limited data; LOE, Level of Evidence; NR, nonrandomized; R, randomized; and RCT, randomized controlled trial.</p>

Changes are depicted in a footnote below the recommendation tables. Clinicians should be advised that this guideline revises and replaces the previously published “2018 AHA/ACC Guideline for the Management of Adults With Congenital Heart Disease.”

### 1.5. Class of Recommendations and Level of Evidence

The Class of Recommendation (COR) indicates the strength of recommendation, encompassing the estimated magnitude and certainty of benefit in proportion to risk. The Level of Evidence (LOE) rates the quality of scientific evidence supporting the intervention on the basis of the type, quantity, and consistency of data from clinical trials and other sources (Table 3).<sup>1</sup>

## 2. DEFINITIONS AND CLASSIFICATIONS

### 2.1. Definitions

#### 2.1.1. Anatomic Terms

The International Society for Nomenclature of Pediatric and Congenital Heart Disease (also known as the Nomenclature Working Group) defined, codified, mapped, and archived examples of nomenclatures and developed standards for terminology.<sup>1-5</sup> The International Paediatric and Congenital Cardiac Code nomenclature for anatomic lesions and repairs is used in this guideline (<http://ipccc.net>).<sup>6</sup>

#### 2.2. The ACHD Anatomic and Physiological Classification System

The ACHD anatomic and physiological (AP) classification system (Table 4) was introduced in the 2018 AHA/ACC ACHD guidelines to more uniformly characterize ACHD anatomy and physiology. It aims to improve classification of disease severity given the potential for discordance between anatomic complexity and physiological stage. In addition, the AP classification system underpins the guidelines’ follow-up and procedural monitoring recommendations and has been shown to correlate with patient outcomes.<sup>1-4</sup> Patients are assigned an anatomic complexity, ranging from simple to complex (I-III), and a physiological stage that reflects their clinical status (A-D). Patients who are clinically well without residual anatomic or physiological sequelae are classified as physiological stage A, whereas patients with advanced heart failure or high-risk pulmonary arterial hypertension (PAH), for example, are classified as physiological stage D. A patient might shift to a lower (improved) physiological stage after an intervention, such as a valve replacement, but to a higher (worse) physiological stage when new arrhythmias develop.

Although the AP components are often independent of each other, certain combinations are incompatible. For example, given that physiological stage A requires

“no anatomic sequelae,” patients with certain conditions—such as Fontan circulation, a systemic right ventricle, or truncus arteriosus—can never be in physiological stage A.

Patients are classified according to the “highest” relevant anatomic or physiological feature. For example, the ACHD AP classification for a patient with repaired coarctation of the aorta (COA) who is asymptomatic and normotensive, with normal aortic dimensions and normal exercise capacity, would be IIA. If moderate ventricular dysfunction was also present, the classification would be IIC. In patients with multiple lesions, the most complex anatomic diagnosis determines the anatomic complexity.

Multiple studies have confirmed that a higher AP classification is associated with greater short- and long-term mortality risk and that the physiologic stage adds prognostic value to the anatomic classification.<sup>1-4</sup> In addition, higher AP classification has been associated with worse surgical outcomes and with maternal and fetal complications of pregnancy.<sup>5-7</sup> Despite the broad applicability of the AP classification system, more narrowly tailored risk stratification tools may be of benefit in some scenarios.

Notably, in addition to its association with outcomes, the ACHD AP classification system aims to support decision-making about where, when, and with what intensity adults with congenital heart disease should obtain medical care. Throughout these 2025 guidelines, AP classifications offer guidance on resource utilization, including which patients should undergo noncardiac procedures at ACHD centers (Section 3.2, “Expertise for Noncardiac Surgery”), which patients require ACHD experts for invasive cardiac procedures and anesthesia (Section 3.4, “Expertise for Cardiac Surgery and Invasive Cardiac Procedures”), and how patients with different AP classifications should be counseled and monitored during pregnancy, labor, and delivery (Section 3.8, “Reproductive Health, Pregnancy, and Contraception”). Even patients with low predicted mortality risk but complex anatomy can benefit from management by clinicians who have experience and expertise with congenital heart disease anatomy and physiology, especially during periods of hemodynamic stress. Although imperfect in assessing short- and long-term mortality risk, largely due to the heterogeneity of the population for which it was designed, the AP classification system provides a framework for discussing relative risk to help assemble the appropriate team in the right place for each patient.

The classification system’s guidance on resource utilization also includes information on ACHD consultation and routine diagnostic studies. Tables accompanying each diagnosis provide general guidance on follow-up intervals according to a patient’s physiological stage.

**TABLE 4** ACHD AP Classification (CHD Anatomy + Physiological Stage = ACHD AP Classification)

CONGENITAL HEART DISEASE ANATOMY	
<b>I: Simple</b>	
	Ostium secundum ASD
	Patent ductus arteriosus
	Ventricular septal defect
	Pulmonic stenosis
<b>II: Moderate Complexity</b>	
	Anomalous aortic origin of a coronary artery from the opposite sinus
	Anomalous coronary artery arising from the pulmonary artery
	Anomalous pulmonary venous connection, partial or total
	Atrioventricular septal defect (partial or complete)
	Congenital aortic valve disease
	Congenital mitral valve disease
	Coarctation of the aorta
	Cor triatriatum sinister
	Dextro-TGA after arterial switch operation
	Ebstein anomaly
	Infundibular right ventricular outflow obstruction/double-chamber right ventricle
	Peripheral pulmonary artery stenosis
	Sinus venosus defect
	Subvalvular aortic stenosis (excluding hypertrophic cardiomyopathy, which these guidelines do not address)
	Supravalvar aortic stenosis
	Tetralogy of Fallot
	Vascular ring or sling
<b>III: Great Complexity (or Complex)</b>	
	Double-outlet ventricle
	Fontan physiology
	Interrupted aortic arch
	Pulmonary atresia (all forms, including tetralogy of Fallot with pulmonary atresia)
	Single-ventricle anatomy (including double-inlet left ventricle, tricuspid/mitral atresia, hypoplastic left heart, any other anatomic abnormality with a functionally single ventricle)
	Congenitally corrected TGA (CCTGA, levo-TGA)
	Dextro-TGA after atrial switch (Mustard/Senning) operation
	Dextro-TGA after Rastelli operation
	Truncus arteriosus
	Unrepaired or partially palliated cyanotic congenital heart defect
PHYSIOLOGICAL STAGE	
<b>Stage A</b>	
	No cardiac symptoms
	No hemodynamic or anatomic sequelae
	No sustained arrhythmias*
	Normal exercise capacity*
	Normal pulmonary pressure

Continued on the next column

**TABLE 4** Continued

PHYSIOLOGICAL STAGE	
<b>Stage B</b>	
	Arrhythmia* not requiring new treatment or a change in therapy in the past 12 months
	Mild native valve dysfunction* or prosthetic valve with normal function
	Mild ventricular dysfunction
	Mild ventricular enlargement
	Presence of a permanent pacemaker or ICD, without need for ICD therapy in the past 12 months
	Trivial or small shunt* (not hemodynamically significant)
<b>Stage C</b>	
	BNP or NT-proBNP level $\geq 2$ times the upper limit of normal
	Hemodynamically significant shunt*
	Mild or moderate chronic hypoxemia* (baseline resting oxygen saturation 86%-92%)
	Moderate or greater valvular dysfunction*
	Moderate or severe ventricular dysfunction (systemic, pulmonic, or both)
	Pulmonary arterial hypertension (low-risk)*
	Sustained or high-burden tachyarrhythmia in the past 12 months requiring treatment with antiarrhythmic drugs, ablation, cardioversion, or ICD therapy
<b>Stage D</b>	
	Hospitalization for heart failure in the past 12 months <sup>10,16-18</sup>
	Endocarditis in the prior 1 year <sup>19-21</sup>
	Eisenmenger syndrome
	NYHA functional class* III or IV symptoms
	Recurrent arrhythmias* that are hemodynamically significant and/or refractory to treatment
	Severe hypoxemia* (baseline oxygen saturation $\leq 85\%$ )
	Pulmonary arterial hypertension* (intermediate- or high-risk)

Modified with permission from Stout et al.<sup>22</sup> Copyright 2018 American Heart Association, Inc. and American College of Cardiology Foundation.

\*See Table 5.

ACHD indicates adult congenital heart disease; AP, anatomic and physiological; ASD, atrial septal defect; BNP, B-type natriuretic peptide; ICD, implantable cardioverter-defibrillator; NT-proBNP, N-terminal prohormone of B-type natriuretic peptide; NYHA, New York Heart Association; PDA, patent ductus arteriosus; TGA, transposition of the great arteries; and VSD, ventricular septal defect.

Suggested follow-up intervals are not class recommendations, and the recommended testing intervals should be tailored to the individual patient and local resources.

The 2025 guidelines refine the AP classification system to reduce ambiguity and the risk for misclassification.<sup>8</sup> In addition, components have been added or modified to improve the system's prognostic ability. Biomarkers, such as N-terminal prohormone of B-type natriuretic peptide (NT-proBNP), unplanned heart failure hospitalizations, and recent endocarditis, each identify patients with poorer prognosis and higher resource utilization and, therefore, have been incorporated into this updated classification system.<sup>8-15</sup>

**TABLE 5** Physiological Variables as Used in ACHD AP Classification

Variable	Description
Arrhythmia	<p>Arrhythmias are very common in patients with ACHD and may be both the cause and the consequence of deteriorating hemodynamics, valvular dysfunction, or ventricular dysfunction. Given that arrhythmias are associated with symptoms, outcomes, and prognosis,<sup>23-26</sup> they are categorized based on their presence and their response to treatment.</p> <ul style="list-style-type: none"> <li>■ No sustained arrhythmia: No documented clinically relevant atrial or ventricular tachyarrhythmias</li> <li>■ Arrhythmia not requiring new treatment or a change in therapy in the past 12 months: Bradyarrhythmia, atrial or ventricular tachyarrhythmia not requiring new antiarrhythmic therapy, cardioversion, ablation, or pacemaker/ICD placement</li> <li>■ Recurrent arrhythmias that are hemodynamically significant and/or refractory to treatment</li> </ul>
Concomitant valvular heart disease (VHD)	<p>Severity defined according to the 2020 VHD guideline.<sup>27</sup></p> <ul style="list-style-type: none"> <li>■ Mild VHD</li> <li>■ Moderate VHD</li> <li>■ Severe VHD</li> </ul>
Exercise capacity	<p>Patients with ACHD are often asymptomatic despite exercise limitations that manifest as diminished exercise capacity upon objective evaluation<sup>28-30</sup>; accordingly, assessing both subjective and objective exercise capacity is important (see NYHA classification system below). Exercise capacity is associated with prognosis.<sup>31-33</sup></p> <ul style="list-style-type: none"> <li>■ Abnormal objective cardiac limitation to exercise is defined as an exercise maximum ventilatory equivalent of oxygen below the range expected for the specific congenital heart disease anatomic diagnosis.<sup>34,35</sup></li> </ul>
Hypoxemia/hypoxia/cyanosis	<p>See Section 3.5 for a detailed definition of cyanosis.</p> <ul style="list-style-type: none"> <li>■ Hypoxemia is defined as baseline oxygen saturation measured by pulse oximetry at rest <math>\leq 92\%</math>.</li> <li>■ Severe hypoxemia is defined as oxygen saturation at rest <math>\leq 85\%</math>.</li> <li>■ Hypoxia refers to inadequate tissue oxygenation that may or may not be present in the setting of chronic hypoxemia.</li> <li>■ Cyanosis is blue or purple discoloration of the skin, lips, and nailbeds caused by levels <math>\geq 5</math> g/dL of desaturated hemoglobin; it is visible in patients with chronic hypoxemia and normal or high hemoglobin levels but may be absent in patients with anemia.</li> </ul>
NYHA functional classification system <sup>36</sup>	<p>Functional Capacity<sup>37</sup></p> <ol style="list-style-type: none"> <li>I. Patients with cardiac disease but resulting in no limitation of physical activity: Ordinary physical activity does not cause undue fatigue, palpitation, dyspnea, or anginal pain.</li> <li>II. Patients with cardiac disease resulting in slight limitation of physical activity: They are comfortable at rest. Ordinary physical activity results in fatigue, palpitations, dyspnea, or anginal pain.</li> <li>III. Patients with cardiac disease resulting in marked limitation of physical activity: They are comfortable at rest. Less than ordinary activity causes fatigue, palpitations, dyspnea, or anginal pain.</li> <li>IV. Patients with cardiac disease resulting in inability to carry on any physical activity without discomfort: Symptoms of heart failure or the anginal syndrome may be present even at rest. If any physical activity is undertaken, discomfort increases.</li> </ol>
Pulmonary arterial hypertension	<p>Pulmonary arterial hypertension is defined as:</p> <ul style="list-style-type: none"> <li>■ Mean pulmonary artery pressure by right heart catheterization <math>\geq 20</math> mm Hg and a pulmonary capillary wedge pressure <math>\leq 15</math> mm Hg; and pulmonary vascular resistance <math>\geq 2</math> Wood units.<sup>38</sup></li> </ul> <p>Pulmonary arterial hypertension risk categories are measured using the 3-strata risk score calculator.<sup>39</sup></p>
Shunt (hemodynamically significant shunt)	<p>An intracardiac shunt is considered hemodynamically significant if there is evidence of chamber enlargement distal to the shunt and/or evidence of sustained Qp:Qs <math>\geq 1.5</math>.</p> <p>An intracardiac shunt not meeting these criteria would be described as small or trivial.</p>

Modified with permission from Stout et al.<sup>22</sup> Copyright 2018 American Heart Association, Inc. and American College of Cardiology Foundation.

ACHD indicates adult congenital heart disease; AP, anatomic and physiological; ICD, implantable cardioverter-defibrillator; NYHA, New York Heart Association; and Qp:Qs, pulmonary-to-systemic blood flow ratio.

Some patients with ACHD may have substantial acquired comorbidities unrelated to congenital heart disease, such that their cardiac follow-up strategies are more appropriately based on guidelines for acquired heart disease. For example, an 80-year-old patient with a small atrial septal defect (ASD), heart failure with preserved

ejection fraction, chronic kidney disease, diabetes, and aortic stenosis ought to be followed according to relevant guidelines for those diseases, rather than according to the AP classification for the ASD. Nevertheless, awareness of the additional, ASD-related hemodynamic complexity is important.

### 2.3. Abbreviations

Abbreviation	Meaning/Phrase
AAOCA	anomalous aortic origin of a coronary artery
ACHD	adult congenital heart disease
AP	anatomic and physiological
APVC	anomalous pulmonary venous connection
ASD	atrial septal defect
AVSD	atrioventricular septal defect
BAV	bicuspid aortic valve
BNP	B-type natriuretic peptide
CCTGA	congenitally corrected transposition of the great arteries
CMR	cardiovascular magnetic resonance
COA	coarctation of the aorta
CPET	cardiopulmonary exercise testing
CRT	cardiac resynchronization therapy
CT	computed tomography
DCRV	double-chambered right ventricle
d-TGA	dextro-transposition of the great arteries
FALD	Fontan-associated liver disease
GDMT	guideline-directed medical therapy
HLHS	hypoplastic left heart syndrome
ICD	implantable cardioverter-defibrillator
LV	left ventricular
LVOT	left ventricular outflow tract
MCS	mechanical circulatory support
MR	magnetic resonance
NT-proBNP	N-terminal prohormone of B-type natriuretic peptide
PA	pulmonary artery
PAH	pulmonary arterial hypertension
PA-IVS	pulmonary atresia with intact ventricular septum
PDA	patent ductus arteriosus
PVR	pulmonary vascular resistance
Qp:Qs	pulmonary-to-systemic blood flow ratio
RV	right ventricular
RVEDV	right ventricular end diastolic volume
RVOT	right ventricular outflow tract
RV-to-PA	right ventricle-to-pulmonary artery
SCD	sudden cardiac death
SVASD	sinus venosus atrial septal defect
TOF	tetralogy of Fallot
VSD	ventricular septal defect

### 3. GENERAL PRINCIPLES

#### 3.1. Care Access and Delivery in the ACHD Population

**Recommendation for Care Access and Delivery in the ACHD Population**  
 Referenced studies that support recommendation are summarized in the [Evidence Table](#).

COR	LOE	RECOMMENDATION
1	B-NR	1. ACHD programs and clinicians who care for adults with congenital heart disease should follow policies and procedures that reduce barriers, reduce attrition, and improve access to lifelong ACHD care. <sup>1-3</sup>

#### Synopsis

As the number of adults with congenital heart disease continues to rise for the next several decades,<sup>4-7</sup> access and care delivery will remain challenging. In the United States, where numbers of qualified ACHD cardiologists and centers are insufficient, geography, socioeconomic stress, and insurance variability may limit patients' access to high-quality care.<sup>1,8-18</sup> In addition, a large proportion of patients with congenital heart disease are lost to care before they reach adulthood, only to return for care when they develop cardiovascular symptoms and complications.<sup>10</sup> The complex process of loss to care starts in early childhood, accelerates through adolescence, and has many contributing factors: educational, developmental, socioeconomic, and geographic. It is estimated that only a small fraction of the ACHD population receives care at an ACHD specialty center.<sup>19</sup>

Adults with congenital heart disease face barriers to obtaining seamless, high-quality, lifelong ACHD care. Those barriers include:

- Lack of education—for patients, clinicians, and programs—about the transition and transfer process from pediatric to adult care for congenital heart disease
- Inadequate resources and organizational structures for facilitating comprehensive transfer of care from pediatric to ACHD clinicians and programs
- Inadequate numbers of ACHD clinicians and programs
- Socioeconomic, geographic, and insurance impediments to obtaining ACHD care

#### Recommendation-Specific Supportive Text

1. Limiting barriers to, reducing attrition from, and improving access to congenital heart disease care for adults requires the development and implementation of policies, procedures, and practical solutions. [Table 6](#) identifies the stakeholders and solutions to be considered in achieving key goals at each age-related stage of care.

**TABLE 6** The Lifelong Trajectory of Improving Access to ACHD Care<sup>1,8-18,20,21</sup>

Key Issues at Each Life Stage	Potentially Involved Stakeholders	Possible Solutions
Early childhood (0 to 12 years) <ul style="list-style-type: none"> <li>■ Patient/family education</li> <li>■ Loss to care</li> </ul>	<ul style="list-style-type: none"> <li>■ Children's hospitals</li> <li>■ Pediatric cardiology/heart centers</li> <li>■ Social workers</li> <li>■ Patients and families</li> <li>■ Payors</li> <li>■ Congenital heart disease advocacy organizations</li> </ul>	<ul style="list-style-type: none"> <li>■ Empower patients to stay in congenital heart disease care, by offering well-structured patient and family education.</li> <li>■ Identify patient barriers for loss to care<sup>22</sup>; and add resources.</li> <li>■ Use electronic health records and databases to track patients who are lost to care—and to help them navigate back to care.</li> </ul>
Adolescence to young adulthood (13 to 18 years) <ul style="list-style-type: none"> <li>■ Transition education</li> <li>■ Loss to care</li> </ul>	<ul style="list-style-type: none"> <li>■ Children's hospitals</li> <li>■ Pediatric cardiology/heart centers</li> <li>■ Social workers</li> <li>■ Patients and families</li> <li>■ Payors</li> <li>■ Congenital heart disease advocacy organizations</li> </ul>	<ul style="list-style-type: none"> <li>■ Procure and deploy resources to identify patients who are eligible for pediatric-to-adult transition education.</li> <li>■ Develop and implement transition education.</li> <li>■ Use electronic health records and databases to track patients who are lost to care—and to help them navigate back to care.</li> <li>■ Identify barriers to care to navigate back to care.</li> </ul>
Young adulthood (18 to 26 years) <ul style="list-style-type: none"> <li>■ Loss to care</li> <li>■ Transfer to ACHD care</li> </ul>	<ul style="list-style-type: none"> <li>■ Children's hospitals</li> <li>■ Pediatric cardiology/heart centers</li> <li>■ Adult care hospitals</li> <li>■ ACHD providers and programs</li> <li>■ Social workers</li> <li>■ Patients and families</li> <li>■ Payors</li> <li>■ ACHD advocacy organizations</li> </ul>	<ul style="list-style-type: none"> <li>■ Develop and implement processes, policies, and resources for successful transfer from pediatric to adult care.</li> <li>■ Identify barriers to care.</li> <li>■ Use electronic health records and databases to track patients who are lost to care—and to help them navigate back to care.</li> </ul>
Adulthood (18 to 80+ years) <ul style="list-style-type: none"> <li>■ Loss during transfer to ACHD care</li> <li>■ Loss to care during adulthood</li> <li>■ Insufficient number of ACHD cardiologists and programs</li> </ul>	<ul style="list-style-type: none"> <li>■ ACHD programs</li> <li>■ Adult care hospitals</li> <li>■ Social work professionals</li> <li>■ Patients</li> <li>■ Governmental agencies</li> <li>■ Medical education and medical board organizations</li> <li>■ ACHD advocacy organizations</li> </ul>	<ul style="list-style-type: none"> <li>■ Use electronic health records and databases to track patients who are lost to care and help navigate back to CHD care.</li> <li>■ Engage resources to track patients and identify barriers to care.</li> <li>■ Consider innovative care options such as telehealth.</li> <li>■ Partner with advance practice providers and general cardiologists, to provide local care.</li> <li>■ Increase the number and geographic availability of ACHD cardiologists.</li> </ul>

ACHD indicates adult congenital heart disease; and CHD, congenital heart disease.

**3.1.1. Transition Education and Transfer of Care**

**Recommendations for Transition Education and Transfer of Care**  
Referenced studies that support recommendations are summarized in the [Evidence Table](#).

COR	LOE	RECOMMENDATIONS
1	A B-NR	1. All patients with congenital heart disease should receive structured, patient-centered transition education that is age-, sex-, gender-, and developmentally appropriate to improve knowledge (LOE A) <sup>1,2</sup> and reduce loss to care (LOE B-NR). <sup>3-5</sup>
1	B-NR	2. Congenital heart disease programs and clinicians should have transfer-of-care policies and procedures to ensure effective handoffs of patients from a pediatric to an ACHD cardiologist. <sup>6-9</sup>

**Synopsis**

Transition education for congenital heart disease has several key challenges that include:

- Lack of universal identification, by current electronic medical record systems, to identify all patients with congenital heart disease who qualify for transition education.
- Lack of standardized, developmentally and educationally appropriate educational materials that meet the needs of the patient population and that account for patients' age, sex, gender, and learning ability.
- Inadequate resources and qualified personnel to administer transition education.
- Lack of resources and methodology for measuring the success of transition education.

Transfer of care from pediatric to ACHD providers is critical to the lifelong continuum of congenital heart disease care. Unsuccessful transfer to ACHD care may lead to gaps in care delivery and unexpected morbidity

and premature mortality.<sup>10</sup> Transfer-of-care challenges include:

- Lack of universal identification of eligible patients through electronic medical records
- Lack of resources to support staffing for nurse navigators and social workers who follow patients through the transfer process and ensure completion of care transfers to ACHD providers
- Barriers to care, including insurance, distance to clinic, and disruptions to work and career

**Recommendation-Specific Supportive Text**

1. Patients with congenital heart disease must navigate several critical stages that may affect quality of life and survival: diagnosis, palliative interventions in early childhood, transfer to ACHD providers/programs, and lifelong ACHD care, which may include reinterventions. Throughout those stages, patients should receive continuous education<sup>3-5,10-19</sup> regarding:

- Their specific congenital heart disease diagnosis: name, anatomy, physiology, and surgical procedures
- Expected short- and long-term medical issues, including the need for diagnostic evaluation and possible reintervention
- Reproductive health education
- Development of independent skills in making appointments, filling prescriptions, contacting providers with symptoms or concerns, and understanding the need to maintain insurance
- Need for lifelong, uninterrupted, specialized congenital heart disease care by ACHD cardiologists

2. Transition education should lead to seamless transfers from pediatric to ACHD providers and their respective teams. Loss to care affects patient outcomes. It disproportionately affects patients with socioeconomic stress, those who must travel significant distances to ACHD centers, and non-White patients.<sup>7-10,13,15,16,20</sup> To prevent loss to care during this critical period, pediatric and ACHD providers should employ policies and procedures for transfer of care that include:

- Determination of readiness for transfer of care
- Development of seamless policies and processes for referral to ACHD care

- Implementation of policies and processes for receiving and tracking transfer patients, which may include the use of nurse navigators and social workers to develop lists of patients and follow them after transfer of care has been initiated—and to identify and address barriers to care. Barriers may include geographic distance, consistency and insurance coverage, and socioeconomic challenges.

**3.1.2. The ACHD Program and Cardiologists**

**Recommendations for the ACHD Program and Cardiologists**  
 Referenced studies that support recommendations are summarized in the [Evidence Table](#).

COR	LOE	RECOMMENDATIONS
1	B-NR	1. Patients in ACHD AP classes IB-D, IIA-D, and IIIA-D should be evaluated and managed by or in collaboration with an ACHD cardiologist and, when indicated and accessible, an ACHD program to improve outcomes. <sup>1-3</sup>
1	B-NR	2. Patients in ACHD AP class IA should have at least 1 evaluation by an ACHD cardiologist to develop a plan of care. <sup>1-3</sup>

**Synopsis**

Patients with ACHD class IB or higher benefit from being evaluated and managed by or in collaboration with ACHD cardiologists and, when feasible, within an ACHD program.

- Patients with ACHD have complex anatomy, physiology, and past cardiac interventions and surgical repairs.
- Long-term complications may be unique to specific congenital heart disease lesions and require the expert knowledge and experience of ACHD cardiologists and specialists in ACHD programs.
- Even patients with milder forms of congenital heart disease benefit from an initial evaluation to develop a collaborative plan for diagnostic testing and follow-up.

**TABLE 7** ACHD Program Components

ACHD board-eligible/-certified cardiologists
Congenital cardiac surgeons
Advanced practice providers
Registered nurses
Advanced imagers: echocardiography/CT/CMR*
Cardiac intensivist*
Advanced heart failure and transplant cardiologist*
Cardiac catheterization interventionalist*
Electrophysiologist*
Cardiac anesthesiologist*
Multidisciplinary specialists
Maternal fetal medicine
Hepatology
Pulmonary hypertension
Cardiovascular genetics
Palliative medicine
Social work
Psychology

Modified with permission from Stout et al.<sup>12</sup> Copyright 2018 American Heart Association, Inc. and American College of Cardiology Foundation.

\*Personnel and service lines supervised, performed, and interpreted by clinicians with expertise and/or training in congenital heart disease.

ACHD indicates adult congenital heart disease; CMR, cardiovascular magnetic resonance; and CT, computed tomography.

### Recommendation-Specific Supportive Text

1. The American Board of Internal Medicine and the American Board of Pediatrics have created formal Accreditation Council for Graduate Medical Education training programs and subsequent board certification for ACHD cardiologists. In adulthood, outcomes for patients with ACHD are better when they are cared for in an organized, high-quality, fully integrated, collaborative, multidisciplinary ACHD program.<sup>1-3</sup> The definition of an ACHD program has been refined over the past 25 years.<sup>2,4-8</sup>

**Table 7** lists ACHD program personnel and services. An ACHD program should include multiple subspecialists with experience and expertise in complex ACHD anatomy and physiology.<sup>1-3,9-11</sup>

Patients with ACHD may be followed by individual ACHD cardiologists. However, more complex diagnoses should prompt collaboration with, or referral to, multidisciplinary specialized ACHD care. ACHD

program evaluation and management must be balanced against several accessibility constraints and barriers: geographic distance and travel limitations, insurance barriers, cost, and socioeconomic stress. Indications for program referral may include:

- Clinical evaluation to assess worsening AP class
- Advanced imaging (cardiac computed tomography [CT]/cardiovascular magnetic resonance [CMR]) is indicated and beyond local expertise
- Worsening heart failure and need for expert evaluation
- Heart or multiorgan transplant evaluation and/or listing
- Diagnostic and interventional heart catheterization evaluation and/or therapies
- Electrophysiology for arrhythmia, evaluation for device implantation, and/or electrophysiology study
- ACHD cardiothoracic surgery evaluation and/or surgery
- Risk assessment or management of pregnancy
- Noncardiac surgery in high-risk populations (AP classes IC-D, IIA-D, IIIA-D) and need for ACHD cardiac anesthesia and ICU support

2. After initial ACHD consultation and confirmation of the AP class, some patients with mild disease (class IA) may be followed by general cardiologists. However, they should be aware of potential complications of even the mildest forms of congenital heart disease.

Patients may enter an ACHD program from multiple pathways. The largest potential volume of patients—and the most critical entry point—is through transfer from pediatric to ACHD providers. Patients who navigate transfer of care successfully may have a greater chance of remaining in care. However, many patients are lost to care before transfer can occur, and others who are referred for transfer do not do so successfully because of substantial barriers.

Once lost to care, patients may be referred to an ACHD cardiologist/program by general cardiologists, primary care physicians, and obstetrician-gynecologists, or they may enter ACHD care after a cardiovascular event or hospitalization. Despite those known pathways to lifelong ACHD care, many patients are lost to care, and their care pathways remain unknown.

### 3.2. Expertise for Noncardiac Surgery

**Recommendations for Expertise for Noncardiac Surgery**  
 Referenced studies that support recommendations are summarized in the [Evidence Table](#).

COR	LOE	RECOMMENDATIONS
1	B-NR	1. In patients with ACHD being considered for noncardiac procedures, preprocedural involvement of an ACHD cardiologist is recommended to risk-stratify the patient, determine appropriate procedure location, guide periprocedural planning and support, and assist in preprocedural clinical optimization to improve outcomes. <sup>1,2</sup>
1	B-NR	2. In patients with ACHD AP classifications IC-D, IIB-D, and IIIA-D who undergo noncardiac procedures, postprocedural care should involve collaboration with an ACHD cardiologist to incorporate expert opinion, provide guideline-based therapy, and improve outcomes. <sup>1-3</sup>
1	C-LD	3. In patients with ACHD AP classifications IC-D, IIC-D, and IIIA-D, anesthesia for noncardiac procedures should be administered by, or in collaboration or consultation with, an anesthesiologist with ACHD expertise to reduce the likelihood of perioperative complications. <sup>4-6</sup>

#### Synopsis

Patients with ACHD have greater operative risk than those without ACHD for noncardiac surgery. The 2023 “Perioperative Considerations for Pediatric Patients With Congenital Heart Disease Presenting for Noncardiac Procedures: A Scientific Statement From the American Heart Association”<sup>7</sup> and the “2014 ACC/AHA Guideline on Perioperative Cardiovascular Evaluation and Management of Patients Undergoing Noncardiac Surgery”<sup>8</sup> may be consulted, but whether they apply directly to the ACHD population is unknown. Because of differences in underlying pathophysiology between congenital and acquired heart disease, as well as the influence of age on the natural history of congenital heart disease, the evidence

supporting recommendations regarding risk indices and management strategies may not apply to many patients with ACHD. Given the ACHD population’s heterogeneity, input from appropriate specialists should inform how individualized pre- and perioperative management plans are formulated, to account for hemodynamic, hematologic, and end-organ considerations.

#### Recommendation-Specific Supportive Text

1. Case series and analyses of administrative databases confirm that noncardiac surgical procedures carry greater risk in patients with ACHD than in those without ACHD, and that the risk is influenced by congenital heart disease lesion, type of surgical procedure, urgency of intervention, and availability of specialized resources; therefore, before proceeding to surgery, consider individualized risks and benefits.<sup>1,2,4,5,9-12</sup> Patients with ACHD may have nonroutine and unusual physiological challenges (eg, fluid balance for a palliated single ventricle or the impact of vascular resistances on shunts in patients with cyanosis).<sup>5,7,13-17</sup> When possible, patients with ACHD, especially those with more complex stages of disease (ACHD anatomic classification II or III) and/or those with significant residual disease (ACHD physiological stages C and D), should receive preoperative evaluation and surgery or other nonsurgical interventions at a center with an ACHD program.<sup>18,19</sup> Given geographic and other limitations in obtaining care at an ACHD center, careful procedural planning in consultation with an ACHD physician may be the best alternative. Well-delineated plans should guide timely management of the anticipated physiological challenges in patients with ACHD, related to medications, fluid balance, vascular resistance, and shunts. **Table 8** presents a checklist of considerations in assessing and managing patients with ACHD who undergo noncardiac surgery.
2. Postoperative collaboration with an ACHD physician is important to help with timely management of ACHD-specific complications related to the individual’s physiology. Even with ideal preprocedural planning, postoperative complications are prevalent in this population, especially in patients with more complex disease and those with more significant residual lesions.<sup>1,2,4,7,10-12,16</sup> Expedient, appropriate responses to postoperative fluid shifts, blood pressure variation,

**TABLE 8** Preoperative Checklist for Noncardiac Surgery in Patients With ACHD**Clarify clinical information related to congenital heart disease**

- Clarify prior procedures, residua, sequelae, and current status, including ACHD anatomic-physiological classification.
- Develop management strategies for preoperative optimization to minimize risk and improve postprocedural outcome.

**Factors associated with increased risk for perioperative morbidity and mortality<sup>2,12,26</sup>:**

- Cyanosis
- Complex congenital heart disease
- Frailty
- Heart failure
- Operations on the respiratory and nervous systems
- Pulmonary hypertension
- Urgent/emergency procedures

**Issues to consider:**

- Arrhythmias, including bradyarrhythmias
- Abnormal venous and/or arterial anatomy affecting venous and arterial access and blood pressure monitoring
- Adjustment of anticoagulant volume in tubes for some blood work in patients with cyanosis
- Developmental disability
- Differential dependence on preload/afterload and impacts on ventilation and/or insufflation strategies
- Endocarditis prophylaxis
- Erythrocytosis
- Monitoring of renal and liver function
- Need for meticulous line care (consider air filters for intravenous lines) to reduce risk for paradoxical embolism in patients with reduced oxygen saturations because of right-to-left shunts
- Periprocedural anticoagulation
- Persistent shunts
- Prevention of venous thrombosis
- Pulmonary vascular disease
- Valvular disease
- Ventricular function (systemic and/or subpulmonary)

Modified with permission from Stout et al.<sup>27</sup> Copyright 2018 American Heart Association, Inc. and American College of Cardiology Foundation.

ACHD indicates adult congenital heart disease.

oxygenation/ventilation, and arrhythmias are critical to achieving optimal outcomes and depend on thoroughly understanding each patient's physiology. Early extubation, for instance, is of particular importance in patients with Fontan physiology and patients with pulmonary vascular disease, given the deleterious effects of positive pressure ventilation on transpulmonary gradient and systemic ventricular preload.<sup>3,5,13,16,17</sup>

3. Patients with ACHD require specialized planning and management to avoid complications of anesthesia.<sup>4,5,16</sup> Anesthesiologists without specific fellowship training in pediatric or cardiac anesthesia often have minimal experience managing patients with

ACHD; in a national survey of practicing anesthesiologists, the majority reported being uncomfortable managing patients with ACHD, especially those with complex disease.<sup>6,20</sup> Considerations include optimization of preload and afterload, selection of vasoactive medications, and ventilator strategies, each of which may affect pulmonary vascular resistance (PVR), hemodynamics, or arrhythmia. Patients may also have risk for coagulopathy or paradoxical embolism (in patients with right-to-left shunts), requiring adjustment in intravascular line management.<sup>13-17,21-25</sup> Even patients with anatomically simple lesions may have complex physiology (eg, a patient with a ventricular septal defect [VSD] and Eisenmenger syndrome) that requires specialized anesthetic considerations.

**3.3. Mental Health and Neurocognitive Assessment**

**Recommendations for Mental Health and Neurocognitive Assessment**  
Referenced studies that support recommendations are summarized in the Evidence Table.

COR	LOE	RECOMMENDATIONS
1	C-LD	1. Adults with congenital heart disease should be assessed for mental health conditions, including depression, anxiety, and post-traumatic stress disorder, to identify those who may benefit from mental health services. <sup>1,2</sup>
2a	C-LD	2. For adults with congenital heart disease who have mental health concerns, referral to a mental health clinician can be beneficial to improve psychological symptoms and quality of life. <sup>3</sup>
2b	B-NR	3. For adults with congenital heart disease, neuropsychological testing may be considered to guide therapies that enhance academic, behavioral, psychosocial, and adaptive functioning. <sup>4-6</sup>
2b	C-LD	4. For adults with congenital heart disease, evaluation for cognitive decline and frailty may be considered to identify patients who can benefit from additional support. <sup>7,8</sup>

## Synopsis

Mental health and neurocognitive concerns are common in adults with congenital heart disease and may substantially affect quality of life. Mental health conditions—including depression, anxiety, and posttraumatic stress disorder—have been identified in up to 50% of adults with congenital heart disease. Depression in this population is associated with impaired functional status, heart failure, and increased adverse outcomes<sup>9</sup> that can lead to worse clinical profiles and greater health care utilization.<sup>9,10</sup> Illness identity—and the extent to which a congenital heart disease diagnosis affects a patient's self-perception—predicts health care utilization.

Neurocognitive differences are more frequently seen in children with congenital heart disease who have complex conditions, complex surgical repairs, and genetic syndromes, such as 22 q11.2 and Turner syndrome. These differences are also noted in adults but not well studied. Frailty and cognitive decline are noted in more than a third of adults with congenital heart disease who are older than 40 years.<sup>7</sup>

## Recommendation-Specific Supportive Text

1. Although prevalent in patients with ACHD, anxiety, depression, and posttraumatic stress disorder often go unrecognized<sup>1</sup> and may be associated with impaired functional status, heart failure, and an increased risk for adverse outcomes.<sup>9</sup> Chronic uncertainty regarding illness course and outcome may increase the risk for posttraumatic stress disorder in patients with ACHD.<sup>11,12</sup> During clinic visits, patients should be asked about mental health. Review of symptoms can include inquiring about anxiety and depression. Although self-reported symptoms are insufficient for identifying mood disorders, using assessment tools can initiate a discussion and may lead to further evaluation and, when a screen is positive, referral to a mental health clinician. Multiple validated screening tools can be used to improve discussion about treatment options.<sup>13,14</sup>
2. For patients with ACHD who have mental health conditions, referral to a mental health clinician is most useful when it is timely. Patients may see their congenital heart disease as part of their identity and the extent to which their diagnosis is integrated into their self-perception predicts health care utilization.<sup>15</sup>
3. Although evidence on neurocognitive and neuropsychological issues in patients with ACHD is limited, data on the neurodevelopmental and neuropsychological impact of congenital heart disease and surgery in childhood are increasing.<sup>16</sup> That impact is likely to persist into adulthood and may manifest in lower educational and occupational achievement.<sup>17-19</sup> However, patients with ACHD may not have been evaluated for mental health conditions as children as current diagnostic and treatment guidance suggests they should. Neuropsychological testing should include standardized tests and questionnaires administered by qualified professionals.<sup>20</sup> Appropriate diagnosis, treatment, and rehabilitation may be beneficial in optimizing cognitive function and quality of life. Problems with executive function may affect later adaptive coping skills and psychological distress in adolescents and young adults.<sup>20-23</sup>
4. Adults with congenital heart disease may have cognitive decline (38% of patients), frailty (6%), and prefrailty (42%) that may manifest as people age,<sup>7</sup> with an increased risk for early-onset dementia.<sup>24</sup> Having any type of congenital heart disease may lead to decline in physical activity, unplanned weight reduction, and fatigue. Symptoms such as fatigue, unintentional weight loss, and a decline in physical activity may be related to this cognitive decline and should be distinguished from cardiac symptoms. Recognizing and addressing those changes may improve patient-clinician communication, patient care, and quality of life and may reduce health care utilization. In other patient populations, potential interventions include aerobic resistance exercise and cognitive training.<sup>8</sup>

### 3.4. Expertise for Cardiac Surgery and Invasive Cardiac Procedures

**Recommendations for Expertise for Cardiac Surgery and Invasive Cardiac Procedures**  
Referenced studies that support recommendations are summarized in the [Evidence Table](#).

COR	LOE	RECOMMENDATIONS
1	B-NR	1. In patients with ACHD who undergo invasive cardiac procedures, preprocedural involvement of an ACHD cardiologist is recommended to risk-stratify the patient, determine appropriate procedure location, guide periprocedural planning and support, and assist in preprocedural clinical optimization to improve outcomes. <sup>1-3</sup>
1	B-NR	2. In patients with ACHD, invasive cardiac procedures involving congenital lesions should be performed by operators with expertise in congenital heart disease procedures to ensure appropriate periprocedural care. <sup>4,5</sup>
1	C-LD	3. In patients with ACHD undergoing invasive cardiac procedures, postprocedural care should involve collaboration with an ACHD cardiologist to incorporate expert opinion, provide guideline-based therapy, and improve outcomes. <sup>1,3,4</sup>
1	C-LD	4. In patients with ACHD AP classifications IC-D, IIA-D, and IIIA-D, anesthesia for invasive cardiac procedures should be administered by, or in collaboration or consultation with, an anesthesiologist who has congenital heart disease expertise to reduce the likelihood of perioperative complications. <sup>2,3,6,7</sup>
2a	B-NR	5. In patients with ACHD who undergo invasive cardiac procedures for acquired cardiovascular disease, it can be beneficial for operators with expertise in procedural treatment of acquired disease to collaborate with ACHD experts. <sup>8-10</sup>

#### Synopsis

Patients with ACHD often have complex underlying cardiac anatomy and physiology, which increases the technical and medical risks of invasive cardiac

procedures such as cardiac surgery, cardiac catheter-based procedures, and electrophysiologic procedures. Periprocedural care (preprocedural evaluation, clinical management during the procedure, and postprocedural care) for invasive procedures should involve collaboration with an ACHD cardiologist. Anesthesia for cardiac procedures, high-risk surgery, and for high-risk patients should be administered by, or in collaboration with, an anesthesiologist who has experience with patients with ACHD. Cardiac surgery and cardiac catheter-based procedures, including electrophysiology device implantation, should be performed by cardiologists and surgeons with expertise in managing patients with ACHD. Acquired cardiac disease in patients with ACHD should be managed collaboratively by operators with expertise in congenital and acquired disease. Expertise in ACHD varies across medical and surgical specialties. Some specialties, such as cardiology and congenital heart surgery, have specific ACHD fellowship training and board certification; in other specialties, ACHD expertise is gained from focused experience during training and practice. Clinicians trained outside the United States may have different pathways to ACHD expertise.

#### Recommendation-Specific Supportive Text

- In patients with ACHD, the presence of AP complexity from the lesion or surgical palliation may change the overall care plan and procedural decision-making. Data obtained during invasive ACHD cardiac procedures are difficult to contextualize without specialized knowledge of congenital disease. Patients with ACHD present with nonroutine and uncommon physiological challenges (eg, fluid balance in the setting of a palliated single ventricle or the impact of vascular resistances on shunts in patients with cyanosis).<sup>2,3</sup> Patients with complex AP forms of ACHD may need evaluation and treatment approaches that differ from those for adults without congenital conditions who have valve disease, heart failure, or arrhythmias. Evidence suggests that when they are managed by specialized practitioners, patients with ACHD are more likely to receive guideline-based therapy with fewer adverse clinical consequences.<sup>1</sup> Consultation and collaboration with an ACHD cardiologist provide expert guidance, which is fundamental to designing an appropriate therapeutic plan that reduces procedure-related morbidity and improves outcomes.
- Patients with ACHD who undergo invasive cardiac procedures in specialized ACHD centers generally have better outcomes, including survival, than those managed in other care settings.<sup>4</sup> Ensuring appropriate periprocedural care requires special attention, such as identifying procedure-related risk factors and

availability of ancillary imaging.<sup>4,5,11,12</sup> It is challenging to assess the risk associated with invasive cardiac procedures in patients with ACHD who were excluded when procedural risk-scoring systems for adults were developed.<sup>13</sup> The involvement of ACHD-experienced surgeons, interventional cardiologists, and electrophysiologists facilitates appropriate planning and care delivery for patients with congenital lesions.

3. Expertise in managing the unique physiology of patients with ACHD can reduce procedure-related morbidity and improve postprocedural follow-up care and outcomes.<sup>1,3</sup> Patients with ACHD who are not managed by specialized ACHD practitioners have a higher risk for adverse events when pertinent clinical care guidelines are not followed.<sup>1,4</sup> Collaboration with an ACHD cardiologist can offer the requisite expert guidance.
4. Patients with ACHD have complex AP sequelae from their defect or prior surgical palliation. Operators must consider their underlying cardiac physiology and hemodynamics, as well as the effects of anesthetic medications and ventilation strategies. Such ACHD-specific changes may cause cardiovascular and respiratory alterations during invasive procedures that may be unfamiliar to anesthesiologists without ACHD experience.<sup>2,3,6,7</sup> Experience and expertise in managing congenital heart disease physiology ensures safe delivery of anesthesia and appropriate periprocedural resuscitation. Although ACHD-specific training is not available for cardiac anesthesiologists, many develop expertise through advanced training in pediatric or adult congenital cardiac anesthesiology, mentoring, and practice experience.
5. With increased longevity, patients with ACHD are at risk of developing acquired cardiovascular disease (eg, obstructive coronary artery disease, noncongenital aortic aneurysm, calcific valvar stenosis, arrhythmia). Operative and catheter-based repair of acquired disease (especially coronary disease) is rarely performed by congenital surgeons or congenital interventional cardiologists. Operator experience with those procedures correlates with improved outcomes.<sup>8-10</sup> Attention to the unique anatomy and physiology of patients with ACHD is essential. Depending on provider experience and case complexity, this collaborative effort may include a co-surgeon model that involves an ACHD expert and an acquired disease expert.

### 3.5. Management of Cyanosis

**Recommendations for Management of Cyanosis**  
 Referenced studies that support recommendations are summarized in the [Evidence Table](#).

COR	LOE	RECOMMENDATIONS
1	B-NR	1. Patients with ACHD and cyanosis should receive annual screening for and treatment of iron deficiency to improve exercise capacity and functional status. <sup>1</sup>
1	B-NR	2. In patients with ACHD and cyanosis who present with persistent, new, or worsening neurologic deficits, urgent brain imaging to exclude cerebral abscess or stroke should be performed. <sup>2,3</sup>
1	B-NR	3. In patients with ACHD and cyanosis who present with symptoms of hyperviscosity, rehydration with oral or intravenous fluids should be performed to improve symptoms and reduce the risk for vascular complications. <sup>4</sup>
1	B-NR	4. Pregnant patients with ACHD and cyanosis should be closely followed for the entire duration of the pregnancy by a multidisciplinary cardio-obstetrics team of experts in maternal-fetal medicine, ACHD, and obstetric anesthesia to reduce the risk for pregnancy-related cardiovascular and obstetric complications. <sup>5</sup>
1	C-EO	5. Patients with ACHD and cyanosis who are of childbearing age should receive comprehensive family planning consultation, including recommendations on safe and reliable contraceptive methods, from a multidisciplinary team of experts in family planning and ACHD.
2a	B-NR	6. In patients with ACHD and cyanosis who experience recurrent unexplained hypertension or tachycardia, evaluation to detect pheochromocytomas and paragangliomas is reasonable. <sup>6,7</sup>

*Continued on the next page*

Continued		
COR	LOE	RECOMMENDATIONS
2a	B-NR	7. In patients with ACHD, cyanosis, and recurrent episodes of joint pain, it is reasonable to check serum uric acid levels and evaluate for gout. <sup>8,9</sup>
2b	B-R	8. In patients with ACHD and cyanosis, the use of supplemental oxygen during exercise may be considered to improve exercise capacity. <sup>10</sup>
2b	C-EO	9. In patients with ACHD, hematocrit >65%, and hyperviscosity symptoms that persist despite adequate rehydration and treatment of iron deficiency, phlebotomy may be considered.
3: No Benefit	B-NR	10. In patients with ACHD and cyanosis, prophylactic phlebotomy is not recommended. <sup>2</sup>

### Synopsis

Cyanotic heart disease is a heterogeneous group of congenital heart defects that is characterized by hypoxemia and central cyanosis caused by right-to-left shunting.<sup>11</sup> Cyanosis often presents as bluish discoloration of skin and/or mucous membranes, although detection may be difficult in patients with anemia or those with dark skin pigmentation.<sup>12</sup>

Chronic hypoxemia triggers an increase in red cell mass (secondary erythrocytosis)—a normal physiological response aimed at achieving and maintaining optimal hemoglobin and hematocrit.<sup>13,14</sup> However, increases in red cell mass deplete bone marrow iron stores, prompting iron-deficiency anemia.<sup>15</sup> Iron-deficiency anemia, in turn, compromises systemic oxygen transport, manifesting clinically as exercise intolerance, transient ischemic attack, stroke, and myocardial ischemia.<sup>13,14</sup> Patients with ACHD and cyanosis can also present with hyperviscosity symptoms, such as headache and visual disturbance.<sup>2,14</sup>

Cyanosis is associated with altered coagulation cascade, leading to both hypo- and hypercoagulability, with consequent increases in the risks for bleeding (hemoptysis and epistaxis) and thrombosis (transient ischemic attack/stroke, pulmonary embolism).<sup>16-19</sup> The

role of thromboprophylaxis in cyanotic ACHD patients is unclear, meriting individualized approaches to anti-coagulation and antiplatelet therapy.<sup>20</sup> Appropriate precautions should be taken when assessing coagulation parameters, such as the measurement of international normalized ratio.<sup>21</sup>

Chronic cyanosis affects multiple organ systems and can manifest with kidney dysfunction, hypertrophic osteoarthropathy, myocardial dysfunction, neurologic dysfunction, and hypertensive emergency due to neuroendocrine tumors such as pheochromocytomas and paragangliomas.<sup>6,19,22</sup> Ongoing surveillance is crucial for early detection of end-organ dysfunction.

### Recommendation-Specific Supportive Text

1. Iron deficiency is common in patients with ACHD and cyanosis because of depletion of bone marrow iron stores from secondary erythrocytosis.<sup>13-15</sup> Patients with ACHD and cyanosis should undergo routine screening for iron deficiency because deficiency can occur even when hematocrit levels are either normal or elevated.<sup>13-15</sup> Treatment of iron deficiency is safe and associated with improved exercise capacity and quality of life.<sup>1</sup>
2. Patients with ACHD and cyanosis, especially those with Eisenmenger syndrome, have increased risk for neurologic complications, such as stroke and brain abscess.<sup>2,3</sup> Urgent brain imaging to exclude brain abscess or stroke should be considered when patients with ACHD and cyanosis present with new or worsening headache or neurologic symptoms.<sup>2,3</sup>
3. When increased red cell mass leads to symptoms of hyperviscosity, symptom severity correlates with hematocrit level.<sup>13,14</sup> Associated headaches, visual disturbances, and neurologic symptoms can mimic stroke or transient ischemic attack.<sup>4</sup> A diagnosis of hyperviscosity syndrome should be considered when a patient with hyperviscosity symptoms has severely elevated hematocrit (>65%), after brain imaging excludes acute neurologic events. Most of the affected patients respond to rehydration with oral or intravenous fluid and to treatment of iron-deficiency anemia (Figure 1).<sup>4</sup>
4. Pregnancy in patients with ACHD and cyanosis is associated with high risks for cardiovascular and obstetric complications.<sup>23</sup> However, multidisciplinary care during and after pregnancy in this population (excluding patients with Eisenmenger syndrome) has

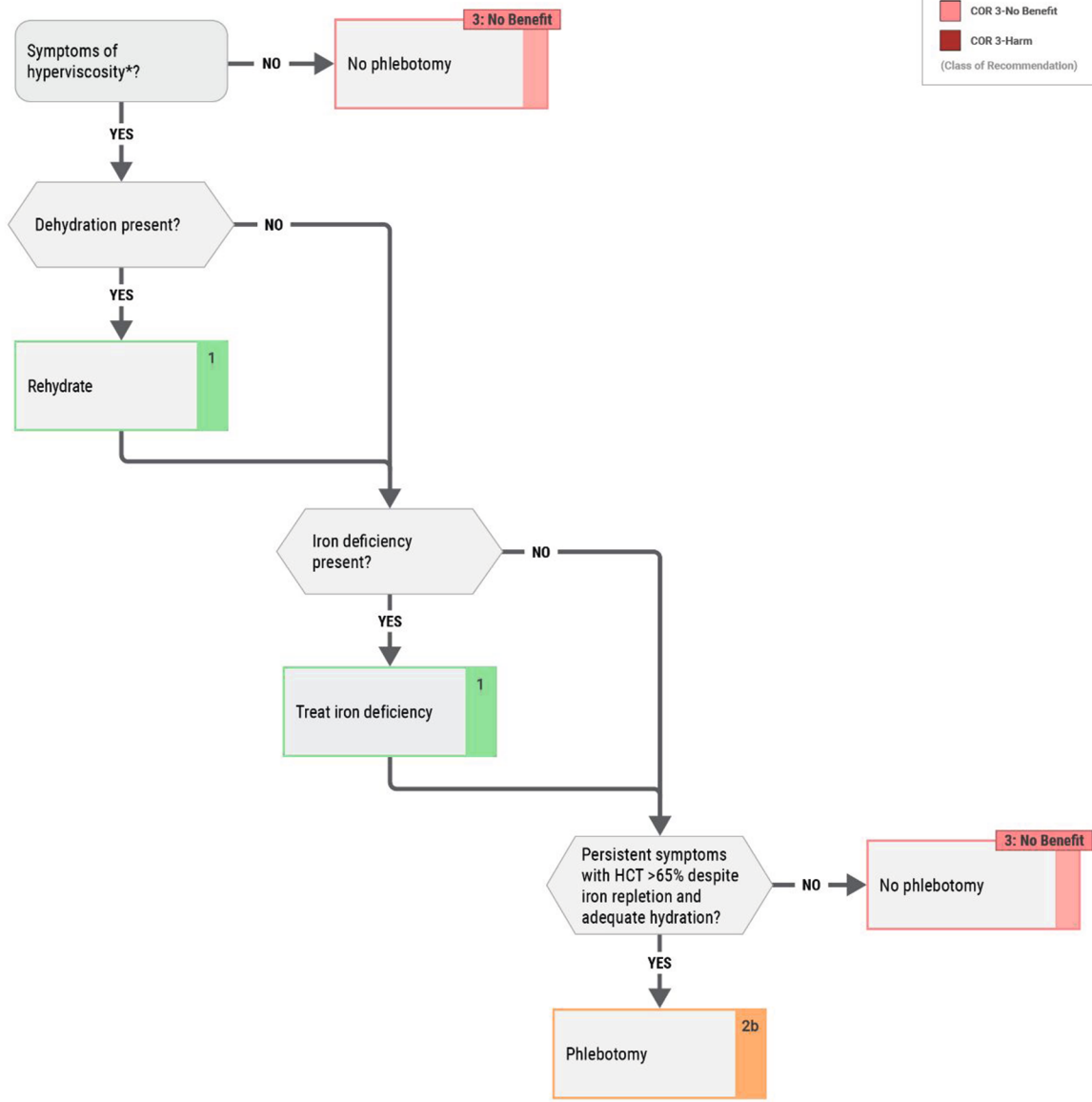
**FIGURE 1** Management of Hyperviscosity Symptoms in Cyanotic ACHD

## Management of Hyperviscosity Symptoms in Cyanotic ACHD

**LEGEND**

- COR 1
- COR 2a
- COR 2b
- COR 3-No Benefit
- COR 3-Harm

(Class of Recommendation)



\*All patients should have at least annual screening for iron deficiency. ACHD indicates adult congenital heart disease; and HCT, hematocrit.

been associated with lower risk for cardiovascular complications, compared with historical data.<sup>5</sup>

5. The risks of pregnancy-related cardiovascular, obstetric, and neonatal complications increase with congenital heart disease complexity, with risks significantly greater in patients with cyanosis than in those without cyanosis.<sup>23-25</sup> Furthermore, certain contraceptive methods, such as estrogen-containing oral contraceptive pills, are associated with increased risks for venous and arterial thromboembolic complications—and should be avoided in patients with ACHD and cyanosis.<sup>25-27</sup> Safe, reliable contraceptive therapies are critical for patients with ACHD and cyanosis who do not seek to become pregnant.<sup>25-27</sup>
6. Pheochromocytomas and paragangliomas are rare neuroendocrine tumors that produce excess catecholamines, resulting in episodic tachycardia or hypertension.<sup>6,7</sup> A higher prevalence of those tumors has been observed in patients with ACHD and cyanosis, presumably related to chronic hypoxemia-induced proliferation of chromaffin cells. As a result, patients with ACHD and cyanosis who have episodes of tachycardia or hypertension should be screened for pheochromocytomas and paragangliomas, with an initial workup that includes measurement of plasma fractionated metanephrines and 24-hour urinary fractionated metanephrines.<sup>6,7</sup>
7. Hyperuricemia is common in ACHD patients with cyanosis.<sup>8,9</sup> ACHD patients with cyanosis presenting with joint pain should be evaluated for gout.
8. Patients with ACHD and cyanosis have reduced exercise capacity. The use of supplemental oxygen during exercise is associated with improved exercise capacity, compared with ambient air.<sup>10</sup>
9. Phlebotomy involves removal of 250 to 500 mL of blood, with concurrent volume replacement of 250 to 500 mL of isotonic fluid. Phlebotomy may be considered in patients with refractory symptoms of hyperviscosity syndrome after adequate hydration with oral or intravenous fluid and adequate correction of iron deficiency (Figure 1).<sup>4,21</sup> Another indication for preoperative phlebotomy for autologous blood transfusion may be if the patient's hematocrit level is >65%.<sup>21</sup>
10. Prophylactic phlebotomy should be avoided in patients with ACHD and cyanosis because it exacerbates iron deficiency and increases stroke risk.<sup>2,4</sup> It should not be used as the primary treatment in patients with hyperviscosity symptoms or in asymptomatic

patients with elevated hematocrit, as the effect on hematocrit is transient.<sup>2,4</sup>

### 3.6. Heart Failure and Transplantation

#### 3.6.1. Heart Failure

**Recommendations for Heart Failure**  
Referenced studies that support recommendations are summarized in the Evidence Table.

COR	LOE	RECOMMENDATIONS
2a	B-NR	1. In patients with ACHD and heart failure symptoms who have systemic left ventricular (LV) dysfunction and biventricular circulation, and who otherwise meet accepted criteria for cardiac resynchronization therapy (CRT), use of CRT is reasonable to improve heart failure symptoms. <sup>1-4</sup>
2a	C-LD	2. In patients with ACHD and heart failure symptoms who have systemic LV systolic dysfunction and biventricular circulation, use of GDMT for heart failure is reasonable to improve heart failure symptoms. <sup>2,5-7</sup>
2a	C-LD	3. In patients with ACHD and heart failure symptoms who have systemic LV dysfunction and biventricular circulation, who otherwise meet accepted criteria, use of a primary-prevention implantable cardioverter-defibrillator (ICD) is reasonable to prevent sudden cardiac death (SCD). <sup>8,9</sup>

#### Synopsis

Heart failure<sup>10</sup> is a significant source of morbidity and mortality in patients with ACHD, placing them at high risk for SCD.<sup>11</sup> Despite advancements in the understanding of heart failure epidemiology, outcomes, and therapies—including GDMT, mechanical circulatory support, and transplantation—data to guide treatment recommendations for patients with ACHD remains limited.<sup>12</sup>

The randomized clinical trials showing that GDMT, CRT, and ICDs improve outcomes in heart failure exclude patients with ACHD. In addition, patients with ACHD and heart failure exhibit a wide range of native and post-operative anatomic configurations, including biventricular or single-ventricle physiologies, and the presence

of either a systemic left ventricle or a systemic right ventricle. The biventricular circulation and systemic left ventricle share the greatest anatomic and physiological similarities with heart failure patients in clinical trials; extrapolation from the heart failure literature is most appropriate in this population.

Given the wide anatomic and physiological variation in ACHD, the benefits and harms from therapy likely differ from those in patients without ACHD. For example, some patients with ACHD may be predisposed to bradyarrhythmia or endocarditis, which could counterbalance the benefits of beta blockers or device therapy, respectively. Therefore, both the strength of recommendation and the level of evidence for the use of GDMT and device therapy in patients with ACHD and heart failure are lower, compared with recommendations for patients without ACHD, in whom large, randomized trials show benefits. Other challenges in implementing GDMT are the effects of restrictive physiology, multimorbidity, frailty, and polypharmacy, particularly in older patients with ACHD.

The role of GDMT, ICDs, and CRT in patients with single-ventricle (Fontan) physiology or systemic right ventricles (dextro-TGA with atrial switch or congenitally corrected transposition of the great arteries [CCTGA]) is discussed in pertinent other sections of this guideline.

### Recommendation-Specific Supportive Text

1. CRT attempts to optimize the overall pattern of ventricular activation and myocardial contraction through either biventricular or conduction-system pacing. Data from well-designed randomized clinical trials in the general population of adults with heart failure that are related to electrical dyssynchrony demonstrate substantial clinical improvement following CRT, including improvements in quality of life, heart failure hospitalization, cardiac remodeling, and overall survival.<sup>13-15</sup> Similarly, for patients with congenital heart disease, large observational studies have generally reported clinical benefit after implementation of biventricular CRT, especially for patients with systemic LV morphology.<sup>16-18</sup> In studies predominantly involving patients with ACHD and a systemic left ventricle, clinical improvement following CRT is reported in 65% to 77% of participants,<sup>18-21</sup> and multivariable comparisons of ACHD with acquired heart disease patients suggest similar outcomes in terms of heart failure hospitalization and overall mortality.<sup>22</sup> Given satisfactory outcomes for ACHD with systemic LV morphology<sup>18</sup> and the shared pathophysiology for electromechanical dyssynchrony-related heart failure, extrapolation from acquired heart disease represents a rational approach to ACHD patients with heart failure, reduced systemic LV ejection fraction, and electrical

dyssynchrony. Existing evidence for CRT and other anatomic substrates is addressed separately in [Sections 4.4.2](#), “Management of CCTGA” and [4.4.1.1](#), “Patients With dextro-Transposition of the Great Arteries and Atrial Switch” of this guideline.

2. The evidence of benefit from GDMT<sup>12</sup> in patients with ACHD and biventricular circulation with systemic LV systolic dysfunction is mostly limited to retrospective studies. In a large, single-center retrospective study of ACHD patients with biventricular circulation and a systemic left ventricle, the use of GDMT in patients with LV systolic dysfunction was associated with improvement in LV ejection fraction, heart failure symptoms, and biomarkers.<sup>2</sup> Newer therapies, including angiotensin receptor-neprilysin inhibitors<sup>23,24</sup> and sodium-glucose cotransporter 2 inhibitors,<sup>5,7</sup> appear to be well tolerated and safe. In retrospective studies, the use of angiotensin receptor-neprilysin inhibitors and sodium-glucose cotransporter 2 inhibitors are associated with reduced heart failure hospitalizations as well as improved New York Heart Association functional class, biomarkers, and LV function.<sup>5,6</sup>

3. SCD accounts for up to 25% of mortality in congenital heart disease populations,<sup>25,26</sup> and the risk for SCD in patients with ACHD is markedly increased (25- to 100-fold) compared with that in the general population.<sup>27</sup> Many observational studies have attempted to quantify SCD risk in patients with ACHD and provide useful data for clinical care. For instance, data derived from the CONCOR registry were used to develop a disease-specific risk calculator that estimates annual SCD risk for key forms of ACHD.<sup>28</sup> Similarly, risk factors specific to anatomic ACHD substrates, such as Ebstein anomaly,<sup>29</sup> postoperative Fontan,<sup>30-32</sup> and systemic right ventricle,<sup>33,34</sup> have been proposed and utilized to inform risk assessment, but they remain unvalidated. Further, no randomized clinical trials establish clinical benefit for primary-prevention ICD placement in patients with ACHD. Instead, data from noncongenital, acquired heart disease populations provide the strongest evidence for survival benefit after ICD placement in patients with systemic LV morphologies. Multiple randomized controlled trials in acquired heart disease show improved outcomes for patients with severe LV systolic dysfunction (LV ejection fraction  $\leq 35\%$ ) and evidence of clinical heart failure (New York Heart Association functional class II-III). Furthermore, no randomized clinical trials establish the clinical benefit of primary-prevention ICD placement in patients with ACHD, and there is a high rate of inappropriate shocks with primary-prevention ICDs in patients with tetralogy of Fallot (TOF).<sup>35,36</sup>

## 3.6.2. Heart Transplantation and MCS

**Recommendations for Heart Transplantation and MCS**  
Referenced studies that support recommendations are summarized in the [Evidence Table](#).

COR	LOE	RECOMMENDATIONS
1	B-NR	1. In patients with ACHD and heart failure, evaluation by specialists with medical and surgical experience in ACHD, as well as by specialists with expertise in advanced heart failure, is recommended to assess appropriateness for advanced heart failure therapies, such as heart transplantation or MCS. <sup>1,2</sup>
2a	B-NR	2. In patients with ACHD who are considered for heart transplantation, multiorgan transplantation (heart-lung, <sup>3</sup> heart-kidney, <sup>4</sup> or heart-liver <sup>5,6</sup> ) is reasonable based on center-specific assessment of the degree of respective lung, kidney, or liver dysfunction.
2a	B-NR	3. In patients with ACHD and advanced heart failure that is refractory to optimal medical and device-based therapy, the use of durable MCS devices is reasonable to improve quality of life or as a bridge to transplantation. <sup>7-10</sup>

**Synopsis**

Despite successful interventions to repair cardiac anatomy, many adults with ACHD experience long-term morbidity and reduced survival, relative to the general population, with heart failure as a leading cause of death.<sup>11-16</sup> For many patients with complex congenital heart disease, sensitization—from prior transfusions or from existing homografts—adds risk and complexity to early postoperative and long-term management.<sup>17-19</sup> However, patients with ACHD have benefited from increased priority in the new United Network of Organ Sharing allocation system to reduce waitlist time and mortality.<sup>20,21</sup> Despite high early posttransplant mortality,<sup>22-25</sup> patients with ACHD have equal or even superior long-term survival,<sup>26</sup> particularly when cared for at high-volume centers<sup>2</sup> with ACHD accreditation.<sup>1</sup> The

thresholds for multiorgan transplantation (heart-lung, heart-liver, and heart-kidney) remain center-specific, with a focus on heart-liver transplantation in patients with failing Fontan physiology. Temporary<sup>7,27</sup> and durable<sup>7,8,28</sup> MCS are less well studied and used in selected patients with appropriate anatomy and extracardiac organ function. Temporary MCS includes implantable vascular devices, typically placed for urgent stabilization of cardiogenic shock. Durable MCS devices offer LV or biventricular support, are surgically implanted, allow for hospital discharge, and may be used as a bridge to transplantation or destination therapy. The “2022 AHA/ACC/HFSA Guideline for the Management of Heart Failure”<sup>29</sup> provides important recommendations regarding hospitalization and post-discharge follow-up that may be applied to the ACHD population.

**Recommendation-Specific Supportive Text**

1. Many causes of heart failure symptoms in patients with ACHD may be reversible, including valve dysfunction, shunts, arrhythmias, venous obstruction, and ventricular dysfunction, which require evaluation and treatment in an ACHD program whenever possible. However, heart failure-related hospital admissions,<sup>30-35</sup> as well as the development of systemic ventricular dysfunction and protein-losing enteropathy,<sup>36</sup> are associated with worse outcomes and would be appropriate triggers for evaluation for advanced heart failure therapies, including transplantation. Nonetheless, patients with ACHD who undergo heart transplant evaluation may not be candidates because of delays in referral that result in prohibitive risk from extracardiac organ dysfunction<sup>26,36,37</sup> and, even when listed, have high waitlist-period mortality.<sup>38</sup> No clear ACHD-specific markers for advanced heart failure exist. Traditional advanced heart failure criteria are useful,<sup>29</sup> including objective assessments of deterioration in functional capacity based on cardiopulmonary exercise stress testing (CPET).<sup>39</sup> Heart transplantation candidates with ACHD often receive care at centers with established medical and surgical experience in ACHD and transplantation, to confirm that nontransplant medical, interventional, and surgical therapies have been exhausted and to ensure timely referral for advanced heart failure therapies, including transplantation, when appropriate.
2. The thresholds for multiorgan transplantation remain center-specific. Heart-lung transplantation is an

option for patients with Eisenmenger syndrome<sup>40</sup> (although incidence is declining over time,<sup>3</sup> and lung transplant with concurrent repair of the congenital heart defect may be an option<sup>41</sup>). Heart-lung transplantation carries the greatest risk for posttransplant mortality but is comparable to that in non-ACHD heart-lung transplant recipients.<sup>4</sup> Heart-kidney transplantation, an option for patients with advanced kidney disease, portends no increased post-transplantation risk in patients with ACHD.<sup>4</sup> Heart-liver transplantation receives the most attention, given the prevalence of advanced liver fibrosis in patients late after Fontan palliation. Adults with Fontan palliation have high early mortality after heart transplantation,<sup>42</sup> especially if markers for failing Fontan physiology are present.<sup>6</sup> Even after heart-liver transplantation, patients with Fontan palliation have more perioperative complications,<sup>5,43</sup> although longer-term outcomes are comparable with those in non-ACHD patients who undergo heart-liver transplantation<sup>4</sup> and with those in patients with ACHD who undergo heart transplantation alone<sup>44,45</sup> (the latter analyses were not restricted to patients with ACHD and Fontan palliation). Nonetheless, the threshold for heart-liver transplantation remains unclear, as some patients experience improvement in hepatic function after heart transplantation alone<sup>46,47</sup>; thus, identifying the specific indications for heart-liver transplantation remains a challenge.

3. Patients with ACHD who undergo durable MCS have longer lengths of hospital stay after implantation but similar rates of post-MCS adverse effects and re-hospitalization, as well as similar improvements in quality of life, compared with patients without ACHD who undergo durable MCS.<sup>10</sup> Mortality risk is greater in patients who require biventricular durable MCS.<sup>10,48</sup> Among heart transplantation candidates, those with ACHD are less likely to undergo durable MCS than are patients without ACHD.<sup>7,9</sup> However, in analyses from the United Network of Organ Sharing,<sup>7,8</sup> the Scientific Registry of Transplant Recipients,<sup>9,28</sup> and the Interagency Registry for Mechanically Assisted Circulatory Support,<sup>10,48</sup> patients with ACHD who undergo durable MCS have post-transplant mortality comparable to that of ACHD patients without MCS,<sup>7,8,28</sup> although data on the impact of MCS on waitlist-period mortality are mixed.<sup>7-9</sup> Temporary MCS appears to be well tolerated in selected patients.<sup>7,27</sup> Among heart transplantation candidates, temporary MCS is associated with a decrease in waitlist time, with no increase in waitlist-period or posttransplant mortality in patients with ACHD without temporary MCS.<sup>7</sup>

### 3.7. Genetic Syndromes Screening

**Recommendations for Genetic Syndromes Screening**  
 Referenced studies that support recommendations are summarized in the [Evidence Table](#).

COR	LOE	RECOMMENDATIONS
2a	B-NR	1. For adults with conotruncal defects, screening for 22q11.2 deletion syndrome is reasonable to assess the risk of transmission to offspring and to screen for associated comorbidities. <sup>1,2</sup>
2a	C-EO	2. In adults with congenital heart disease and a family history of congenital heart disease or clinical features associated with a genetic syndrome, referral for genetic evaluation is reasonable to guide management.

#### Synopsis

Although congenital heart disease etiologies are multifactorial, genetic and/or environmental causes can be identified in 20% to 30% of affected patients.<sup>3</sup> The several broad classes of genetic variations associated with congenital heart disease include chromosomal aneuploidy, large chromosomal deletions or duplications, single-gene mutation, and copy-number variation.<sup>4-10</sup> Some genetic syndromes are associated with increased risk for congenital heart disease ([Table 9](#)). Clinicians caring for adults with congenital heart disease should recognize the associated features of common genetic syndromes, because the presence of a genetic syndrome may affect overall health and postoperative outcomes.

Single-center studies have shown that adults with congenital heart disease and heterotaxy have high rates of comorbidities, heart transplantation, and early death.<sup>11</sup> Patients with heterotaxy syndrome (situs abnormalities that result from multiple possible genetic defects) have associated ciliary dysfunction, which predisposes the patient to impaired respiratory clearance.<sup>12-14</sup> Single-center studies have also shown that patients with heterotaxy and ciliary dysfunction have increased respiratory complications postoperatively and required increased use of inhaled beta agonists, which has been shown to improve ciliary function.<sup>13,15</sup> These and other associated features contribute to higher rates of postoperative complications in patients with congenital heart disease and heterotaxy.<sup>11,15</sup>

**TABLE 9 Genetic Syndromes and Their Associations With Congenital Heart Disease**

Syndrome	Genetic Abnormality	Clinical Features	Percentage of Affected Patients With Congenital Heart Disease	Common Cardiac Findings
22q11.2 deletion syndrome <sup>1,2,16-18</sup> (DiGeorge syndrome, velocardiofacial syndrome)	22q11.2 deletion	Facial dysmorphism, palate and speech abnormalities, thymic and parathyroid hypoplasia, hypocalcemia, immunodeficiency, neurodevelopmental and psychiatric disorders	60%-80%	Interrupted aortic arch type B, other aortic arch abnormalities, truncus arteriosus, tetralogy of Fallot, ventricular septal defect/pulmonary atresia
Down syndrome <sup>26,27</sup>	Trisomy 21	Facial dysmorphism, developmental disability, atlantoaxial instability, obstructive sleep apnea, craniofacial abnormalities	40%-50%	Atrial septal defect, ventricular septal defect, atrioventricular septal defect, tetralogy of Fallot
Holt-Oram syndrome <sup>28,29</sup>	<i>TBX5</i>	Upper-limb skeletal abnormalities, conduction abnormalities	75%	Atrial septal defect, ventricular septal defect, valvular disease (mitral valve prolapse, pulmonary stenosis)
Klinefelter syndrome <sup>30</sup>	47,XXY	Tall stature, hypoplastic testes, delayed puberty and developmental disability	50%	Patent ductus arteriosus, atrial septal defect, mitral valve prolapse
Noonan syndrome <sup>31,32</sup>	<i>PTPN11, KRAS, SOS1, RAF1, NRAS, BRAF, MAP2K1</i>	Facial anomalies, webbed neck, chest deformity, lymphatic abnormalities, bleeding abnormalities	80%	Pulmonary stenosis, atrial septal defect, hypertrophic cardiomyopathy, atrioventricular septal defect
Turner syndrome <sup>33-35</sup>	45,X	Short stature, webbed neck, lymphedema, primary amenorrhea	30%	Bicuspid aortic valve, coarctation of the aorta, aortopathies, partial anomalous pulmonary venous connection, atherosclerosis risk
Williams syndrome <sup>36,37</sup>	7q11.23 deletion	"Elfin" facial features, social personality, hearing loss, developmental delay, infantile hypercalcemia	50%-80%	Supravalvar aortic stenosis, branch pulmonary artery stenosis, supravalvar pulmonary stenosis, coronary ostial stenosis, QTc prolongation, mid-aortic narrowing syndrome
Alagille syndrome <sup>38,39</sup>	<i>JAG1</i>	Facial dysmorphism, hepatic dysfunction (chronic cholestasis, elevated liver enzymes, biliary atresia, hypercholesterolemia, or liver failure), neurovascular accidents, renal anomalies (renal artery stenosis, hypertension, renal tubular acidosis, uteropelvic obstruction, small, hyperechoic kidneys)	70%-75%	Two-thirds with peripheral or branch pulmonary artery stenosis or other arterial narrowing (coarctation of the aorta, renal artery stenosis, middle cerebral artery, Moyamoya); also can have tetralogy of Fallot, aortic stenosis, septal defects, mid-aortic narrowing syndrome
Heterotaxy syndrome <sup>12-14</sup>	<i>ZIC3, SHROOM3, GRK5, ANKS3, NODAL, CFC1, LEFTY2, GDF1, SMAD2, ACVR2B</i>	Situs abnormalities, ciliary dysfunction, functional asplenia, conduction abnormalities, biliary atresia	50%-95%	Atrioventricular septal defect (balanced, unbalanced), malposed great vessels, interrupted inferior vena cava, bilateral superior vena cava, atrial isomerism

Modified with permission from Stout et al.<sup>40</sup> Copyright 2018 American Heart Association, Inc. and American College of Cardiology Foundation.

### Recommendation-Specific Supportive Text

1. Conotruncal anomalies are malformations of the infundibulum (outflow tract) and great arteries that have a high rate of associated genetic diagnoses, with 22q11.2 deletion syndrome and trisomy 21 as the most common associated syndromes.<sup>19,20</sup> Given the associated comorbidities and the autosomal dominant pattern, genetic testing for 22q11.2 deletion syndrome in adults with conotruncal abnormalities can aid in assessing risk for recurrence, identifying noncardiac comorbidities, and determining preoperative risk.<sup>20-22</sup> Approximately 60% to 80% of people with 22q11.2 deletion syndrome have congenital heart disease; 70% of that subset have a conotruncal

defect.<sup>16-18</sup> Studies have shown that 22q11.2 deletion syndrome may not be phenotypically apparent in adults with congenital heart disease.<sup>23</sup> Identifying patients can help guide management of associated cardiac and noncardiac conditions. Given that other genetic diagnoses are also associated with conotruncal defects and that genetic testing for 22q11.2 deletion syndrome may not be readily accessible to all practitioners, genetic referral for evaluation and screening is reasonable to consider.<sup>24,25</sup>

2. Most adults with congenital heart disease did not have access during childhood to currently available genetic evaluation and testing. Some individuals may decline genetic evaluation because of personal preference, but evaluation nevertheless offers adults with congenital

heart disease several potential benefits, including management guidance, information on long-term prognosis, and estimates of recurrence risk in offspring and family members.<sup>3,19-21</sup> A genetics provider can offer important preconception counseling that may influence family planning as people learn the potential risks and mechanism of disease.<sup>22</sup> Cardiologists within the United States have also reported fewer barriers to referring patients for genetics evaluation than to ordering appropriate genetic testing.<sup>25</sup> Many syndromes are also associated with cardiac and noncardiac comorbidities that can affect surgical and procedural outcomes (Table 9). For example, patients with Noonan syndrome can have increased bleeding risk related to platelet dysfunction.<sup>23</sup> Patients with Williams syndrome have a higher risk for QTc prolongation with anesthesia, thought to be responsible for increased risk for sudden death.<sup>24,25</sup> Identifying which patients with heterotaxy have respiratory ciliary dysfunction would, in consultation with pulmonology, facilitate use of preoperative protocols to improve respiratory clearance and, potentially, postoperative recovery. Referral for genetic counseling and evaluation should therefore be considered, especially for people with a family history of congenital heart disease or clinical features associated with a genetic syndrome.<sup>19-21</sup>

**3.8. Reproductive Health, Pregnancy, and Contraception**

**Recommendations for Reproductive Health, Pregnancy, and Contraception**  
 Referenced studies that support recommendations are summarized in the Evidence Table.

COR	LOE	RECOMMENDATIONS
1	B-NR	1. In adults with congenital heart disease of childbearing age, counseling on contraceptive options is recommended to inform pregnancy-related shared decision-making. <sup>1-4</sup>
1	B-NR	2. Adults with congenital heart disease interested in pregnancy should receive preconception counseling, in collaboration with an ACHD cardiologist, about the maternal cardiac, obstetric, and fetal risks associated with pregnancy and the potential long-term risks to the pregnant individual. <sup>1,5</sup>

*continued in the next column*

Continued		
COR	LOE	RECOMMENDATIONS
1	C-LD	3. Screening fetal echocardiography is indicated to detect congenital heart disease if either parent has ACHD to optimize delivery planning and access to care. <sup>6,7</sup>
1	C-LD	4. In pregnant patients with ACHD AP classifications IB-D, IIA-D, and IIIA-D, an individualized care plan, including mode of delivery, need for cardiac monitoring, and anesthetic support, should be documented in the medical record and communicated to the patient and care team, to reduce maternal risks for morbidity and mortality. <sup>8</sup>
1	C-LD	5. In pregnant patients with ACHD AP classifications IB-D, IIA-D, and IIIA-D, management should be provided by, or in collaboration with, a cardio-obstetrics team with expertise in ACHD and maternal-fetal medicine, to improve clinical outcomes. <sup>9</sup>
1	C-LD	6. Patients with ACHD who have high risk for maternal morbidity and mortality should be counseled to avoid pregnancy and given guidance on effective contraception to improve outcomes. <sup>3</sup>
1	C-LD	7. For pregnant patients with ACHD who have high risk for morbidity and mortality, the option of terminating pregnancy should be discussed to reduce that risk. <sup>10,11</sup>
2a	C-LD	8. In patients with ACHD who are of childbearing age, referral to a genetic counselor for preconception planning is reasonable to facilitate understanding of the risks for congenital heart disease in their offspring. <sup>12,13</sup>
2a	C-EO	9. For patients with ACHD who are considering assisted reproductive technology, discussions involving an ACHD cardiologist can be beneficial to increase patients' knowledge about their options and the associated risks.

*Continued on the next page*

Continued		
COR	LOE	RECOMMENDATIONS
3: No Benefit	C-LD	10. Routine cesarean delivery has no benefit and may cause harm in pregnant patients with ACHD in the absence of an obstetric indication or high-risk cardiac condition. <sup>14</sup>
3: Harm	B-NR	11. In patients with ACHD who are at high risk for thromboembolic events, contraceptive agents that contain estrogen are potentially harmful. <sup>15</sup>

### Synopsis

Although adults with congenital heart disease are at risk for adverse maternal cardiac, obstetric, and fetal complications, many have received either no or inconsistent guidance about pregnancy-related risks.<sup>2,16</sup> Several congenital heart disease conditions (Table 10) are associated with significantly high risks, meriting condition-specific counseling in a shared decision-making process, as well as use of relevant risk scores that aid in risk-stratifying patients with cardiac disease as they consider pregnancy.<sup>1,5</sup> (Consult pertinent guidelines for information about peripartum cardiomyopathy, spontaneous coronary artery dissection, and anti-coagulation for mechanical heart valves, which are not addressed here.<sup>17-19</sup>)

The most common cardiac complications of pregnancy include arrhythmia and heart failure, and fatal events may occur. In a study of 1,315 pregnancies in women with heart disease, serious adverse maternal cardiac events occurred in 3.6%, of which 49% were determined to be preventable using a specific adjudication process.<sup>20</sup> A multidisciplinary cardio-obstetrics team should care for most patients with ACHD during pregnancy, with continued postpartum surveillance.<sup>9,21</sup> The long-term hemodynamic effects of pregnancy on individuals with ACHD have not been established.

The potential side effects of contraceptive agents should be balanced against the risks from pregnancy. Family planning counseling should include information on available methods of contraception and on the potential for occurrence of congenital heart disease in offspring. No randomized controlled trials have studied the safety of select contraceptive methods in patients with ACHD.

**TABLE 10** Congenital Heart Conditions Considered Significantly High Risk for Maternal Complications in Pregnancy\*

#### Congenital Heart Lesions

Severe, symptomatic, left-sided obstructive lesions (mitral stenosis, subaortic and aortic stenosis)
Severe native coarctation or reoarctation
Cyanotic congenital heart disease or Eisenmenger syndrome
Fontan physiology
Systemic right ventricle with at least moderately depressed ventricular function
<b>Other Factors/Conditions</b>
Advanced New York Heart Association functional class (III or IV)
Prior adverse cardiac event during pregnancy
Pulmonary arterial hypertension
Significantly decreased systemic ventricular dysfunction (ejection fraction <30%)
Aortopathy (diameter >5 cm or associated with connective tissue disorders)
Mechanical heart valves
Refractory ventricular arrhythmias

Adapted from Regitz-Zagrosek et al.<sup>39</sup> by permission of Oxford University Press. Copyright 2018 The European Society of Cardiology and The European Society of Hypertension.

\*Information adapted from the modified World Health Organization classification system.

#### Recommendation-Specific Supportive Text

1. Pregnancy is associated with risks to both mother and fetus. Patients with congenital heart disease should be counseled about potential risks according to the individual's anatomy and physiology. The patient-specific benefits and risks of each contraceptive method should be discussed, including anticipated failure rates and potential side effects of each agent.<sup>4,22-24</sup>
2. Family planning counseling should be based on the underlying anatomy, physiology, and functional class of each patient with ACHD of childbearing age. Risk scores, such as the modified World Health Organization classification system and the CARPREG 2 score, may be used to estimate maternal cardiac risk.<sup>1,5,25</sup> Counseling should include potential cardiac and obstetric risks in the antenatal, labor and delivery, and postpartum periods; potential long-term risks<sup>26</sup>; and, crucially, medication adjustments to avoid teratogenic agents.<sup>27</sup> Discussions with an ACHD cardiologist should include potential risks for congenital heart disease in the patient's offspring.<sup>28</sup>
3. Biological offspring of parents with congenital heart disease have an increased risk for congenital heart disease. Fetal echocardiography, performed in the

second trimester when possible, is helpful in diagnosing fetal congenital heart defects, which can aid in choosing a course of action at the time of delivery.<sup>29</sup>

4. The care plan should include specific potential complications according to each patient’s anatomy, physiology, and functional class. Documentation should lucidly inform all providers of potential management strategies if adverse maternal or fetal events occur, the expected plan for labor and delivery, and the need for maternal cardiac monitoring.<sup>30</sup>
5. Many patients with ACHD tolerate the hemodynamic changes of pregnancy without major adverse events; however, the large shifts in volume, cardiac output, and systemic vascular resistance may result in hemodynamic decompensation. Management should involve a dedicated team of clinicians with expertise in ACHD, maternal-fetal medicine, and anesthesiology to anticipate and mitigate potential cardiac and obstetric adverse outcomes.<sup>9</sup> Specific patients may need additional team members, such as cardiac interventionalists, cardiac surgeons, neonatologists, and others.<sup>31</sup>
6. Patients with ACHD and specific conditions—including, but not limited to, PAH; Eisenmenger syndrome; severe ventricular dysfunction; symptomatic, severe left-sided obstructive lesions; and physiological class D conditions—are at high risk for maternal morbidity and mortality (Table 10). Those patients should be counseled about avoiding pregnancy with reliable contraceptive or sterilization methods.
7. Maternal mortality rates have risen during the past several decades. In pregnant patients with high-risk congenital heart disease lesions, the risks for serious, sometimes fatal, maternal cardiac events may be high. Therefore, shared decision-making discussions about those risks should include the option to terminate pregnancy, in addition to information about the procedural risks of pregnancy termination, accompanied by appropriate psychosocial support during the decision-making process and thereafter.<sup>32</sup>
8. Preconception counseling about the risk for congenital heart disease in offspring should inform shared decision-making about pregnancy planning and other reproductive health options.<sup>33</sup> Such counseling includes referral to genetic counselors, with potential for genetic testing and preimplantation genetic testing, as appropriate.<sup>34</sup>
9. For patients with ACHD who are unable to conceive within 1 year of unprotected intercourse and in those with multiple miscarriages, it is reasonable to offer referral to a specialist with expertise in causes of infertility and potential assisted reproductive

therapy, including ovulation induction, intrauterine insemination, and in vitro fertilization.<sup>35</sup> Similarly, assisted reproductive technologies may be an option for patients in whom pregnancy is high-risk, and consultation with a reproductive endocrinologist can be considered. Single-embryo transfer may be preferable given the increased physiological demands of multiple gestation.<sup>36</sup>

10. In pregnant patients with ACHD, the mode of delivery should be determined by obstetric indications (eg, fetal distress or presentation in labor while fully anticoagulated), except in specific patients such as high-risk cardiac conditions (eg, high-risk aortopathies) as determined by a multidisciplinary team. Cesarean delivery is associated with longer hospitalizations, and with increased risk for bleeding and infectious complications, and does not improve maternal cardiac outcomes, compared with planned vaginal delivery.<sup>14,37</sup> Given that labor beyond 24 hours is associated with adverse cardiac outcomes in patients with ACHD, an assisted delivery should be considered at that time.<sup>38</sup>
11. Estrogen-containing contraceptive agents should be avoided in patients with ACHD who are at increased risk for thrombotic events, including those with cyanosis, mechanical heart valves, PAH, Fontan physiology, or prior thrombotic events. Data are insufficient on the safety of estrogen use in patients with ACHD who have elevated risk for thrombosis and are receiving anticoagulation therapy.<sup>15,23</sup>

### 3.9. Ionizing Radiation Exposure

**Recommendation for Ionizing Radiation Exposure**  
 Referenced studies that support recommendation are summarized in the Evidence Table.

COR	LOE	RECOMMENDATION
1	B-NR	1. In adults with congenital heart disease, processes to limit radiation exposure during imaging and cardiovascular procedures are recommended to reduce the lifetime risk for cancer. <sup>1,2</sup>

#### Synopsis

Low-dose ionizing radiation is a known carcinogen. Throughout their lifetimes, adults with congenital heart disease may have numerous exposures to low-dose ionizing radiation from cardiac testing, including cardiac catheterizations, invasive electrophysiology procedures, CT scans, nuclear perfusion scans, and chest x-rays. Reducing those exposures is warranted to mitigate

the risk for malignancy. Whenever clinically appropriate, studies should be chosen that do not involve ionizing radiation.

### Recommendation-Specific Supportive Text

1. Greater exposure to low-dose ionizing radiation from cardiac procedures has been associated with elevated cancer risk, with a possible dose-related response.<sup>1,3</sup> Select cohorts of adults with congenital heart disease have greater exposure and, consequently, higher estimated cancer risk.<sup>4</sup> Radiation exposure should be as low as reasonably achievable without sacrificing quality of care. Many centers have developed initiatives to reduce radiation exposure, including selection of tests that use minimal to no radiation, use of updated imaging technologies and fluoroscopy protocols during catheterization procedures and CT studies, education for health care professionals about radiation-dose reduction, and dose optimization that is tailored to specific clinical indications.<sup>5,6</sup>

## 3.10. Exercise Testing and Sports

### 3.10.1. Exercise Testing

**Recommendations for Exercise Testing**  
Referenced studies that support recommendations are summarized in the [Evidence Table](#).

COR	LOE	RECOMMENDATIONS
2a	B-NR	1. In patients with ACHD, CPET can be useful for establishing a baseline functional assessment, guiding clinical care, stratifying risk for major adverse cardiovascular events, and ongoing surveillance. <sup>1-4</sup>
2a	B-NR	2. In patients with ACHD and established PAH, or in those unable to perform CPET yielding reliable diagnostic information, a 6-minute walk test can be useful to objectively assess symptom severity, functional capacity, and response to therapy. <sup>5,6</sup>

### Synopsis

Reduced exercise capacity and functional impairment are common in patients with ACHD and have been associated with hospitalizations and increased mortality.<sup>7,8</sup> Unlike patients with acquired heart disease, those with ACHD experience lifelong adaptation to a chronic disorder. As such, they often underreport functional

limitations and overestimate their physical capabilities.<sup>8,9</sup> A decline in physical capacity can occur progressively over the course of several years, with imperceptible changes in symptom status.<sup>10-12</sup> Although New York Heart Association functional class and objective measures of functional capacity have a strong inverse relationship in patients with ACHD, measured exercise capacity varies widely within each New York Heart Association functional class stratum.<sup>13</sup> A more objective, reliable tool than symptom assessment alone is needed for accurately evaluating and regularly monitoring functional capacity in patients with ACHD.<sup>14,15</sup>

### Recommendation-Specific Supportive Text

1. CPET, an objective means of quantifying functional capacity, is reproducible and amenable to serial testing.<sup>16</sup> In patients with ACHD who do not have contraindications to CPET (eg, acute illness or other medical condition deemed by the clinician to render the test unsafe to perform), the test can provide a wealth of information on cardiovascular, respiratory, and muscular systems.<sup>3,10,13,17-22</sup> Several studies suggest that CPET carries prognostic value for various ACHD conditions, including postoperative outcomes, mortality, heart failure hospitalizations, and other major adverse cardiovascular events.<sup>1,2,4,11,23-26</sup> The findings underscore the value of CPET as a comprehensive tool for both initial assessment and longitudinal follow-up in patients with ACHD, facilitating preventive and therapeutic decision-making. The data also inform individualized recommendations regarding exercise, sports participation, and pregnancy risk. Exercise testing can be used to guide the timing of hemodynamic or surgical interventions and reinterventions.<sup>14,15,27</sup> Given its established prognostic significance and clinical utility, serial exercise testing should be systematically integrated into long-term follow-up protocols for patients with ACHD.

2. Among patients with ACHD and severe functional impairment unable to perform a CPET yielding reliable diagnostic information, a 6-minute walk test provides a reasonable, albeit more limited, assessment of functional capacity. A 6-minute walk test is also an informative tool to assess symptom severity, evaluate functional capacity, and monitor response to therapy in patients with ACHD and PAH.<sup>28,29</sup> Incorporating an intensity rating of breathlessness (eg, from the Borg scale<sup>30</sup>) can semiquantitatively characterize symptom severity. A 6-minute walk test offers important prognostic information beyond that of a standard history alone.<sup>5,6,31</sup>

3.10.2. Physical Activity, Exercise, and Sports Participation

**Recommendations for Physical Activity, Exercise, and Sports Participation**  
 Referenced studies that support recommendations are summarized in the Evidence Table.

COR	LOE	RECOMMENDATIONS
1	B-R	1. Patients with ACHD should have their activity levels assessed at regular intervals to receive counseling about the types and intensity of exercise appropriate to their clinical status. <sup>1-4</sup>
2a	B-R	2. In patients with ACHD, exercise training and cardiac rehabilitation can be useful to increase exercise capacity. <sup>3,5</sup>
2a	C-LD	3. In patients with ACHD, CPET can be useful to guide physical activity recommendations. <sup>4,6-8</sup>
2a	C-EO	4. In patients with ACHD, participation in competitive sports is reasonable following a comprehensive evaluation by an ACHD specialist that incorporates functional status and individualized assessment of risks and benefits.

**Synopsis**

Guidelines for physical activity in patients with ACHD have shifted away from a historical focus on restriction to emphasizing the promotion of activity and sports participation, given the multitude of increasingly documented health benefits, including improved functional capacity, vascular and autonomic function, and patient-reported outcomes.<sup>5,8,9</sup> Most patients with ACHD can safely engage in regular, moderate physical activity and should be encouraged to engage in recreational exercise or appropriate physical activity. Nevertheless, a few conditions—such as systemic ventricular systolic dysfunction, systemic ventricular outflow tract obstruction, hemodynamically significant arrhythmias, or aortic dilation—warrant more cautious recommendations.<sup>10-12</sup>

**Recommendation-Specific Supportive Text**

1. Physical activity is widely recognized as beneficial to physical and mental health. Studies addressing the benefits and safety of exercise programs in patients

with ACHD have included heterogeneous populations and more-specific subgroups, such as those with TOF, a systemic right ventricle, Fontan palliation, and unrepaired cyanotic heart disease.<sup>1-9,13-21</sup> The type and intensity of exercise appropriate to the clinical status of a patient with ACHD could range from mild (<3 metabolic equivalents; 40%-50% of the predicted maximum heart rate achieved) or moderate (3-6 metabolic equivalents; 50%-70% of the predicted maximum heart rate achieved) recreational exercises for leisure, to competitive sports that involve systematic training.<sup>22</sup>

2. In patients with ACHD, regular exercise and cardiac rehabilitation (prescribed after a cardiac procedure, for chronic heart failure, or for reduced exercise tolerance) have been consistently shown to improve exercise capacity, with some studies documenting benefits on other parameters such as heart failure symptoms, vascular function, NT-proBNP and fibrinogen levels, cardiac autonomic function, quality of life, and self-reported health status.<sup>4-9,14-16,18</sup> However, adherence to rehabilitation programs may be problematic, thereby attenuating long-term benefits.<sup>2,4,23</sup>

3. Most clinical trials that have documented beneficial effects of exercise in patients with ACHD have customized training programs tailored to parameters derived from CPET (eg, work rate, exercise time at constant work rate, and peak oxygen uptake).<sup>4,6-9,15</sup> Not all ACHD centers may have the resources to conduct CPET, the preferred evaluation method. When CPET is not feasible, other exercise tests that use established treadmill or bicycle ergometer protocols are considered acceptable alternatives for assessing exercise capacity, although they may not provide all of the insights that CPET offers.

4. Recommendations for competitive sports participation in patients with ACHD remain consensus-based, given the paucity of scientific data. A comprehensive, tailored evaluation is recommended for patients contemplating competitive sports, which may include formal exercise testing, rhythm monitoring, and imaging studies.<sup>22</sup> Guidelines that comprehensively address this issue emphasize the importance of customizing the assessment to each patient's distinct condition, engaging in shared decision-making, employing a multidisciplinary care strategy, and regular monitoring.<sup>22,24</sup> The objective is to allow for participation in competitive sports within reasonable boundaries of safety.

## 4. SPECIFIC CONDITIONS

### 4.1. Shunt Lesions

Congenital shunt lesions allow communication between the systemic and pulmonary circulation. Isolated shunt lesions discussed in this guideline include ASD, VSD, atrioventricular septal defect (AVSD), patent ductus arteriosus (PDA), and anomalous pulmonary venous return. Most of those lesions permit left-to-right flow and cause volume loading of the downstream cardiac chambers and vascular beds.

Shunt magnitude depends on the size of the defect, its location, and the cardiac physiology. A left-to-right shunt is considered hemodynamically significant when the pulmonary-to-systemic blood flow ratio (Qp:Qs) is  $\geq 1.5$ , with associated chamber enlargement. Right-to-left shunts are less common and are characterized by resting cyanosis. Right-to-left shunts can be caused by shunt reversal from severe pulmonary vascular disease (see Section 4.4.6, “Eisenmenger Syndrome”), obligatory mixing in patients with complex congenital heart disease, or local streaming phenomena. Exercise-induced hypoxemia in the presence of an isolated shunt suggests bidirectional flow.

#### PAH and Shunt Closure

This section and Table 11 refer to the care of ACHD patients with shunt lesions and PAH and not to other

forms of ACHD with PAH. PAH is defined by a mean pulmonary artery (PA) pressure  $>20$  mm Hg at rest, PVR  $>2$  Wood units, and pulmonary arterial wedge pressure  $\leq 15$  mm Hg.<sup>1</sup> Patients with congenital shunt lesions and PAH are categorized into 4 subtypes, as shown in Table 11, and pulmonary hypertension specialist care is associated with improved morbidity and mortality for patients with PAH.<sup>2</sup> Medical therapy<sup>1</sup> for patients with congenital shunt lesions and PAH may be initiated as monotherapy or combination therapy. Table 11 summarizes general information on patient characteristics and the currently available evidence regarding strategies for risk assessment and PAH therapies studied in each subtype.

Whether to close a left-to-right shunt in patients with PAH depends on several considerations that include shunt magnitude and a continuum of pulmonary vascular disease severity, with or without shunt reversal. When severe, irreversible pulmonary vascular disease with a right-to-left shunt has developed, perioperative risk is high; closure leads to catastrophic physiology, so it is contraindicated.

Defect closure may be considered in patients with less than systemic PVR, when PAH therapy leads to a sufficient reduction in that resistance (the “treat-and-repair” approach). Partial defect closure (“fenestrated closure”) may also be considered in such cases. Data on treat-and-

**TABLE 11** Isolated Shunt Lesions and Pulmonary Arterial Hypertension

PAH-ACHD Subtype	Patient Characteristics		Evidence for Use of Risk Assessment Factors/Tools	Evidence for Use of PAH-Specific Therapy
	Resting hypoxemia/cyanosis	Typical defect size		
A. Eisenmenger syndrome	Usually	Large	Patient age, pretricuspid shunt, resting oxygen saturation, loss of sinus rhythm, pericardial effusion, <sup>7</sup> BNP, <sup>8</sup> C-reactive protein, <sup>9</sup> 6MWD, <sup>7,10</sup> echocardiography, <sup>11</sup> renal dysfunction, or other clinical stratification tools. <sup>*12-14</sup>	Endothelin-receptor antagonists, <sup>15-17</sup> phosphodiesterase-5 inhibitors, <sup>18</sup> prostacyclin analogs <sup>19-23†</sup>
B. Prevalent systemic to pulmonary shunts (left-to-right shunts with elevated PVR, yet not meeting criteria for Eisenmenger syndrome)	No	Moderate to large	Review using the 3-strata risk-prediction model for newly diagnosed patients, the 4-strata risk-prediction model for patients with established PAH, <sup>1</sup> and/or any of the Eisenmenger syndrome tools. <sup>†1-7</sup>	No direct studies on this isolated cohort; treatment has typically followed recommendations for idiopathic PAH <sup>1</sup>
C. Coincidental defects with elevated PVR	Rare	Small	Review using the 3-strata risk-prediction model for newly diagnosed patients, the 4-strata risk-prediction model for patients with established PAH, <sup>1</sup> and/or any of the Eisenmenger syndrome tools. <sup>†1-7</sup>	No direct studies on this isolated cohort; treatment has typically followed recommendations for idiopathic PAH <sup>1</sup>
D. Postcorrection defects with elevated PVR	Rare (with small residual shunts and severe pulmonary vascular disease)	Corrected	Review using the 3-strata risk-prediction model for newly diagnosed patients, the 4-strata risk-prediction model for patients with established PAH, <sup>1</sup> and/or any of the Eisenmenger syndrome tools. <sup>†1-7</sup>	Phosphodiesterase-5 inhibitors, <sup>24</sup> endothelin receptor antagonists, <sup>25-27</sup> oral prostacyclin receptor analog, <sup>28</sup> activin signaling inhibitors <sup>§29</sup>

\*No validated score available.

†See Section 4.4.6 for details on the order of PAH-directed drug initiation.

‡For patients in groups B, C, and D, the 3- and 4-strata models have been applied, and evidence for use has included enrollment of patients in this category; however, validation for this specific population in isolation from other forms of PAH has not been directly studied.

§Trials that included patients with PAH after congenital defect correction.

6MWD indicates 6-minute walk distance; ACHD, adult congenital heart disease; BNP, B-type natriuretic peptide; N/A, not applicable; PAH, pulmonary arterial hypertension; and PVR, pulmonary vascular resistance.

repair are most robust in pretricuspid shunts, for which a drop in PVR to <5 Wood units after PAH therapy appears to be favorable.<sup>3-6</sup> The treat-and-repair approach requires both expert ACHD and pulmonary hypertension care, including postclosure hemodynamic assessment and, typically, long-term PAH therapies. Further discussion and recommendations regarding management are discussed in the individual lesion sections.

4.1.1. Atrial Septal Defect

**Recommendations for Atrial Septal Defect**  
 Referenced studies that support recommendations are summarized in the Evidence Table.

COR	LOE	RECOMMENDATIONS
<b>Diagnostic</b>		
1	B-NR	1. In adults with an unrepaired ASD, CMR imaging, transesophageal echocardiography, or cardiac CT is recommended to define defect size, morphology, rim anatomy, and pulmonary venous connections. <sup>1-3</sup>
1	B-NR	2. Adults with an unrepaired ASD and PAH should undergo risk assessment and management in consultation with pulmonary hypertension specialists to improve outcomes. <sup>4</sup>
1	C-EO	3. Adults with an unrepaired ASD should be assessed for the presence of PAH to guide medical therapy and determine suitability for repair.
2b	C-LD	4. In adults with an unrepaired ASD, balloon test occlusion before closure may be reasonable to assess hemodynamic changes. <sup>5,6</sup>
<b>Therapeutic</b>		
1	B-R	5. In adults with an unrepaired ASD, significant left-to-right shunt (Qp:Qs ≥1.5) and right ventricular (RV) dilation, in the absence of PAH (PVR ≤2 Wood units) or significant LV disease,* ASD closure is recommended to improve functional class and clinical outcomes. <sup>7-9</sup>

*continued in the next column*

Continued		
COR	LOE	RECOMMENDATIONS
1	B-NR	6. In adults with an isolated unrepaired secundum ASD, transcatheter closure is usually preferred to surgical repair to reduce length of stay and recovery time. <sup>10</sup>
1	C-EO	7. In adults with an unrepaired ASD and evidence of (or strong suspicion for) paradoxical embolism, ASD closure is recommended to prevent recurrent embolism.
2a	B-R	8. In adults with an unrepaired ASD, significant left-to-right shunt (Qp:Qs ≥1.5) and RV dilation, with a PVR >2 to <5 Wood units, and without significant LV disease,* ASD closure is reasonable to improve functional status. <sup>11-14</sup>
2a	B-NR	9. In adults with an unrepaired ASD, significant left-to-right shunt (Qp:Qs ≥1.5), RV dilation, PAH (PVR 5 to 8 Wood units), and without significant LV disease, closure can be beneficial if PVR <5 Wood units can be achieved with targeted PAH therapy, to improve medium-term functional status. <sup>11-13</sup>
2b	B-NR	10. In adults with an unrepaired ASD and PAH for whom closure is indicated, fenestrated repair can be considered to improve functional class and clinical outcomes. <sup>14,15</sup>
2b	B-NR	11. In adults with unrepaired superior sinus venosus atrial septal defect (SVASD), transcatheter closure (when technically feasible) may be a reasonable alternative to surgery to reduce operative morbidity. <sup>16-19</sup>
2b	B-NR	12. In adults with an unrepaired ASD, significant left-to-right shunt (Qp:Qs ≥1.5), and PAH with PVR of 5 to 8 Wood units while receiving targeted PAH therapy, the usefulness of fenestrated ASD closure to improve functional class and clinical outcomes is uncertain. <sup>11,13-15</sup>

*Continued on the next page*

Continued		
COR	LOE	RECOMMENDATIONS
3: Harm	C-LD	<b>13. In adults with an unrepaired ASD and Eisenmenger physiology, ASD closure should not be performed to avoid increasing morbidity and mortality.<sup>20,21</sup></b>

\*Significant LV disease: any condition resulting in chronically elevated left atrial pressure  $\geq 15$  mm Hg.

### Synopsis

The physiology of an ASD is affected by the presence of  $\geq 1$  concomitant defects. Given that accompanying lesions can lead to unique physiological heterogeneity, this section focuses on isolated ASDs.

The commonly known subtypes of isolated ASDs are based on location: secundum (80% of cases); primum (15%), also known as partial AVSD (see Section 4.1.3, “Atrioventricular Septal Defect”); sinus venosus, either superior (5%) or inferior (<1%); and unroofed coronary sinus (1%). The most commonly associated lesion is partial anomalous pulmonary venous return. Left-to-right shunting may result in enlargement of the right heart chambers and RV dysfunction. A minority of affected patients may develop PAH, right-to-left shunting, and/or paradoxical embolism. Atrial arrhythmia is observed with increased frequency in patients with an ASD closed later in life. The mainstay of therapy for patients with clinical or hemodynamic consequences of the ASD remains percutaneous or surgical closure, in some cases with a fenestration or flap, to decompress (either right- or left-

sided) high pressure. See Table 12 for suggested routine testing and follow-up intervals for patients with ASD.

### Recommendation-Specific Supportive Text

1. Transthoracic echocardiography has limited ability to anatomically define all pulmonary venous connections, or the atrial septum in totality, in adults. Transesophageal echocardiography has been shown to optimally visualize the atrial septum in its entirety, as well as some anomalous pulmonary venous connections (APVCs), in particular those involved with sinus venosus defects. However, for more remote APVCs, cross-sectional imaging is critical.<sup>1-3</sup> Either CMR imaging or cardiac CT may be used, but CMR avoids radiation and offers the additional benefit of quantifying the degree of shunting. Although advanced imaging is useful in the initial diagnosis and assessment of ASDs, there is no evidence-based recommendation for repeat imaging at specific follow-up intervals. However, some patients may occasionally require follow-up advanced imaging for specific reasons (eg, when device erosion is suspected).
2. Adults with an ASD confirmed to have precapillary PAH (mean PA pressure  $>20$  mm Hg, PVR  $>2$  Wood units, pulmonary capillary wedge pressure  $\leq 15$  mm Hg) are classified as having group 1 PAH, which should be managed according to current PAH guidelines.<sup>22,23</sup> Management includes appropriate risk assessment and stratification, according to the 3-strata model, and consideration of PAH-directed therapy based on individual data and clinical presentation. Patients with PAH who are followed in pulmonary hypertension specialty care centers have been shown to have fewer hospitalizations and lower mortality; therefore, if PAH management does not fall within the ACHD team’s expertise, collaborative pulmonary hypertension specialty care should be sought, according to designations by the Pulmonary Hypertension Association.<sup>4</sup>
3. In adults with an ASD, if PAH develops, it may manifest clinically with, for example, evidence of functional decline, right heart dysfunction, elevation of biomarkers (eg, B-type natriuretic peptide [BNP]/NT-proBNP), and/or imaging evidence of elevated right heart pressure. However, some adults with ASD and PAH may have no signs or symptoms of PAH at rest, despite the presence of occult disease. Therefore, all adults with an unrepaired ASD must be evaluated for

**TABLE 12** Atrial Septal Defect: Routine Follow-Up and Testing Intervals

Type of Follow-Up or Testing	Physiological Stage A* (mo)	Physiological Stage B* (mo)	Physiological Stage C* (mo)	Physiological Stage D* (mo)
Outpatient ACHD cardiologist	36-60	12-24	6-12	3-6
Electrocardiogram	36-60	12-24	12	12
Transthoracic echocardiogram	36-60	12-24	12	12

For recommendations about CMR imaging intervals, see Section 4.1.1 supportive text for recommendation #1. Modified with permission from Stout et al.<sup>30</sup> Copyright 2018 American Heart Association, Inc. and American College of Cardiology Foundation.

\*See Section 2.2 for details on the ACHD anatomic and physiological classification system.

ACHD indicates adult congenital heart disease; and CMR, cardiovascular magnetic resonance.

the presence of PAH, as some may exhibit findings only with specific interrogation, such as desaturation with exercise (see **Table 13**). All patients should undergo a detailed history and physical examination, exercise testing, electrocardiogram, and transthoracic echocardiography to rule out PAH. Patients with suspected PAH may also require lung imaging, biomarker analysis, and invasive hemodynamic testing. For proven PAH, PAH-directed medical therapy is indicated, and in cases with significantly elevated PVR ( $\geq 5$  Wood units), regression of PVR to  $< 5$  Wood units may make ASD closure safe to consider.<sup>22</sup> Notably, if a treat-to-close strategy is selected, long-term PAH medical therapy may still be required, necessitating ongoing surveillance and management.

4. In adults with suspected significant LV diastolic dysfunction, ASD closure may be contraindicated because it removes the necessary egress for high left atrial pressure. However, fenestrated patch closure may be considered. To identify patients at highest risk from ASD closure, balloon test occlusion has been considered, but retrospective analysis has shown that balloon test occlusion does not offer additional risk-stratification information compared with a resting LV end-diastolic pressure cutoff of  $< 15$  mm Hg.<sup>6</sup> In a more recent analysis, balloon test occlusion consistently overestimated pulmonary capillary wedge pressure, compared with hemodynamic changes after ASD closure, making balloon test occlusion testing likely to be ineffective in identifying patients with LV dysfunction at highest risk from ASD closure.<sup>5</sup>
5. The long-standing presence of an unrepaired moderate to large ASD may result in right heart over-circulation, characterized by right-sided chamber enlargement and a Qp:Qs  $\geq 1.5$ . Regardless of symptoms, closure has been shown to improve functional capacity<sup>7-9</sup> and reduce morbidity and mortality, particularly in patients aged  $\geq 40$  years.<sup>7,8</sup> However, to ensure the safety of ASD closure, PAH and significant LV dysfunction should be ruled out, as described in the previous text. In patients with significantly elevated left atrial pressure, the ASD provides an egress to alleviate that pressure, and closure without fenestration may worsen symptoms and reduce functional capacity. In patients with atrial arrhythmias, an electrophysiology study prior to ASD closure is often performed. In patients with moderate or more tricuspid regurgitation, valve repair may need to be

**TABLE 13** Assessment for Pulmonary Arterial Hypertension in Adults With Congenital Heart Disease

Assessment Type	Findings
Clinical history, examination	<ul style="list-style-type: none"> <li>■ Reduced functional capacity</li> <li>■ Symptoms:                             <ul style="list-style-type: none"> <li>■ Functional: dyspnea, fatigue</li> <li>■ Right heart failure: congestion, abdominal distention, early satiety</li> </ul> </li> <li>■ History of near-syncope</li> <li>■ Desaturation at rest</li> <li>■ Cyanosis</li> <li>■ Clubbing</li> <li>■ Accentuated S2 heart sound</li> <li>■ Jugular venous distention, distended abdomen, peripheral edema</li> </ul>
Exercise capacity	<ul style="list-style-type: none"> <li>■ Reduced 6-minute walk distance</li> <li>■ Possibly reduced resting or exercising oxygen saturation</li> <li>■ Abnormal lung function, at rest and during exercise</li> </ul>
Imaging	<ul style="list-style-type: none"> <li>■ Electrocardiogram: right ventricular enlargement</li> <li>■ Transthoracic echocardiography: RVE, flattened IVS, RAE, peak TR jet <math>&gt; 2.9</math> m/s, RVOT acceleration time <math>&lt; 105</math> ms, TAPSE <math>&lt; 18</math> mm</li> </ul>
Biomarkers	<ul style="list-style-type: none"> <li>■ Elevated BNP or NT-proBNP</li> </ul>
Hemodynamics	<ul style="list-style-type: none"> <li>■ mPAP <math>&gt; 20</math> mm Hg and</li> <li>■ PVR <math>&gt; 2</math> Wood units and</li> <li>■ PCWP <math>\leq 15</math> mm Hg</li> </ul>

BNP indicates B-type natriuretic peptide; CT, computed tomography; IVS, interventricular septum; JVD, jugular venous distention; mPAP, mean pulmonary artery pressure; NT-proBNP, N-terminal pro-hormone of B-type natriuretic peptide; PAH, pulmonary arterial hypertension; PCWP, pulmonary capillary wedge pressure; PVR, pulmonary vascular resistance; RAE, right atrial enlargement; RVE, right ventricular enlargement; RVOT, right ventricular outflow tract; TAPSE, tricuspid annular plane systolic excursion; and TR, tricuspid regurgitation.

considered, although the criteria to identify which patients benefit from tricuspid valve intervention at the time of ASD repair require further study.<sup>24</sup>

6. Transcatheter options for several types of congenital heart disease offer shorter hospital stays and, in many cases, reduced morbidity and mortality. For ASD, transcatheter closure has been available most commonly for secundum defects that have adequate rims for device placement and, traditionally, in absence of partial anomalous pulmonary venous return. In a comparison of clinical outcomes with surgical versus transcatheter closure of secundum ASD, transcatheter closure conferred lower all-cause mortality, fewer total complications (major and minor), and shorter hospital stays.<sup>10</sup> Although patients in the transcatheter group more often had a residual shunt, the need for reintervention was similar to that in the surgical group.<sup>10</sup> It is important to consider each patient's characteristics. Although transcatheter closure

- is recommended, morbidity and mortality rates for both percutaneous and surgical closure are quite low, and a surgical approach may be preferable in some patients because of anatomic considerations or comorbid disease (ie, requirement for other concomitant cardiac surgical procedures).
7. In a small number of adults with an ASD, paradoxical embolism may occur, often due to concomitant systemic disease that predisposes the patient to veno-thromboembolic events such as clotting disorders, malignancy, kidney disease, and connective tissue disease. It is reasonable to use, for example, the Risk of Paradoxical Embolism score to identify patients with a thrombophilia who may benefit more from ASD closure than medical therapy alone.<sup>25</sup> In adults with known or suspected paradoxical embolism (particularly with evidence of concomitant thrombophilia<sup>25</sup>), ASD closure is indicated to prevent recurrence, regardless of defect size, chamber size, or Qp:Qs, in the absence of significant PAH or LV disease.
  8. Although every adult with an ASD should be assessed for concomitant PAH, those with less than severe PVR elevation may still be considered for ASD closure, with or without targeted PAH therapy, if criteria for optimal hemodynamics are met, in consultation with expert teams. PAH is considered present when PVR is >2 Wood units; however, patients with PVR of 2 to 5 Wood units have safely undergone and benefited from ASD closure.<sup>11-13,26</sup>
  9. Patients with PAH and PVR of 5 to 8 Wood units (and even up to 10 Wood units) on targeted PAH therapy have also been shown to undergo ASD closure safely and to benefit from it.<sup>11-13,26</sup> In the largest meta-analysis of adults with ASD and at least moderate PAH, most of the included studies classified severe PAH as having a baseline PVR  $\geq$  5 Wood units. Although the majority of the studies adopted a “treat-and-repair” approach, 4 studies reported on patients who went “straight to repair.”<sup>12</sup> Regardless of treatment status, improvements in mean PA pressure, PVR, 6-minute walk distance, and functional class were demonstrated, albeit to a greater extent in the treat-and-repair groups. Although mortality was low overall, average follow-up was short to medium term (about 3 years). Notably, reports on patients who have undergone a treat-and-repair strategy typically refer to follow-up intervals of 2 to 5 years, and long-term monitoring and benefit remain under study. Shunt closure with elevated PVR does not obviate the need for continued administration of direct PAH therapy and chronic specialized PAH management, which are recommended in this cohort.
  10. In adults with ASD and PAH, agreement about the expected reversibility of PAH remains controversial, and many clinicians worry about the safety of ASD closure, as it removes the outlet for elevated right heart pressure, which is concerning if PAH progresses. To alleviate the risk of removing the egress in cases of further escalating PA pressures, fenestrated closure has been commonly used. In a prospective study of adults with ASD and severe PAH (median PVR, 8.6 Wood units) who received 3 months of up-front dual PAH therapy, followed by fenestrated transcatheter closure, hemodynamics (mean pulmonary artery pressure, PVR) and exercise capacity improved, and RV dimensions regressed.<sup>14</sup> Almost half of this cohort showed normalization of PA pressures at 1-year follow-up. No fenestrated transcatheter devices are currently available for percutaneous fenestrated ASD closure in the United States; however, a similar study utilizing dual up-front PAH therapy showed benefit with fenestrated surgical repair.<sup>27</sup> For adults with ASD and PAH in whom hemodynamics are optimized (PVR <5 Wood units), fenestrated closure provides an outlet when there is concern for further escalation of PA pressures, while providing hemodynamic and functional benefits (Figure 2).
  11. Nonsurgical closure options for superior SVASD are attractive compared with surgery. More specifically, superior SVASDs that override the superior vena cava result in a lack of tissue separating the superior vena cava from the right upper pulmonary vein, leaving this structure “unroofed” and causing a left-to-right atrial level shunt. In adults with right upper pulmonary vein return confined to the cavoatrial junction and not extending beyond the superior vena cava/fossa ovalis border, covered stent closure (assessed on cross-sectional imaging) may be reasonable. In adults with superior SVASD and an anomalous right upper pulmonary vein in whom transesophageal echocardiography-guided test-balloon interrogation of the cavoatrial junction confirms the right upper pulmonary vein’s redirection of flow to the left atrium, transcatheter closure by an operator with ACHD expertise may be considered. Several studies have shown that at least half of patients with this type of anatomy may be technically suitable for transcatheter closure.<sup>16,17,28</sup> A contemporary analysis

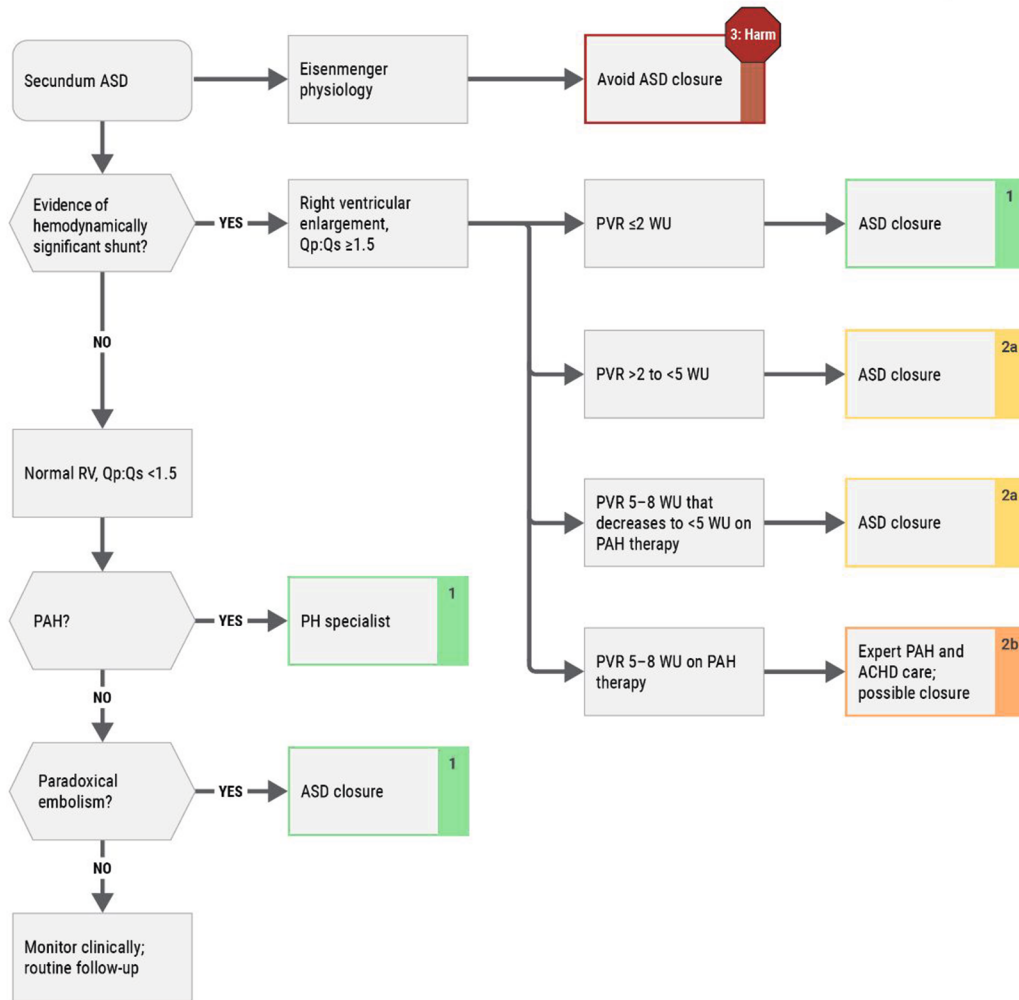
**FIGURE 2** Closure Considerations for Secundum Atrial Septal Defect

## Closure Considerations for Secundum Atrial Septal Defect

**LEGEND**

- COR 1
- COR 2a
- COR 2b
- COR 3-No Benefit
- COR 3-Harm

(Class of Recommendation)



All ASD closure recommendations assume the patient has no evidence of significant left heart disease. \*Therapy, PAH-directed medical therapy. ACHD indicates adult congenital heart disease; ASD, atrial septal defect; PAH, pulmonary arterial hypertension; PH, pulmonary hypertension; PVR, pulmonary vascular resistance; Qp:Qs, pulmonary-to-systemic blood flow ratio; RV, right ventricle; and WU, Wood units.

of adults undergoing surgical superior SVASD repair showed low in-hospital and 30-day mortality rates (<1%).<sup>29</sup> For patients who wish to avoid surgery, procedural success is typically >95% in eligible transcatheter cases, with no deaths, and a low incidence of complications, suggesting that a transcatheter approach may be reasonable.<sup>16,18</sup> Although data do not yet support a higher-level recommendation, evidence continues to accumulate, and nonsurgical closure options for superior SVASD are expected to evolve and become more widely available.

12. Perhaps the most difficult ASD-PAH profile is in patients with severe baseline PAH who have some improvement on PAH-directed therapies yet do not achieve PVR <5 Wood units. However, some studies have shown a benefit of ASD closure even when PVR is  $\geq 5$  Wood units. For example, He et al<sup>26</sup> showed that closure in a subset of 17 patients with PVR  $\geq 5$  Wood units was safe with continued PAH therapy (no deaths at 31 months and improvement in hemodynamics in 16 months). In a study by Bradley et al<sup>11</sup> involving 19 patients who underwent a treat-to-close approach, the average PVR was 6.4 Wood units at baseline and <5 Wood units at 4.4 years. Limited data suggest that some patients with higher PVR on medical therapy (8 to 10 Wood units) may benefit from a treat-and-repair approach. In a study by Takaya et al,<sup>13</sup> 14 patients in the cohort had PVR  $\geq 5$  Wood units (mean, 9.7), and all survived with no hospitalizations. As early as 2012, Cho et al<sup>15</sup> showed that 16 patients receiving PAH therapy (mean PVR, 9.8 Wood units) underwent safe surgical fenestrated closure. All these studies are small, and data on this approach remain limited. However, there is likely to be a narrow range within which fenestrated closure may be reasonable for an adult with ASD and PAH whose PVR is  $\geq 5$  Wood units; such cases require careful reanalysis of data and repeat invasive hemodynamic assessment after PAH therapy, as offering closure could be dangerous if PAH remains progressive. Therefore, it is critical that such patients receive collaborative care from expert ACHD and pulmonary hypertension teams to carefully weigh risks and benefit, and longer-term studies are needed to continue to assess outcomes in this group of patients.
13. Initial attempts to repair large intracardiac shunts in children took place in the 1970s, and outcomes were poor. Eventually, PVR thresholds became better understood—specifically, that the presence of Eisenmenger syndrome was associated with the worst prognosis.<sup>20,21</sup>

#### 4.1.2. Ventricular Septal Defect

**Recommendations for Ventricular Septal Defect**  
Referenced studies that support recommendations are summarized in the [Evidence Table](#).

COR	LOE	RECOMMENDATIONS
<b>Diagnostic</b>		
1	B-NR	1. Patients with an unrepaired VSD should be assessed for the presence of PAH to guide decisions about medical therapy and repair. <sup>1-3</sup>
1	B-NR	2. In adults with a perimembranous VSD being considered for repair, evaluation to exclude right ventricular outflow tract (RVOT) obstruction or double-chambered right ventricle (DCRV) is recommended to improve management planning. <sup>4-6</sup>
1	C-LD	3. Adults with a VSD (repaired or unrepaired) and PAH should be followed by specialists with expertise in ACHD and pulmonary hypertension to reduce morbidity and mortality. <sup>7-11</sup>
<b>Therapeutic</b>		
1	B-NR	4. In adults with a VSD, a significant left-to-right shunt (Qp:Qs $\geq 1.5$ ), and significant or progressive LV dilatation with no evidence of PAH (PVR $\leq 2$ Wood units), closure of the defect is recommended to eliminate the shunt and preserve ventricular function. <sup>8,12</sup>
2a	C-LD	5. In adults with a VSD, LV volume overload, Qp:Qs $\geq 1.5:1$ , and mild PAH (PVR >2 but <5 Wood units), closure of the VSD is reasonable to eliminate the shunt, in order to reduce the risk for progressive PAH and the burden of chronic volume overload on the LV. <sup>2,9,13,14</sup>
2a	C-LD	6. In adults with an outlet or perimembranous VSD causing progressive moderate or greater aortic regurgitation, closure of the VSD is reasonable to preserve aortic valve function. <sup>15-18</sup>
2b	C-LD	7. In adults with a recent history of infective endocarditis involving a VSD, closure of the VSD may be reasonable to reduce the risk for recurrent endocarditis. <sup>3,6,19,20</sup>

Continued on the next page

Continued		
COR	LOE	RECOMMENDATIONS
2b	C-LD	8. In adults with a VSD, Qp:Qs $\geq 1.5$ , and PAH (PVR 5 to 8 Wood units) without hypoxemia, if PVR drops to $< 5$ Wood units with PAH therapies, usefulness of closure of the VSD is uncertain to reduce the risk for progressive PAH and the burden of chronic volume overload on the left ventricle. <sup>9,14,21-23</sup>
3: No Benefit	B-NR	9. In adults with a VSD, Qp:Qs $< 1.5$ , and no other indications, closure should not be performed to avoid unnecessary perioperative risks. <sup>6,24</sup>
3: Harm	B-NR	10. In adults with a VSD and Eisenmenger physiology, VSD closure should not be performed to avoid escalating morbidity and mortality. <sup>11,13,24-27</sup>

**Synopsis**

VSD, the most common congenital heart defect after aortic valve defects, can cause volume loading of the left heart depending on the size of the shunt and ratio of pulmonary to systemic vascular resistance. The spectrum of isolated VSDs in adults includes:

- Pressure- and volume-restrictive VSDs: small restrictive defects, with a high-pressure gradient ( $> 64$  mm Hg) between the left and right ventricles and a small left-to-right shunt
- Pressure-restrictive, but not volume-restrictive, VSDs: moderate-size restrictive defects (Qp:Qs  $\geq 1.5$  but  $< 2$ ) that may have developed PAH (ie, pulmonary vascular disease), LV dilatation, or both
- Large nonrestrictive defects that, in the absence of RVOT obstruction, are typically associated with Eisenmenger syndrome in adults
- Previously closed defects with patch leaks and PAH and/or LV dilatation.

Figure 3 depicts a diagnostic and treatment algorithm for VSD.

The long-term survival of patients with restrictive VSD is excellent but not identical to that of the general population because of the need for surgery/intervention and other morbidity (eg, infective endocarditis).<sup>3,12,24,28</sup> In uncomplicated restrictive VSDs without associated complications or signs of LV overload, infrequent cardiology

follow-up (every 3 to 5 years) is reasonable to ensure early detection of complications and patient education.<sup>3,6,12,24</sup> All patients with repaired VSD should be monitored periodically to detect late postclosure PAH or conduction system disease.<sup>1</sup> See Table 14 for suggested routine testing and follow-up intervals.

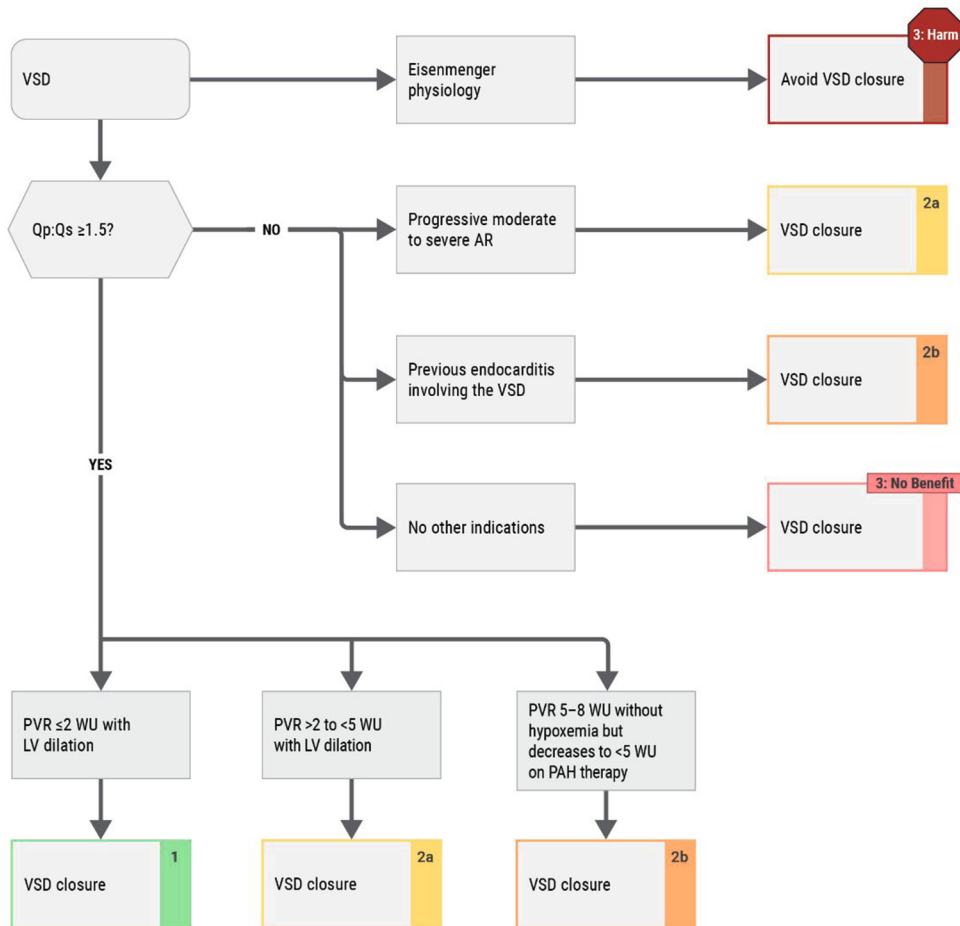
**Recommendation Specific Supportive Text**

1. PAH is a well-described complication of VSDs, whether untreated or previously closed. The presence and severity of PAH greatly influences clinical decision-making about repair and medical therapy. The presence and severity of PAH should be evaluated with transthoracic echocardiography during regular ACHD follow-up and should be confirmed through cardiac catheterization.<sup>1,2</sup> The role of acute reversibility studies during cardiac catheterization in these patients remains controversial.<sup>14</sup>
2. Transthoracic echocardiography and, when indicated, transesophageal echocardiography play an important role in identifying the location and size of the VSD, potential associated lesions or complications (eg, sinus of Valsalva prolapse and/or aneurysm, aortic insufficiency, or DCRV) and can guide decisions about surgical versus percutaneous closure.<sup>4,5,17,18</sup>
3. Specialist care is recommended for all patients with PAH and ensures accurate diagnosis, risk stratification, and treatment with PAH therapies, when appropriate, with or without defect closure (see Section 4.1, “Shunt Lesions”).<sup>2,7-11</sup>
4. In adults, VSDs can cause LV volume overload, resulting in progressive LV dilatation and eventual LV dysfunction. In the absence of PAH (PVR  $< 2$  Wood units), patients with evidence of significant (at least moderate) or progressive LV dilatation should be considered for surgical or percutaneous closure. Surgical closure generally has low risk with good long-term results, but a small risk for arrhythmia, heart failure, endocarditis, and pulmonary hypertension.<sup>3</sup> Percutaneous closure can be performed in a carefully selected subset of patients with similar periprocedural risk and success rate for most muscular and some perimembranous VSDs (if no risk for interference with the aortic valve)<sup>29,30</sup>; however, perimembranous VSDs have an associated risk for complete heart block, as well as risks for valve and residual shunt, and no Food and Drug Administration-approved device is available in the United States.<sup>31-33</sup> Transcatheter devices also have been used intraoperatively for muscular and other types of VSDs.

**FIGURE 3** Closure Considerations for Ventricular Septal Defect

## Closure Considerations for Ventricular Septal Defect

LEGEND	
<span style="background-color: #90EE90; border: 1px solid black; display: inline-block; width: 15px; height: 10px;"></span>	COR 1
<span style="background-color: #FFD700; border: 1px solid black; display: inline-block; width: 15px; height: 10px;"></span>	COR 2a
<span style="background-color: #FFA500; border: 1px solid black; display: inline-block; width: 15px; height: 10px;"></span>	COR 2b
<span style="background-color: #FFB6C1; border: 1px solid black; display: inline-block; width: 15px; height: 10px;"></span>	COR 3-No Benefit
<span style="background-color: #8B0000; border: 1px solid black; display: inline-block; width: 15px; height: 10px;"></span>	COR 3-Harm
<small>(Class of Recommendation)</small>	



\*See Section 4.4.6, "Eisenmenger Syndrome." AR indicates aortic regurgitation; LV, left ventricular; PVR, pulmonary vascular resistance; Qp:Qs, pulmonary-to-systemic blood flow ratio; VSD, ventricular septal defect; and WU, Wood units.

5. In patients with a VSD, significant left-to-right shunt, and catheterization-confirmed PAH that is mild (PVR >2 but <5 Wood units), closure may be reasonable to abolish the shunt, thereby preserving LV function and reducing the risk for progressive PAH. Those benefits should be weighed against the perioperative risks and the risk for long-term progressive RV dysfunction and heart failure in patients with PAH after VSD closure.<sup>11,25</sup> Careful preoperative assessment and perioperative care in centers with pulmonary hypertension specialist support is important. Hemodynamic assessment after VSD closure is necessary to guide adjustment of PAH therapies and to minimize adverse effects from residual PAH.<sup>2,3,11,25,34,35</sup>
6. Outlet or perimembranous VSDs may allow prolapse of the right coronary cusp of the aortic valve into the defect, creating aortic insufficiency. The patient may also develop a sinus of Valsalva aneurysm that is at risk for rupture.<sup>15-18</sup> Prolapse of an aortic valve cusp through a VSD may lead to progressive aortic insufficiency and can be an indication for VSD closure in children, to avoid the need for early aortic valve replacement or repair. In adults, however, evidence on the rate of progression of aortic regurgitation in this setting is lacking. Depending on patient age, the potential risks and benefits of early preventive surgery should be weighed against a conservative approach that follows standard guidelines on timing of aortic valve replacement in patients with aortic insufficiency (ie, delaying surgery until severe insufficiency with ventricular dilatation has developed). At the time of VSD closure, aortic valve repair may be performed to stabilize or improve aortic insufficiency. For patients who meet criteria for aortic valve replacement, this procedure may be performed simultaneously with VSD closure.
7. Infective endocarditis is not uncommon in patients with VSD (unrepaired or repaired with a residual defect) and can have devastating effects.<sup>3,6,19,20,24,36</sup> In restrictive VSDs, infective endocarditis can involve the tricuspid valve and result in septic emboli to the lungs. In patients with nonrestrictive defects and severe PAH with shunt reversal, infective endocarditis carries a significant risk for devastating systemic emboli, including cerebral abscesses and cerebrovascular events (see relevant guidelines on antibiotic prophylaxis).<sup>37-39</sup> In patients with a history of infective endocarditis and a restrictive VSD, repair of the defect may be contemplated to reduce the risk for further episodes of infective endocarditis, although

**TABLE 14** Ventricular Septal Defect: Routine Follow-Up and Testing Intervals

Type of Follow-Up or Testing	Physiological Stage A*† (mo)	Physiological Stage B*‡ (mo)	Physiological Stage C* (mo)	Physiological Stage D* (mo)
Outpatient ACHD cardiologist	36-60	12-60	6-12	3-6
Electrocardiogram	36-60	12-60	12	12
Transthoracic echocardiogram	36-60	12-60	12	12

Modified with permission from Stout et al.<sup>48</sup> Copyright 2018 American Heart Association, Inc. and American College of Cardiology Foundation.

\*See Section 2.2 for details on the ACHD anatomic and physiological classification system.

†Some physiological stage A patients with spontaneously closed muscular ventricular septal defects without residual anatomic or hemodynamic sequelae can be discharged from routine cardiology follow-up and be seen on an as-needed basis.

‡Stage B patients with a ventricular septal defect and a hemodynamically insignificant shunt who have normal chamber size without pulmonary hypertension can be seen every 36 to 60 months. Patients with ventricular dilation, dysfunction, or arrhythmia should be seen more frequently.

ACHD indicates adult congenital heart disease.

evidence on the risk for recurrence after a single episode is limited. In patients with nonrestrictive VSDs and severe PAH (PVR >10 Wood units), surgery requiring cardiopulmonary bypass carries prohibitive risks, and closure of the defect is contraindicated.<sup>13,26</sup>

8. When a VSD is associated with PVR 5 to 8 Wood units, but still a significant left-to-right shunt (Qp:Qs ≥1.5), closure could be contemplated to abolish the excess LV volume load if PVR is <5 Wood units with PAH treatment, but this approach should be considered only in specialist centers because it carries significant perioperative risk with potential for RV failure.<sup>9,21,22,40-42</sup> In such patients, PAH therapy for at least 3 months could be introduced preoperatively to lower PVR.<sup>8</sup> If repeat cardiac catheterization confirms reduction in PVR to <5 Wood units, closure could be considered. Options include complete closure, or a unidirectional patch or atrial fenestration can be added to allow decompression of the right heart.<sup>21,43,44</sup> Expert perioperative ACHD and pulmonary hypertension care is strongly encouraged.<sup>42,45-47</sup> PAH therapy should be continued perioperatively and likely for the long term, guided by postoperative assessment that includes repeat cardiac catheterization. This “treat-and-repair” strategy has the strongest evidence for patients with ASDs and carries a risk for adversely affecting RV function, with potential implications for prognosis.<sup>11,22,25</sup> In patients with a significant left-to-right shunt who cannot undergo correction because of inadequate reduction in PVR with PAH therapies, the merits of long-term continuation of PAH therapy should be weighed against the risk for LV volume overload exacerbated by the PAH treatment.

9. The majority of unrepaired VSDs encountered in ACHD practice are pressure and volume-restrictive, with no evidence of volume overload of the LV or other sequelae; hence, closure should not be pursued even when it can be achieved at low risk (surgically or percutaneously). Prevention of infective endocarditis is not an indication for VSD closure in patients without previous infective endocarditis.
10. Surgical closure of nonrestrictive VSD in patients with severe PAH (PVR >10 Wood units), including those with Eisenmenger syndrome, is associated with unacceptably high mortality risk, both perioperatively and in the long term.<sup>11,13,24-26</sup> See Section 4.4.6, “Eisenmenger Syndrome,” for evaluation and management of severe PAH and Eisenmenger syndrome.

4.1.3. Atrioventricular Septal Defect

**Recommendations for Atrioventricular Septal Defect**  
Referenced studies that support recommendations are summarized in the Evidence Table.

COR	LOE	RECOMMENDATIONS
<b>Diagnostic</b>		
1	C-LD	1. Adults with an unrepaired AVSD or those with residual shunts after prior repair should be assessed for the presence of PAH to guide medical therapy and assess suitability for repair. <sup>1,2</sup>
1	C-LD	2. Adults with an AVSD (repaired or unrepaired) and PAH should be managed by clinicians with pulmonary hypertension expertise to improve outcomes. <sup>3</sup>
<b>Therapeutic</b>		
1	B-NR	3. In adults with repaired AVSD and left ventricular outflow tract (LVOT) obstruction with symptoms attributable to the obstruction, or LV systolic dysfunction (LV ejection fraction <50%), surgical repair is recommended to improve functional status and preserve ventricular function. <sup>4,5</sup>

*continued in the next column*

Continued		
COR	LOE	RECOMMENDATIONS
1	B-NR	4. In adults with repaired AVSD with a) symptomatic severe left atrioventricular valve regurgitation or b) asymptomatic severe left atrioventricular valve regurgitation with LV dilation (LV end-systolic diameter ≥40 mm) or LV systolic dysfunction (LV ejection fraction <60%), valve surgery is recommended to improve functional status and prevent worsening ventricular function. <sup>4,6,7</sup>
1	C-LD	5. In adults with an unrepaired AVSD or those with residual shunts after previous repair, significant left-to-right shunt (Qp:Qs ≥1.5), and/or significant or progressive atrial/ventricular dilatation with no PAH (PVR ≤2 Wood units), closure of the AVSD or residual shunt is recommended to improve functional class and clinical outcomes. <sup>6,8</sup>
2a	C-EO	6. In adults with an unrepaired AVSD or those with residual shunts after previous repair, significant left-to-right shunt (Qp:Qs ≥1.5), and/or significant or progressive atrial/ventricular dilatation with mild PAH (PVR >2 to <5 Wood units), closure is reasonable to improve functional class and clinical outcomes.
2b	C-LD	7. In asymptomatic adults with AVSD, LVOT obstruction, and progressive greater than mild aortic regurgitation, surgical repair may be reasonable to prevent worsening ventricular function and progressive aortic valve disease. <sup>5,6,9</sup>
3: Harm	C-LD	8. In adults with an unrepaired AVSD or those with residual shunts after previous repair demonstrating Eisenmenger physiology or PVR >10 Wood units, shunt closure should not be performed to avoid additional morbidity and mortality. <sup>10,11</sup>

**Synopsis**

AVSD—atrioventricular canal or endocardial cushion defect—accounts for 4% to 5% of congenital heart defects. It is characterized by a defect at the site of the atrioventricular septum and abnormalities of the atrioventricular valves. AVSD has several anatomic subtypes with distinct physiological manifestations, depending on the level of septal abnormality. Partial AVSD (incomplete atrioventricular canal or primum ASD) has only an ASD component, often with a cleft left atrioventricular valve. Complete AVSD (complete atrioventricular canal) has no fusion of the bridging leaflets, resulting in a large defect at the atrial and ventricular levels. Transitional AVSD (transitional atrioventricular canal) has attachments of the common atrioventricular valve to the crest of the septum, resulting in 2 functional atrioventricular-valve orifices; however, a pressure-restrictive VSD is present, along with a primum ASD and atrioventricular-valve abnormalities.

Patients with prior AVSD repair need long-term follow-up for residual shunts, atrioventricular-valve regurgitation, LVOT obstruction, and arrhythmias/conduction abnormalities.<sup>12,13</sup> Left atrioventricular-valve regurgitation is the most common reason for reoperations; LVOT obstruction is the second most common. Patients with AVSD have a posteriorly displaced atrioventricular node, with the His bundle system displaced inferiorly (near the VSD), resulting in a left-axis deviation pattern on electrocardiogram. Postoperatively, patients can be at risk for late-onset complete heart block, especially patients with postoperative conduction abnormalities.<sup>14,15</sup> An ACHD specialist should conduct routine follow-up screening for residual defects (see **Table 15** for suggested follow-up and testing intervals).

**Recommendation-Specific Supportive Text**

1. All adults with unrepaired AVSDs should be evaluated for the presence and severity of PAH, regardless of AVSD type. Patients with repaired AVSD and residual shunts should also be assessed for PAH, especially if being evaluated for closure of the shunt. Transthoracic echocardiography can be used at ACHD subspecialty visits to evaluate for the presence of PAH, and if detected, cardiac catheterization will be needed to confirm the presence of PAH. Given that surgical repair is dictated by the degree of PAH and direction of the shunt, thorough evaluation is needed for clinical decision-making.<sup>1,2,16</sup>
2. Adults with AVSD (repaired or unrepaired) and PAH should be managed collaboratively by an ACHD subspecialist and expert PAH subspecialists.<sup>3</sup> Treatment of PAH in accordance with current PAH guidelines can

**TABLE 15** Atrioventricular Septal Defect: Routine Follow-Up and Testing Intervals

Type of Follow-Up or Testing	Physiological Stage A* (mo)	Physiological Stage B* (mo)	Physiological Stage C* (mo)	Physiological Stage D* (mo)
Outpatient ACHD cardiologist	24-36	12-24	6-12	3-6
Electrocardiogram	24-36	12-24	12	12
Transthoracic echocardiogram	24-36	12-24	12	12

Modified with permission from Stout et al.<sup>21</sup> Copyright 2018 American Heart Association, Inc. and American College of Cardiology Foundation.

\*See **Section 2.2** for details on the ACHD anatomic and physiological classification system. ACHD indicates adult congenital heart disease.

- help to guide treatment course and surgical options for patients with AVSD and residual lesions/shunts.<sup>17</sup>
3. In adults with AVSD and LVOT obstruction, surgical repair is recommended when patients experience symptoms or LV function is decreased. Echocardiography may underestimate the true gradient, and cardiac catheterization may be needed to accurately assess the degree of obstruction given the complex nature of the LVOT obstruction in some patients. Echocardiographic gradients of peak  $\geq 50$  mm Hg (subaortic stenosis) or mean  $\geq 40$  mm Hg (valvular aortic stenosis) have been suggested as cutoffs for severe LVOT obstruction; however, indications for surgical repair should be based on the clinical presentation (symptoms, ventricular dysfunction) and associated valvular disease. Recent studies have shown a 2% to 4% risk of reoperation for LVOT obstruction after initial AVSD repair.<sup>4,5</sup> In addition, the risk of reintervention for repeat LVOT obstruction is high: 59% freedom from reoperation at 10 years.<sup>4,5</sup>
  4. Although the anatomic mechanism of left atrioventricular (mitral) valve regurgitation differs from that of chronic mitral regurgitation, indications for surgery should mirror those in current guidelines for chronic mitral regurgitation.<sup>18</sup> Left atrioventricular-valve surgery should be undertaken in patients with symptoms attributable to the valve dysfunction or those with LV dysfunction and/or LV dilation (end-systolic diameter  $> 40$  mm).<sup>4,6</sup> In asymptomatic patients, valve surgery can be considered with severe regurgitation and low surgical risk. Patients with repaired atrioventricular-canal defects should also be evaluated for residual right-sided atrioventricular-valve disease (stenosis or regurgitation). The mechanism of atrioventricular-valve regurgitation in AVSD is different than for an isolated mitral valve cleft. AVSD has a cleft in the anterior leaflet, owing to incomplete fusion of the endocardial cushions. Unlike an isolated mitral valve

cleft, the cleft in AVSD is directed toward the mid portion of the ventricular septum, not the aortic valve as in an isolated mitral valve cleft. The valve morphology, including the position of the annulus and papillary muscles, and the LVOT morphology warrant the expertise of a congenital heart surgeon. Primary repair should be performed, when possible, to minimize the risks associated with valve replacement. In general, outcomes and survival improve when a congenital heart surgeon performs the repairs.<sup>7</sup>

5. Most studies of primary surgical repair for AVSD focus on interventions during childhood. Long-term survival for partial AVSD repair has been reported to be as high as 94% at 30 years; although long-term studies are largely initiated in the pediatric population, preoperative heart failure has been shown to be a risk factor for death.<sup>8</sup> Long-term survival after complete AVSD repair is slightly lower (91% to 92% at 15 years), but with similar reintervention rates.<sup>4,19</sup> No large-scale studies have examined indications for closure of residual lesions specifically in AVSDs, but the guidance in Sections 4.1.1, “Atrial Septal Defect,” and 4.1.2, “Ventricular Septal Defect,” can be used in decision-making for AVSD (repaired or unrepaired). In guiding indications for repair, clinicians should give careful attention to hemodynamic evaluation of PVR, shunt volume, and directionality. For patients with a large left-to-right shunt, atrial/ventricular enlargement, and no PAH, closure is indicated to improve long-term clinical outcomes.
6. For patients with mild or moderate PAH, evaluation and comanagement with a pulmonary hypertension specialist is recommended before and after shunt closure, if repair is deemed to be indicated.<sup>20</sup>
7. For asymptomatic adults with AVSD and LVOT obstruction, surgical repair can be considered when peak Doppler gradients on echocardiography are  $\geq 50$  mm Hg, aortic valve regurgitation (greater than mild) is increasing, and surgical risk is low. Operative mortality has been shown to be low when the operation is performed by a congenital heart disease specialist at a center with ACHD expertise.<sup>5,7,9</sup> In a 45-year single-center experience of patients requiring LVOT reoperation after primary partial AVSD repair, 17 late deaths were reported, 5 of them secondary to heart failure.<sup>9</sup> It is possible for LV hypertrophy to develop with recurrent obstruction; careful follow-up at an ACHD center should evaluate for recurrence and sequelae.

8. Most adults with complete AVSD have had surgical repair in childhood; complete AVSD, left unrepaired, usually leads to irreversible pulmonary vascular disease, resulting in Eisenmenger physiology. Surgical repair in patients with severe PAH and/or Eisenmenger syndrome confers high mortality risk and should not be performed.<sup>12,13,20</sup>

#### 4.1.4. Anomalous Pulmonary Venous Connections

**Recommendations for Anomalous Pulmonary Venous Connections**  
Referenced studies that support recommendations are summarized in the [Evidence Table](#).

COR	LOE	RECOMMENDATIONS
<b>Diagnostic</b>		
1	B-NR	1. For adults with APVCs, CMR imaging is recommended to assess pulmonary venous anatomy, to evaluate RV size and function, and to determine shunt fraction (Qp:Qs). <sup>1-4</sup>
1	B-NR	2. For adults with APVCs who do not have an indication for repair, routine cardiac imaging is recommended for serial evaluation of RV size and function and for assessment of pulmonary hypertension. <sup>5,6</sup>
1	B-NR	3. For adults with repaired APVCs and dyspnea on exertion and/or reduced functional capacity, CMR or CT angiography is recommended to evaluate for venous obstruction or residual shunt. <sup>3,4</sup>
2a	B-NR	4. For adults with unrepaired APVCs and noninvasive evidence of, and/or risk factors for, PAH, cardiac catheterization can be useful to evaluate hemodynamics and aid in determining indication for repair. <sup>5,6</sup>
<b>Therapeutic</b>		
1	B-NR	5. For adults with APVCs who have cardiac symptoms and/or reduced functional capacity with RV volume overload, and whose Qp:Qs is $\geq 1.5$ , surgical repair is recommended to improve symptoms and clinical outcomes. <sup>6-9</sup>

Continued on the next page

Continued		
COR	LOE	RECOMMENDATIONS
1	B-NR	6. For adults with APVCs undergoing surgical repair for an ASD, repair of the APVC(s) is recommended, when technically feasible, to reduce left-to-right shunting and RV volume overload. <sup>6-9</sup>
2a	B-NR	7. For adults with APVCs who are asymptomatic; whose Qp:Qs is $\geq 1.5$ ; and who have severe or progressive RV volume overload, reduced RV systolic function, PAH by invasive measurement, or objective exercise intolerance, surgical repair is reasonable in order to improve hemodynamics and/or stabilize RV size and function. <sup>6-9</sup>
3: No Benefit	B-NR	8. For adults with APVCs who have a normal to mildly enlarged right ventricle and whose Qp:Qs is $< 1.5$ , surgical repair is not indicated, given the absence of data to support benefit. <sup>4,6</sup>

**Synopsis**

Isolated APVCs, without an ASD, are rare, have a risk for RV volume overload similar to that of ASD physiology, and confer risk for PAH. However, APVCs are distinct from ASD in several ways:

- Isolated APVCs are obligate left-to-right shunts.
- With no right-to-left shunt, there is no risk for paradoxical embolism or hypoxemia.
- In theory, although not formally studied, APVC shunt magnitude should not increase over time, as it is not directly influenced by RV/LV diastolic compliance.
- Cardiothoracic surgery is the only option for isolated APVCs.

See **Table 16** for a side-by-side comparison of APVCs with ASD.

The most common isolated APVCs are from the right upper pulmonary vein to the superior vena cava and from the left upper pulmonary vein to the left innominate vein. Given that shunt magnitude is not based on RV/LV diastolic compliance, the size of the vein (typically representing the size of the lung segment) and the number of anomalous veins determine the overall magnitude of the left-to-right shunt. Having  $>1$  APVC increases the risks for volume overload and PAH.<sup>8</sup> Several surgical

**TABLE 16** Comparison of Anomalous Pulmonary Venous Connections With Atrial Septal Defect

	Anomalous Pulmonary Venous Connections	Atrial Septal Defect
Shunt direction	Left-to-right only	Left-to-right, right-to-left, or bidirectional
Risk for paradoxical embolism	No	Yes
Risk for hypoxemia	No	Yes
Magnitude of shunt change over time	No	Yes
Right ventricular volume overload	Yes	Yes
Risk for pulmonary arterial hypertension	Yes	Yes
Transcatheter option	No	Yes

techniques can repair APVCs. The most common techniques are direct anastomosis to the left atrium or left atrial appendage (for left-sided veins) and baffling through a surgically created ASD (for right-sided veins). The Warden procedure involves disconnecting the proximal superior vena cava, connecting it to the right atrial appendage, and utilizing the distal superior vena cava to baffle the anomalous right-sided veins to the left atrium. See **Table 17** for suggested routine testing and follow-up intervals.

Scimitar vein has unique characteristics distinct from the classic form of isolated APVCs. The right-sided, typically right inferior, pulmonary vein connects to the inferior vena cava. There may also be associated pulmonary sequestration, PA hypoplasia, and/or aortopulmonary collaterals. The indications for repair are the same as for other forms of isolated APVCs, but the repair is more challenging, for it involves baffling of the anomalous vein to the left atrium behind the heart and greater risks for thrombosis and postrepair pulmonary vein stenosis.<sup>10,11</sup>

**Recommendation-Specific Supportive Text**

1. Cross-sectional 3-dimensional CMR imaging is superior to echocardiography and to cardiac catheterization angiography for delineating APVC anatomy, the connection to systemic veins/heart, and the relationship to the atrial septum. CT angiography may also be utilized when CMR is not feasible. CMR has the advantage of providing the Qp:Qs and measurements of RV size and function, and it does not expose the patient to ionizing radiation.

**TABLE 17** Anomalous Pulmonary Venous Connections: Routine Follow-Up and Testing Intervals

Type of Follow-Up or Testing	Physiological Stage A* (mo)	Physiological Stage B* (mo)	Physiological Stage C* (mo)	Physiological Stage D* (mo)
Outpatient ACHD cardiologist	36-60	24	6-12	3-6
Electrocardiogram	36-60	24	12	12
Transthoracic echocardiogram	36-60	24	12	12

For recommendations on CMR and CT angiography, see Section 4.1.4 supportive text for recommendations #1-3.

\*See Section 2.2 for details on the ACHD anatomic and physiological classification system.

ACHD indicates adult congenital heart disease; CMR, cardiovascular magnetic resonance; and CT, computed tomography.

- In patients who do not meet criteria for APVC repair, regular follow-up with echocardiography and/or CMR (every 3 to 5 years) allows for detection of changes in RV size, RV function, or the development of PAH. Stable findings provide reassurance.
- After surgical repair of APVCs, there is risk for pulmonary vein/baffle stenosis and, if a Warden procedure is performed, for superior vena cava obstruction.<sup>12</sup> The risk is related to the patient's age at repair (younger age confers greater risk), the complexity of repair, and the length of the venous connection/baffle. Scimitar vein repair appears to confer higher risk because of the length and location of the surgical repair. Therefore, routine imaging may be indicated to monitor the repair, and it is indicated for any heart failure symptoms. Echocardiography may 1) image the APVC routed to the left atrium; 2) detect abnormal Doppler pulmonary venous flow patterns, consistent with obstruction; and/or 3) show signs of pulmonary hypertension. In asymptomatic patients with no echocardiographic 2-dimensional Doppler abnormalities, cross-sectional imaging is not indicated. Any heart failure symptoms and/or echocardiographic abnormalities may raise concern for pulmonary venous obstruction and warrant cross-sectional imaging. Advanced imaging with CMR or CT angiography provides more detailed imaging of the APVC/baffle connection to the left atrium.<sup>13</sup>
- Invasive hemodynamics may be necessary to determine eligibility for APVC repair and/or identify other causes of pulmonary hypertension, such as left heart disease. When echocardiography shows signs of pulmonary hypertension and in patients with risk factors for pulmonary hypertension, cardiac catheterization should be considered to determine the magnitude and

etiology of the pulmonary hypertension. Risk factors may include older age, obstructive sleep apnea, additional intracardiac shunts, and other known causes of pulmonary hypertension (eg, connective tissue disease, portal hypertension). Any cardiac catheterization should be performed by a congenital heart disease interventionalist. Calculating accurate pulmonary blood flow is necessary to quantify PVR and Qp:Qs and, when catheterization is not performed properly, may lead to repeat heart catheterization or to detrimental decisions regarding repair.

- The magnitude of left-to-right shunting determines the likelihood of developing cardiac symptoms and RV volume overload. A single APVC is therefore less likely than >1 APVC to lead to cardiac symptoms and reduced functional capacity. Reduced functional capacity may be determined subjectively or objectively with formal CPET. In patients who have cardiac symptoms or reduced functional capacity, and those who have RV volume overload and elevated Qp:Qs, surgical repair is indicated to improved RV size, right-sided hemodynamics, and quality of life. Surgical repair should be performed by congenital heart surgeons with experience in rerouting and baffling APVCs to the left atrium.
- Patients with APVCs who undergo surgical repair for an ASD should also undergo APVC repair at the same time, to reduce any magnitude of left-to-right shunt. However, if a secundum defect can be closed in the catheterization laboratory and the APVC is isolated and small, shared decision-making may lead to a nonsurgical approach. Also, if the ASD is being repaired surgically and the APVC is small, isolated, and/or technically challenging (with risk for postoperative pulmonary vein stenosis), the best approach may be to leave the APVC unrepaired.
- In asymptomatic patients with APVCs and evidence of progressive changes in RV size, RV systolic dysfunction, and/or development of PAH, surgical repair may need to be considered. When APVCs are first diagnosed, the initial imaging cannot clarify for how long the right ventricle has been enlarged or if any changes have occurred over time (possibly decades). It is reasonable to follow newly diagnosed patients; any evidence of progression or development of PAH may be an indication for repair. Whether changes in the right ventricle meet the definition of "progressive changes" should be based on clinical observations

over time. Certainly, changes leading to severe RV dilation and the development of RV systolic dysfunction would be concerning and worthy of considering surgical repair.

8. For patients with APVCs, typically involving a single pulmonary vein; a normal to mildly enlarged right ventricle; and an estimated low shunt fraction (Qp:Qs), surgical repair is not indicated, as the potential risk from the repair and the postoperative risk of pulmonary vein/baffle stenosis are greater than the benefit of the repair. Patients can be followed for any changes in RV size and systolic function, but that is unlikely given that the magnitude of the shunt should not change over time. For patients with cardiac symptoms and/or reduced functional capacity in this clinical scenario, workup should be directed elsewhere, to avoid unnecessary surgery.

4.1.5. Patent Ductus Arteriosus

**Recommendations for Patent Ductus Arteriosus**  
 Referenced studies that support recommendations are summarized in the Evidence Table.

COR	LOE	RECOMMENDATIONS
<b>Diagnostic</b>		
1	C-LD	1. Adults with a PDA and PAH should be managed by an ACHD specialist and clinicians with pulmonary hypertension expertise, to minimize morbidity and mortality. <sup>1</sup>
1	C-EO	2. Patients with an unrepaired PDA should be evaluated for PAH to guide recommendations for treatment.
1	C-EO	3. Adults with a PDA should undergo assessment of LV function and left-sided chamber size with echocardiography and/or CMR imaging, to guide recommendations for treatment.
2a	C-LD	4. In adults with a PDA and PAH, balloon test occlusion of the PDA can be useful to facilitate accurate quantification of PVR and to identify patients who are candidates for closure. <sup>2</sup>

*continued in the next column*

Continued		
COR	LOE	RECOMMENDATIONS
<b>Therapeutic</b>		
1	C-LD	5. In adults with a PDA, left heart enlargement attributable to the PDA, a net left-to-right shunt, and no evidence of PAH (PVR ≤2 Wood units), closure to eliminate the shunt is recommended to improve clinical outcomes. <sup>3-5</sup>
2a	C-LD	6. In adults with a PDA, left heart enlargement attributable to the PDA, a net left-to-right shunt, and PVR >2 but <5 Wood units, closure to eliminate the shunt is reasonable to improve clinical outcomes. <sup>6-8</sup>
2b	C-EO	7. In adults with a PDA, left heart enlargement attributable to the PDA, a net left-to-right shunt, and moderate PAH (PVR 5 to 8 Wood units), closure may be considered if the PVR drops to <5 Wood units with initiation of PAH therapies.
3: No Benefit	C-EO	8. In asymptomatic adults with a PDA, no evidence of left atrial or LV enlargement, and no prior history of endarteritis, closure has no benefit.
3: Harm	C-LD	9. In adults with a PDA and Eisenmenger syndrome or PVR >10 Wood units, closure to eliminate the shunt should not be performed to avoid additional morbidity or mortality risk. <sup>9</sup>

**Synopsis**

The PDA, a remnant of fetal circulation connecting the descending aorta to the main PA, can occur in isolation or in conjunction with additional lesions. PDAs are found in approximately 0.3% to 0.8% of full-term infants and may be more common in females.<sup>10</sup> Although many PDAs are closed during infancy or childhood, some remain patent into adulthood. The effect of a PDA is a function of the degree of shunting through the ductus into the PA, which depends on its size, its anatomic configuration, and the relative systemic and pulmonary resistances. Small, hemodynamically insignificant PDAs may be inaudible on

**TABLE 18** Patent Ductus Arteriosus: Routine Follow-Up and Testing Intervals

Type of Follow-Up or Testing	Physiological Stage A*† (mo)	Physiological Stage B*‡ (mo)	Physiological Stage C* (mo)	Physiological Stage D* (mo)
Outpatient ACHD cardiologist	36-60	12-60	6-12	3-6
Electrocardiogram	36-60	12-60	12	12
Transthoracic echocardiogram	36-60	12-60	12	12

Modified with permission from Stout et al.<sup>15</sup> Copyright 2018 American Heart Association, Inc. and American College of Cardiology Foundation.

\*See Section 2.2 for details on the ACHD anatomic and physiological classification system.

†Stage A patients who had closure of their PDA during infancy without residual shunt, chamber dilation, or complications can likely be discharged from cardiology care or be seen on an as-needed basis

‡Stage B patients with a PDA and a hemodynamically insignificant shunt who have normal chamber size without pulmonary hypertension can be seen every 36 to 60 months. Patients with ventricular dilation, dysfunction, or arrhythmia should be seen more frequently.

ACHD indicates adult congenital heart disease; and PDA, patent ductus arteriosus.

auscultation and result in insufficient shunting to cause left heart enlargement or PAH. Larger shunts may result in PAH from pulmonary overcirculation and can lead to left heart dilation from volume overload. Closure is recommended in patients with evidence of left heart enlargement attributable to the shunt without PAH. Closure of a PDA in the setting of Eisenmenger syndrome is contraindicated. Patients with a PDA and PAH who have not progressed to Eisenmenger syndrome should be managed by a team that involves clinicians with PAH expertise, to facilitate decision making about PAH-directed therapy and possible PDA closure. See Table 18 for suggested routine testing and follow-up intervals.

**Recommendation-Specific Supportive Text**

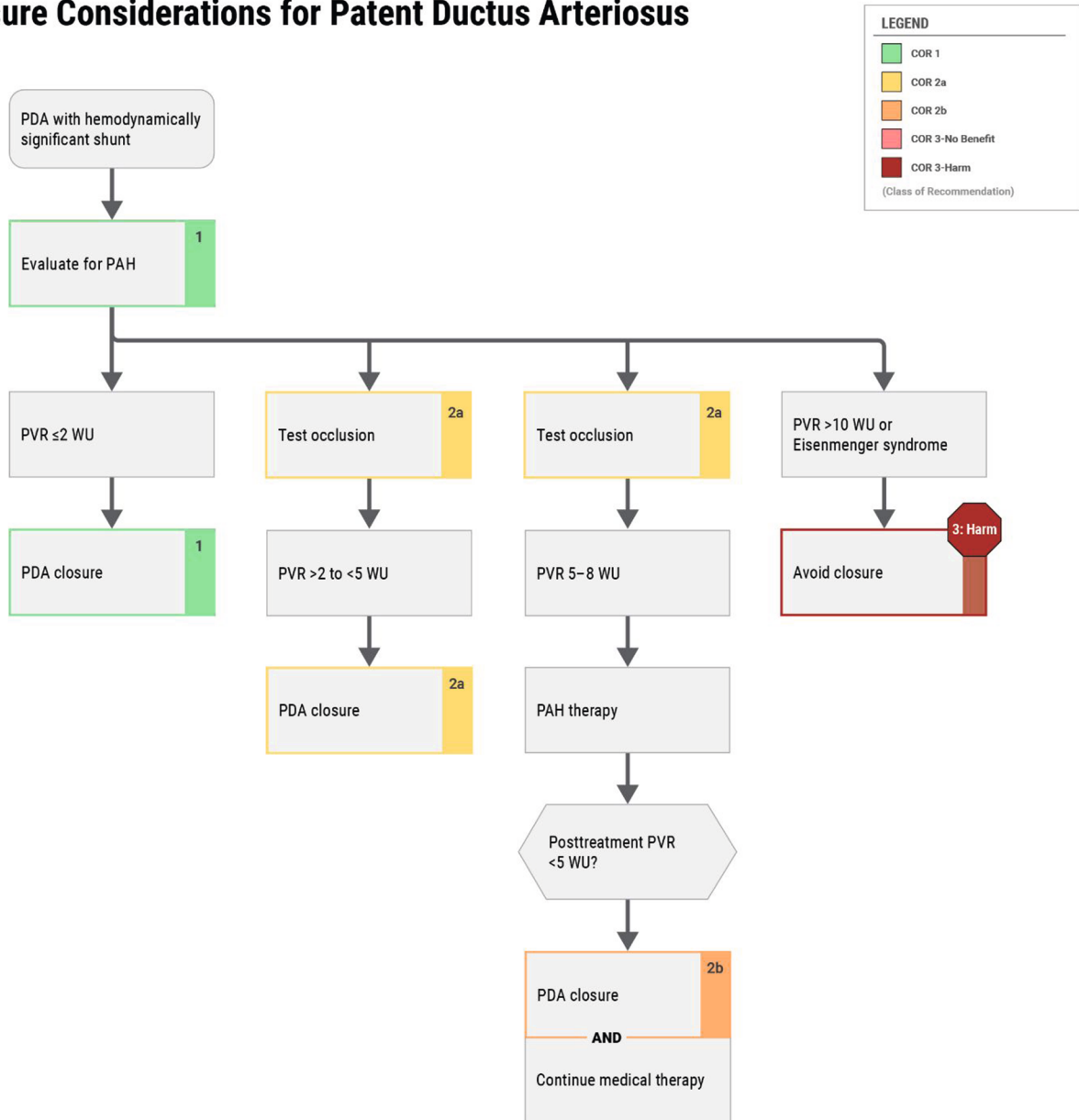
1. Increasing evidence suggests that management of patients with PAH at specialty centers with expertise in pulmonary hypertension improves patient outcomes.<sup>1</sup> Consequently, if the ACHD provider does not have pulmonary hypertension expertise, adults with a PDA and PAH should be managed by a team that consults with clinicians who have such expertise.
2. Longitudinal exposure to shunting and pulmonary overcirculation can lead to the development of PAH in a minority of adult PDA cases. PAH—defined as a PVR ≥2 Wood units, a mean PA pressure ≥20 mm Hg, and a pulmonary capillary wedge pressure ≤15 mm Hg—can have a significant effect on PDA management and on decisions regarding closure and use of pulmonary vasodilators. Consequently, all adults with an unrepaired PDA should undergo assessment for PAH, including (at minimum) historical and physical examination, an electrocardiogram, and a transthoracic echocardiogram. Because cyanosis caused by

right-to-left shunting may occur downstream of the ductal insertion into the aorta, assessment of oxygen saturation by oximetry should be done in the feet and both hands of all patients, to assess for right-to-left shunting. In patients for whom PAH is suspected or cannot be ruled out by noninvasive testing, invasive hemodynamic assessment with cardiac catheterization should be pursued before device closure is considered.<sup>11</sup>

3. In adults with a PDA, echocardiography may be utilized for diagnosis, characterization of the degree of left-sided remodeling, and initial assessment for pulmonary hypertension. In addition to echocardiography, CMR imaging allows for noninvasive flow assessment and calculation of Qp:Qs, superior quantification of LV volume and function, and detailed anatomic delineation of ductal anatomy and characteristics. Because closure before the development of significant LV dilation may reduce the probability of postclosure LV dysfunction,<sup>3</sup> CMR should be considered early in the evaluation of adults with a PDA, to ensure there is no evidence of LV remodeling. When CMR is not feasible, cardiac CT may be pursued, particularly if improved delineation of PDA anatomy or the aortic arch is warranted before considering transcatheter device closure by an operator with ACHD expertise.
4. Invasive measurement of pulmonary arterial saturation can be influenced by the location of the insertion point of the PDA and catheter position, affecting pulmonary blood flow quantification. Consequently, catheter-based calculation of PVR can be inconsistent in the presence of a PDA. Measurement of pulmonary arterial saturation after temporary occlusion of the PDA should be considered, to minimize anatomic and operator-specific confounders and to accurately calculate PVR, particularly when PAH is suspected. Hybrid techniques, leveraging CMR to provide pulmonary blood flow measurements with a catheter-derived transpulmonary gradient, may also allow for accurate calculation of PVR in the presence of a PDA.<sup>12</sup> Before device closure in patients with a PDA and PAH, balloon test occlusion to assess for tolerance to closure of ductus should also be considered.<sup>2,6</sup> Multiple retrospective studies have shown that balloon test occlusion of the ductus may facilitate identification of patients with a PDA and PAH who cannot tolerate shunt closure. Although there are no established criteria, such studies have used the development of symptoms, an increase in PA pressure, or a drop in aortic pressure during test occlusion as indications to defer definitive closure in adults with a PDA and PAH.

**FIGURE 4** Closure Considerations for Patent Ductus Arteriosus

## Closure Considerations for Patent Ductus Arteriosus



5. In the setting of left heart enlargement attributable to the shunt and in the absence of PAH, closure of the PDA is indicated to prevent progressive LV enlargement, to prevent progression or development of PAH, and to reduce the likelihood of LV dysfunction (Figure 4). Similarly, closure prior to significant elevations in PA systolic pressure may be associated with improved postclosure ventricular function.<sup>13</sup> In adults with a history of PDA-associated endarteritis, closure may be considered (if not otherwise contraindicated) to reduce risk for recurrent infection. Typically, closure can be performed percutaneously with minimal risk and is preferred over surgical closure, which may be associated with additive risk.<sup>14</sup>
6. In adults with a PDA, a PVR of 2 to 5 Wood units, and a net left-to-right shunt, it is reasonable to consider PDA closure, in consultation with providers who have pulmonary hypertension expertise. In adults with a PDA and PAH, trial occlusion to assess for cardiac symptoms, an increase in PA systolic pressure, or a decrease in aortic pressure may be helpful to guide decision-making.<sup>6</sup>
7. In the adult PDA population, data on closure after reduction in PVR with targeted PAH therapy are lacking. However, small studies have shown improvements in PA systolic pressure and PVR following PDA closure in patients with PVR <10 Wood units, particularly in those with PVR <5 Wood units.<sup>8</sup> Adults with a PDA, PVR of 5 to 8 Wood units, and a net left-to-right shunt may be considered for PDA closure, in consultation with providers who have pulmonary hypertension expertise. There is a paucity of data on long-term outcomes for PDA closure in patients with moderate PAH, and on whether treatment with PAH-directed therapy before device closure helps to identify patients with a PDA and PAH who may benefit from closure. Available data suggest that closure in the setting of PVR >8 Wood units may be feasible but associated with less reduction in postprocedural PAH.<sup>8</sup> Adults with a PDA and moderate PAH may benefit most from trial occlusion, to ensure tolerability prior to closure.<sup>6,7</sup>
8. No data suggest benefit from PDA closure in patients with a small, hemodynamically insignificant shunt and no evidence of volume overload or prior episodes of endarteritis.
9. Given the high mortality and morbidity risks, PDA closure should not be performed in patients with a net right-to-left shunt or severe PAH (PVR >10 Wood units).<sup>9</sup>

## 4.2. Left-Sided Lesions

### 4.2.1. Cor Triatriatum Sinister

**Recommendations for Cor Triatriatum Sinister**  
Referenced studies that support recommendations are summarized in the Evidence Table.

COR	LOE	RECOMMENDATIONS
<b>Diagnostic</b>		
2a	B-NR	1. In adults with unrepaired cor triatriatum sinister, transesophageal echocardiography and/or cross-sectional imaging can be useful to identify the size and location of the membrane orifice and to assess for the presence of associated congenital cardiac defects. <sup>1,2</sup>
2a	B-NR	2. In adults with repaired cor triatriatum sinister and symptoms compatible with recurrent membrane obstruction, it is reasonable to evaluate for the presence of residual congenital cardiac defects, including pulmonary vein stenosis. <sup>2-5</sup>
<b>Therapeutic</b>		
1	B-NR	3. In adults with unrepaired cor triatriatum sinister and symptoms attributable to membrane obstruction, surgical resection is recommended to reduce the consequences of left atrial hypertension. <sup>1-3</sup>
1	C-LD	4. In adults with unrepaired cor triatriatum sinister and atrial fibrillation or atrial flutter, prior stroke, or left atrial thrombus, chronic anti-coagulation is recommended to prevent embolic stroke, whether or not conventional thromboembolic risk factors are present. <sup>6,7</sup>
2a	C-LD	5. In asymptomatic adults with unrepaired cor triatriatum sinister and severe membrane obstruction, surgical resection can be useful to prevent the sequelae of left atrial hypertension. <sup>1,2,8</sup>

*Continued on the next page*

**Continued**

COR	LOE	RECOMMENDATIONS
2a	C-LD	6. In adults with unrepaired cor triatriatum sinister and atrial fibrillation or atrial flutter, a rhythm control strategy can be beneficial to avoid clinical decompensation. <sup>1,8</sup>
2b	C-LD	7. In highly symptomatic adults with unrepaired cor triatriatum sinister, significant membrane obstruction, and elevated operative risk,* catheter-based intervention may be considered as a bridge to surgical resection. <sup>8</sup>

\*For example, decompensated heart failure, severe pulmonary hypertension, or pregnancy (see supportive text for details).

**Synopsis**

Cor triatriatum sinister is a rare congenital malformation (0.1% of clinical congenital heart disease)<sup>9</sup> characterized by a fenestrated fibromuscular membrane that divides the left atrium into proximal and distal chambers, with attachments to the atrial septum medially and to the embryologic left lateral ridge laterally. The distal chamber contains both the left atrial appendage and mitral valve. Given a shared pathophysiology with mitral stenosis, clinical manifestations are similar.

Cor triatriatum sinister is typically repaired in childhood, when it is associated with additional congenital heart defects in 80% of cases; many of the defects, such as pulmonary vein stenosis, require ongoing evaluation in adulthood. Although usually an isolated defect in adulthood, in up to 40% of cases cor triatriatum sinister can be associated with ASD, persistent left superior vena cava,<sup>1,3</sup> or partial anomalous pulmonary venous return.<sup>2,8</sup> Transesophageal echocardiography and cross-sectional imaging are excellent modalities for detecting associated defects. Although cor triatriatum sinister is sometimes diagnosed incidentally,<sup>10,11</sup> most adults present with gradual onset of heart failure or pulmonary hypertension, which can be effectively treated by surgical membrane resection. Less commonly, an abrupt presentation characterized by atrial arrhythmia or systemic thromboembolism<sup>2,8</sup> requires expedited rhythm control and chronic anticoagulation to prevent clinical decompensation and cardioembolic events.

**Recommendation-Specific Supportive Text**

1. Depending on its size and position, the cor triatriatum membrane may be poorly visualized by transthoracic echocardiography. Transesophageal echocardiography can confirm the diagnosis; identify the size, location,

and degree of obstruction through the membrane orifice; and detect additional lesions, such as ASDs and anomalous pulmonary venous return.<sup>1,2,11</sup> Three-dimensional echocardiography may further define the orifice shape and cross-sectional dimensions. Multimodality imaging for cor triatriatum sinister, including transesophageal echocardiography, CMR, or CT angiography, is used in up to 68% of patients in large series of adults.<sup>1</sup> In cases where noninvasive imaging is considered to be inadequate in determining the degree of membrane obstruction, or when associated pulmonary hypertension is suspected, cardiac catheterization can be performed. The transmembrane gradient is measured by comparing simultaneous pulmonary arterial wedge and LV diastolic pressures.

2. Particularly in infants and young children, cor triatriatum sinister may be associated with concomitant defects, such as pulmonary venous anomalies and/or stenosis, that can result in symptoms after intracardiac repair.<sup>2-5</sup> For adults with prior surgical repair of cor triatriatum associated with other congenital cardiac defects, advanced imaging can both identify and quantify those residual anatomical abnormalities.<sup>3</sup> Cross-sectional imaging, in particular CT angiography and CMR, can define the associated congenital defects and clarify pulmonary venous anatomy.<sup>1,12</sup> Despite successful intracardiac repair, regular follow-up by an experienced ACHD cardiologist allows for appropriate detection and management of residual cardiac sequelae (Table 19).

3. Although generally associated with larger orifice size and fewer additional cardiac anomalies in adults with cor triatriatum sinister, symptoms may be first reported in adulthood. Pathophysiological changes contributing to symptom development include fibrotic degeneration and calcification of the cor membrane,<sup>10,13,14</sup> new-onset atrial fibrillation, and progression of mitral regurgitation.<sup>15</sup> In most reports of adults with cor triatriatum sinister, progression of symptoms (dyspnea on exertion, orthopnea, and palpitations) is gradual.<sup>8</sup> Surgical resection for cor triatriatum sinister represents the only form of definitive therapy. To date, no instances of recurrent membrane obstruction after intracardiac repair have been reported.<sup>1,2,16</sup> Furthermore, the risks associated with operative repair have declined over time, with mortality in the modern era reported to range from 0% to 2%.<sup>1-3,11,16</sup>

4. Among adults with unrepaired cor triatriatum sinister, systemic thromboembolism is the first clinical presentation in 16% of patients overall and in up to 54% of patients with an acute presentation.<sup>5,8</sup> Potential factors that predispose to thrombus formation and systemic embolism include atrial fibrillation, left atrial

**TABLE 19** Cor Triatriatum Sinister: Routine Follow-Up and Testing Intervals

Type of Follow-Up or Testing	Physiological Stage A* (mo)	Physiological Stage B* (mo)	Physiological Stage C* (mo)	Physiological Stage D* (mo)
Outpatient ACHD cardiologist	36-60	12-24	6-12	3-6
Electrocardiogram	36-60	12-24	6-12	3-6
Transthoracic echocardiogram	36-60	12-24	12	12

For recommendations about timing of CMR and CT angiography, see Section 4.2.1 supportive text for recommendations #1 and #2.

\*See Section 2.2 for details on the ACHD anatomic and physiological classification system.

ACHD indicates adult congenital heart disease, CMR, cardiovascular magnetic resonance; and CT, computed tomography.

venous stasis within an obstructed proximal left atrial chamber, and paradoxical embolism through an associated ASD.<sup>6</sup> In addition, left atrial functional indices are reduced for patients with cor triatriatum sinister, compared with age- and sex-matched controls,<sup>17</sup> and a shared pathophysiology with moderate to severe mitral stenosis has been proposed.<sup>18,19</sup> Management after systemic thromboembolism includes chronic anticoagulation, and surgical resection is performed when additional, established indications for repair are present. Although data related to specific anticoagulants for cor triatriatum sinister are lacking, in related conditions such as rheumatic mitral stenosis, warfarin is favored over direct oral anticoagulants.<sup>18,20</sup>

- For asymptomatic patients, a previously proposed threshold for hemodynamically severe obstruction (mean estimated membrane gradient >15 mm Hg at rest or with exercise, by noninvasive Doppler interrogation)<sup>21</sup> or evidence of PAH are each associated with adverse cardiac outcomes and comport with existing guidelines for mitral valve stenosis intervention.<sup>18</sup> Given the association with additional congenital heart anomalies, some patients undergo operative resection while addressing concomitant congenital cardiac lesions. For women of childbearing age, routine follow-up is an opportunity to discuss pregnancy-associated risks and potential preconception intervention (Table 19).<sup>1</sup> Finally, approximately 60% of adults diagnosed with cor triatriatum sinister who have reassuring cardiac evaluation do not require surgery and can be managed expectantly.
- Patients with cor triatriatum sinister are at increased risk for atrial fibrillation due to chronic pressure elevation within the proximal left atrial chamber that contains the pulmonary veins and embryologic pulmonary venous component, with associated arrhythmogenic triggers.<sup>19</sup> Multiple reports describe an association between new-onset atrial fibrillation and clinical decompensation for cor triatriatum

sinister.<sup>8,16,22</sup> Atrial fibrillation leads to loss of atrial contraction and, often, an increase heart rate, both of which can contribute to heart failure symptoms in otherwise well-compensated individuals.<sup>22</sup> Limited data suggest that, for affected patients, long-term maintenance of sinus rhythm is possible with transcatheter ablation strategies<sup>23</sup> or surgical Maze operation.<sup>2</sup> The optimal approach is generally considered within the context of concomitant indications for operative repair by a surgeon with ACHD expertise.

- Catheter-based interventions are increasingly reported for adults with cor triatriatum sinister.<sup>24-32</sup> Patients may occasionally present in extremis with elevated cardiac operative risk related to decompensated heart failure or pulmonary hypertension.<sup>28,29</sup> Similarly, acute pulmonary edema and heart failure may develop during pregnancy or in the immediate postpartum period, when cardiac output reaches its zenith.<sup>33-37</sup> Pregnancy represents a transitory period of greatly increased maternal and fetal risk for cardiac operations involving cardiopulmonary bypass.<sup>38</sup> Although potential complications related to transcatheter intervention are recognized (eg, inadvertent atrial septal dilation, mitral valve damage, and cardiac perforation), existing reports suggest that percutaneous balloon dilatation can be performed safely and effectively at experienced centers with ACHD expertise.<sup>24-32</sup> Optimal candidates have isolated cor triatriatum characterized by a thin, noncalcified membrane.<sup>26</sup> Although acute results have been reported to be excellent, long-term follow-up remains limited, and regrowth of the cor triatriatum membrane may theoretically occur.<sup>31</sup>

#### 4.2.2. Congenital Mitral Stenosis, Including Shone Complex

**Recommendations for Congenital Mitral Stenosis, Including Shone Complex**  
Referenced studies that support recommendations are summarized in the Evidence Table.

COR	LOE	RECOMMENDATIONS
1	B-NR	1. Adults with congenital mitral stenosis or a parachute mitral valve should be evaluated for additional left-sided obstructive lesions to guide management. <sup>1,2</sup>
1	C-LD	2. Adults with multiple left-sided obstructive lesions (Shone complex) and suspected pulmonary hypertension should undergo invasive hemodynamic assessment to identify and classify pulmonary hypertension. <sup>3,4</sup>

**TABLE 20** Congenital Mitral Stenosis: Routine Follow-Up and Testing Intervals

Type of Follow-Up or Testing	Physiological Stage A* (mo)	Physiological Stage B* (mo)	Physiological Stage C* (mo)	Physiological Stage D* (mo)
Outpatient ACHD cardiologist	36-60	12-24	6-12	3-6
Electrocardiogram	36-60	12-24	12	12
Transthoracic echocardiogram	36-60	24	12	12

Modified with permission from Stout et al.<sup>6</sup> Copyright 2018 American Heart Association, Inc. and American College of Cardiology Foundation.

\*See Section 2.2 for details on the ACHD anatomic and physiological classification system.

ACHD indicates adult congenital heart disease.

**Synopsis**

Congenital stenotic anomalies of the mitral valve may occur in isolation (eg, parachute mitral valve, supralvalvar mitral ring, or double-orifice mitral valve) but often coexist with other left-sided obstructive lesions (Shone complex). Acquired mitral valve disease may also complicate other forms of congenital heart disease. In many instances, indications for intervention in congenital mitral valve disease can be extrapolated from the “2020 ACC/AHA Guideline for the Management of Patients With Valvular Heart Disease,”<sup>5</sup> which also covers mitral valve prolapse. However, balloon mitral valvuloplasty is rarely indicated or effective in congenital mitral stenosis. Section 4.1.3, “Atrioventricular Septal Defect,” discusses left atrioventricular valve regurgitation in the context of AVSDs. See Table 20 for suggested routine testing and follow-up intervals for congenital mitral stenosis.

**Recommendation-Specific Supportive Text**

1. Parachute mitral valve is most commonly found in the presence of other congenital abnormalities, such as the components of Shone complex. Recurrence and progression of the various associated lesions are expected, and repeat interventions are common. These patients’ mortality risk may be associated with other defects.<sup>2</sup> Therefore, patients with Shone complex require care at a center where such abnormalities can be followed and future interventions considered. Choices and techniques for valve repair or replacement are based on consideration of coexisting abnormalities, including the likelihood of future surgery.
2. Up to 50% of patients with Shone complex may have pulmonary hypertension, which substantially affects survival. The mechanisms of pulmonary hypertension include both precapillary and combined pre- and

postcapillary pulmonary hypertension. Periodic right heart catheterization with hemodynamic assessment and potential treatments may influence outcomes.<sup>3,4</sup>

**4.2.3. Subaortic Stenosis**

**Recommendations for Subaortic Stenosis**  
 Referenced studies that support recommendations are summarized in the Evidence Table.

COR	LOE	RECOMMENDATIONS
<b>Diagnostic</b>		
2b	C-EO	1. For patients with subaortic stenosis and equivocal symptoms, exercise stress testing may be considered to assess the physiological response to exercise and to determine whether symptoms are attributable to subaortic stenosis.
<b>Therapeutic</b>		
1	C-EO	2. For patients with symptoms attributable to subaortic stenosis, surgical repair is recommended to alleviate symptoms.
2b	C-LD	3. For asymptomatic patients with LV dysfunction or LV hypertrophy in the setting of subaortic stenosis, surgical repair may be considered to mitigate worsening LV function, hypertrophy, or both. <sup>1</sup>
2b	C-LD	4. For asymptomatic patients with subaortic stenosis and at least mild aortic regurgitation, surgical repair may be considered to prevent progressive aortic regurgitation. <sup>2</sup>

**Synopsis**

Subaortic stenosis encompasses a variety of lesions that include thin membrane, thick fibromuscular ridge, diffuse tunnel-like obstruction, abnormal mitral valve attachments, accessory endocardial cushion tissue, or postoperative sequelae. The guideline recommendations apply to “simple” discrete membrane and do not cover “complex” tunnel-like obstruction or hypertrophic cardiomyopathy, which is discussed in the 2024 Guideline for the Management of Hypertrophic Cardiomyopathy.<sup>3</sup>

Subaortic stenosis usually manifests before age 10 years and has a male predominance. Aortic regurgitation is commonly acquired due to turbulence of flow or

**TABLE 21** Subaortic Stenosis: Routine Follow-Up and Testing Intervals

Type of Follow-Up or Testing	Physiological Stage A* (mo)	Physiological Stage B* (mo)	Physiological Stage C* (mo)	Physiological Stage D* (mo)
Outpatient ACHD cardiologist	36	24	6-12	3-6
Electrocardiogram	36	24	12	12
Transthoracic echocardiogram	36	24	12	12

Modified with permission from Stout et al.<sup>10</sup> Copyright 2018 American Heart Association, Inc. and American College of Cardiology Foundation.

\*See Section 2.2 for details on the ACHD anatomic and physiological classification system.

ACHD indicates adult congenital heart disease.

membrane encroachment onto valve leaflets. In adults who do not undergo repair, subaortic stenosis and associated aortic regurgitation are slowly progressive; aortic regurgitation rarely becomes severe.<sup>1</sup>

Treatment of subaortic stenosis is surgical membrane resection, with or without myectomy, with a risk for heart block of 4% to 5%.<sup>4</sup> Recurrence after surgery is substantial—up to 25%—with a reoperation rate of 2% per year.<sup>2,5</sup> Some adults have undergone surgery in childhood, with a natural history that may be distinct from that of patients with no repair. The decision to operate on an asymptomatic patient must balance the natural history of subaortic stenosis against the risks for operative heart block and long-term recurrence. Applying a grading scheme for severity of aortic valve stenosis to determine an operative threshold in this population may not be appropriate for this reason. Although elevated gradients are associated with aortic regurgitation, need for surgical intervention, and lower survival,<sup>1,6,7</sup> the optimal threshold for operating on an asymptomatic patient without significant aortic regurgitation is not known. See Table 21 for suggested routine testing and follow-up intervals for subaortic stenosis.

**Recommendation-Specific Supportive Text**

1. Exercise stress testing can be helpful in evaluating symptoms to better understand the functional significance of subaortic stenosis. Similar to recommendations for aortic stenosis in the “2020 Guideline for the Management of Patients With Valvular Heart Disease,” exercise testing can provide additional diagnostic information for symptom evaluation.<sup>8,9</sup> Patients with subaortic stenosis may not recognize symptoms attributable to congenital LVOT obstruction for reasons that include lifetime experience with the lesion, slow growth of the

membrane, concomitant morbidities, and sedentary lifestyle. Supervised exercise stress testing is safe and can provide valuable information (beyond that from resting data), including symptoms, ischemic changes on electrocardiogram, blood pressure response to exercise, and exercise capacity. No data support exercise stress echocardiography to record LVOT gradients at peak exercise. If symptoms attributable to subaortic stenosis can be elicited, surgical repair may be considered.

2. Patients with symptomatic subaortic stenosis should undergo surgical repair to address symptoms. No data identify an echocardiographic gradient threshold at which a patient develops symptoms, nor one at which symptoms would be relieved by surgical resection.
3. The longstanding afterload of subaortic stenosis to which the LV is subjected may result in LV hypertrophy and, potentially, LV dysfunction. Theoretically, afterload reduction to the LV by surgically addressing LVOT obstruction could lead to improvements in LV function and prevent LV remodeling or its progression. There are limited studies in adults with asymptomatic subaortic stenosis that define an echocardiographic Doppler gradient warranting surgery to mitigate structural changes to the left ventricle. Published data suggest that higher gradients across the LVOT are associated with worse outcomes. In a multicenter, retrospective study on the natural history of unrepaired, discrete subaortic stenosis in adulthood, cumulative survival was 94% at 20 years. When stratified by baseline LVOT gradient on Doppler echocardiography, gradient  $\geq 50$  mm Hg demonstrated lower rates of intervention-free survival.<sup>1</sup>
4. No strong data support prophylactic surgery in adults to prevent progression of aortic regurgitation. Degree of subaortic stenosis is known to be associated with aortic regurgitation, however. In the pediatric literature, LVOT gradient  $\geq 50$  mm Hg on echocardiography is an independent risk factor for moderate to severe aortic regurgitation<sup>6</sup>; in adults, a peak gradient  $\geq 50$  mm Hg is associated with a higher probability of aortic regurgitation.<sup>1</sup> In a study of adults who had undergone prior surgery for subaortic stenosis, a preoperative LVOT gradient  $\geq 80$  mm Hg on post-hoc analysis was associated with progression to moderate aortic regurgitation postoperatively, suggesting that surgery should be considered before patients reach this threshold.<sup>2</sup> Notably, half of the study patients had undergone prior surgery in childhood, suggesting a need for caution in generalizing these results to adults who have not undergone repair.

4.2.4. Congenital Diseases of the Aortic Valve

**Recommendations for Congenital Diseases of the Aortic Valve**  
 Referenced studies that support recommendations are summarized in the Evidence Table.

COR	LOE	RECOMMENDATIONS
<b>Diagnostic</b>		
1	B-NR	1. Adults with a BAV should be screened for the presence of COA and aortic aneurysm to obtain early diagnosis and determine a management plan. <sup>1-4</sup>
1	B-NR	2. Adults with a BAV who have an aortic diameter >4 cm at the level of the sinuses or the ascending aorta, or who have risk factors for aortic dissection,* should undergo lifelong surveillance for progression of thoracic aortic disease to improve early detection of aortic growth. <sup>5-7†</sup>
2a	B-NR	3. In first-degree relatives of adults with a BAV, 1-time echocardiographic screening for the presence of a congenitally abnormal aortic valve or aortic aneurysm is reasonable to obtain early diagnosis. <sup>8-10</sup>
<b>Therapeutic</b>		
1	C-LD	4. In adults with a congenitally abnormal aortic valve who meet indication for valve replacement, surgical and transcatheter options should be reviewed by heart valve and ACHD expert teams in a shared decision-making process to determine a management plan. <sup>11-13</sup>
2b	B-NR	5. In young adults with congenital aortic valve stenosis, a noncalcified valve with no more than mild aortic regurgitation, and an indication for intervention, balloon valvuloplasty may be reasonable to delay the need for aortic valve surgery. <sup>14-16</sup>

\*Risk factors: family history of aortic dissection, aortic growth rate  $\geq 0.3$  cm/year, COA, "root phenotype" aortopathy. †Modified from the "2022 ACC/AHA Guideline for the Diagnosis and Management of Aortic Disease."<sup>21</sup>

**Synopsis**

BAV, the most common congenital cardiac abnormality, has an estimated prevalence of 4.6/1,000 live births and is 2 to 3 times more common in males.<sup>1-3,17</sup> Most cases result from an isolated abnormal fusion of 2 adjacent conotruncal endocardial cushions.<sup>17</sup> Broader cardiovascular disorders with congenital aortic valve abnormalities include truncus arteriosus, hypoplastic left heart syndrome (HLHS), abnormalities associated with Turner syndrome, Shone complex, and BAV associated with COA. Early signs of adverse structural LV remodeling due to eccentric aortic valve opening and diminished ascending aortic elasticity are common. Serial echocardiographic investigations and measurements of biomarkers, such as NT-proBNP, assist in evaluating the remodeling state.<sup>18,19</sup> See Table 22 for suggested imaging testing intervals for asymptomatic patients.

Other guideline indications for valve replacement<sup>20</sup> and prophylactic aortic replacement<sup>21</sup> generally apply. The recommendations above are more specific to the lifelong management of patients with congenital heart disease, many of whom undergo intervention at a young age and may need future interventions. Patients are often young adults, for whom lifestyle considerations (eg, athletics, employment, childbearing) may influence intervention type. The underlying anatomy should be considered in planning the surgery, which may also need to include lesions other than the aortic valve. Minimally invasive procedures, such as transcatheter aortic valve replacement, can be considered in select scenarios by operators with ACHD expertise, although valve durability in younger patients remains a relevant concern.<sup>22-24</sup>

**Recommendation-Specific Supportive Text**

1. COA is present in 4% to 10% of cases of BAV, whereas the prevalence of thoracic aortic disease in this population is reported to be as high as 30% to 40% in large referral centers.<sup>1-4</sup> To evaluate patients with BAV and thoracic aortic disease, echocardiographic imaging of the aorta is usually sufficient. In patients with limited acoustic windows or when the degree of aortic dilatation is within 0.1 to 0.2 cm of the interventional criteria (5 cm with the aforementioned risk factors, 5.5 cm without them), cross-sectional imaging such as cardiac-gated CT angiography or magnetic resonance (MR) angiography can be helpful.
2. Several retrospective studies show low incidences of aortic dissections (about 1%) and ascending aortic replacement (1% to 3%) in adults with a congenitally abnormal aortic valve, whether or not they underwent

**TABLE 22** Congenital Diseases of the Aortic Valve: Imaging Testing Intervals for Asymptomatic Patients With Normal LV Function

Frequency of Echocardiography	
Progressive (Stage B)	<p><b>Aortic stenosis</b></p> <ul style="list-style-type: none"> <li>Every 3-5 years (mild severity, <math>V_{max}</math> 2.0-2.9 m/s or mean <math>\Delta P &lt; 20</math> mm Hg)</li> <li>Every 1-2 years (moderate severity, <math>V_{max}</math> 3.0-3.9 m/s or mean <math>\Delta P</math> 20-39 mm Hg)</li> </ul> <p><b>Aortic regurgitation</b></p> <ul style="list-style-type: none"> <li>Every 3-5 years (mild severity)</li> <li>Every 1-2 years (moderate severity)</li> </ul>
Severe (Stage C)	<p><b>Aortic stenosis</b></p> <ul style="list-style-type: none"> <li>Every 6-12 months (<math>V_{max} \geq 4.0</math> m/s or mean <math>\Delta P \geq 40</math> mm Hg)</li> </ul> <p><b>Aortic regurgitation</b></p> <ul style="list-style-type: none"> <li>Every 6-12 months</li> <li>Dilating left ventricle: more frequently</li> </ul>
Aortic dilation $>4$ cm at the level of the sinuses, the ascending aorta, or both	<p>Periodic echocardiogram, CMR, or CT at intervals determined by:</p> <ul style="list-style-type: none"> <li>Degree and rate of progression of aortic dilatation</li> <li>Family history of aortic dissection</li> <li>History of coarctation</li> </ul>

Modified with permission from Otto et al.<sup>27</sup> Copyright 2020 American Heart Association, Inc. and American College of Cardiology Foundation.

CMR indicates cardiovascular magnetic resonance; CT, computed tomography; LV, left ventricular;  $V_{max}$ , maximum velocity; and  $\Delta P$ , peak pressure gradient.

valve replacement surgery, whereas progressive aortic enlargement was present in about 10%.<sup>5-7</sup> However, those studies may underappreciate the true rate of aortic dilation and adverse aortic outcomes, as they did not entirely identify the number of patients with high-risk features such as root dilatation, history of COA, and family history of thoracic aortic disease. In the absence of more granular data, lifelong screening for progression of aortic dilatation, especially in patients with high-risk features,<sup>20,21</sup> is recommended.

3. Familial inheritance of BAV may occur in an autosomal dominant pattern with variable penetrance. Pathologic variants in the *NOTCH1*, *ADAMTS19*, *SMAD6*, and *ROBO4* genes have been identified as causing abnormalities in formation of the aortic valve, LVOT, and aorta.<sup>8,9,17,25</sup> In 1 large meta-analysis of the prevalence of cardiovascular abnormalities in first-degree relatives of patients with a BAV, congenital aortic valve disease (mainly BAV) was present in about 7%, thoracic aortic disease in about 30% if the relatives also had a BAV, and about 7% if the relatives had a tricuspid aortic valve.<sup>8</sup> Characteristically, people with

more severe clinical phenotypes (ie, young at presentation, dissections or symptomatic disease, additional congenital cardiovascular lesions) are more likely to have affected relatives. Given those associations, first-degree relatives of patients with a BAV should undergo 1-time echocardiographic screening for the presence of an aortic valve abnormality and thoracic aortic disease.

4. Recent advances in aortic valve interventions for patients with congenitally abnormal valves include valve repair and the Ross operation (each intervention depends on anatomic feasibility) and bioprosthetic or mechanical valve replacement by surgeons with ACHD expertise. Transcatheter aortic valve replacement, an emerging option for patients with BAV, can be especially appealing as a temporizing measure in younger patients, to reduce the risk of redo sternotomies, in scenarios such as pregnancy or while awaiting transplantation. However, the long-term durability of transcatheter valves and the ability to fit into complex outflow tract anatomies remain relevant concerns in younger patients.<sup>22-24</sup>

Each intervention has significant implications for the patient's lifestyle, medical treatment, and need for future interventions. Therefore, an evidence-based shared decision-making process should be used to choose the type of intervention, based on patients' priorities and goals of care. Decision-making should encompass topics such as management, self-care, reproductive issues, and lifestyle changes, including sports participation and employment.<sup>11,26</sup> In 1 randomized trial involving patients without congenital heart disease who needed aortic valve replacement, those who received a shared decision-making intervention felt better informed and had greater knowledge of prosthetic valves, less anxiety and depression, and better mental well-being, without any more decision-related conflict than patients in the control group.<sup>12</sup>

5. Balloon dilation of the aortic valve is an accepted palliation for children, adolescents, and young adults with congenitally abnormal aortic valve stenosis (most commonly, a BAV) and no significant valve calcification.<sup>14,15</sup> Although some degree of postprocedural aortic regurgitation is common, balloon dilation allows for valve replacement or repair to be deferred until regurgitation becomes clinically significant. In adults with calcified aortic valve stenosis, the results of balloon valvuloplasty are less favorable, so that

approach is much less commonly used; even after successful reduction of systolic gradients, the effect is typically of limited duration.<sup>16</sup>

4.2.5. Supravalvar Aortic Stenosis

**Recommendations for Supravalvar Aortic Stenosis Referenced studies that support recommendations are summarized in the Evidence Table.**

COR	LOE	RECOMMENDATIONS
<b>Diagnostic</b>		
1	C-LD	1. In adults with suspected supravalvar aortic stenosis or with Williams syndrome, baseline aortic imaging is recommended to define the anatomy and severity of supravalvar aortic stenosis. <sup>1,2</sup>
1	C-LD	2. In adults with Williams syndrome and supravalvar aortic stenosis, baseline coronary imaging is recommended to evaluate for abnormalities such as coronary ostial stenosis. <sup>2-4</sup>
<b>Therapeutic</b>		
1	B-NR	3. In adults with supravalvar aortic stenosis who are symptomatic and/or have diminished LV systolic function due to stenosis, surgical repair is recommended to alleviate symptoms and preserve ventricular function. <sup>5,6</sup>
1	C-LD	4. Adults with supravalvar aortic stenosis and coronary ostial stenosis with symptoms of ischemia should undergo coronary artery revascularization to alleviate symptoms and preserve ventricular function. <sup>7</sup>
2b	C-EO	5. In adults with asymptomatic severe supravalvar aortic stenosis, normal ventricular size and function, and a normal exercise stress test, surgical repair may be considered to avoid worsening of cardiac function and symptoms.

**Synopsis**

Supravalvar aortic stenosis occurs distal to the coronary orifices at the sinotubular junction.<sup>8</sup> The stenosis can be in the form of a discrete, hourglass narrowing

(more common) or a diffuse, long-segment stenosis of the ascending aorta that can also be associated with stenosis of the brachiocephalic vessels.<sup>9</sup> Supravalvar aortic stenosis commonly occurs in patients with Williams syndrome, homozygous familial hypercholesterolemia, and nonsyndromic elastin arteriopathy syndrome.<sup>10-12</sup> Adults with supravalvar aortic stenosis should undergo baseline imaging for a detailed assessment of aortic anatomy. Adults with Williams syndrome and supravalvar aortic stenosis should have baseline evaluation for coronary artery abnormalities, to identify potential risks for SCD. Symptoms or reduced ventricular function associated with LVOT obstruction from supravalvar aortic stenosis should prompt surgical repair. Surgical revascularization is recommended in patients with supravalvar aortic stenosis and coronary ostial stenosis who have ischemic symptoms. See **Table 23** for routine testing and follow-up intervals.

**Recommendation-Specific Supportive Text**

1. Transthoracic echocardiography with Doppler is useful for deriving peak and mean pressure gradients across the area of supravalvar aortic stenosis from apical, suprasternal, and right parasternal views; however, visualization of the full extent of supravalvar aortic stenosis with transthoracic echocardiography is limited.<sup>1,13</sup> Transesophageal echocardiography is superior in this regard, but cross-sectional imaging (eg, CMR, MR angiography, CT angiography) provides detailed images of supravalvar aortic stenosis and, along with echocardiography, is used to assess patients before and after repair.<sup>2,3</sup>
2. Individuals with supravalvar aortic stenosis and Williams syndrome have increased risk for coronary abnormalities, including coronary ostial stenosis (most common), diffuse coronary stenosis, coronary artery dilation, or obstruction due to the aortic valve and/or sinotubular ridge.<sup>14</sup> The presence of significant coronary ostial stenosis increases the risk for SCD, especially when patients undergo anesthesia.<sup>15,16</sup> Many patients with Williams syndrome also have neurocognitive deficits and may be unable to describe their symptoms associated with coronary ischemia. Recent data also report that an electrocardiogram often shows no indicators of myocardial ischemia in patients with coronary abnormalities and Williams syndrome.<sup>17</sup> Baseline screening for coronary artery anomalies is therefore recommended in patients with Williams syndrome and supravalvar aortic stenosis if prior imaging has not been performed. Patients with nonsyndromic elastin arteriopathy can also be considered for screening, given the underlying abnormality in the elastin (*ELN*) gene.<sup>18</sup> Electrocardiography-gated

**TABLE 23** Supravalvar Aortic Stenosis: Routine Follow-Up and Testing Intervals

Type of Follow-Up or Testing	Physiological Stage A* (mo)	Physiological Stage B* (mo)	Physiological Stage C* (mo)	Physiological Stage D* (mo)
Outpatient ACHD cardiologist	24	24	6-12	3-6
Electrocardiogram	24	24	12	12
Transthoracic echocardiogram†	24	24	12	12

Modified with permission from Stout et al.<sup>26</sup> Copyright 2018 American Heart Association, Inc. and American College of Cardiology Foundation.

\*See Section 2.2 for details for ACHD anatomic and physiological classification system.

†Routine transthoracic echocardiography may be unnecessary if CMR imaging is performed to assess aortic anatomy.

ACHD indicates adult congenital heart disease; and CMR, cardiovascular magnetic resonance.

coronary CT angiography or invasive coronary angiography provides excellent visualization of the coronary arterial anatomy.<sup>3</sup> During cardiac catheterization, selective engagement of the proximal coronary can mask the presence of coronary ostial stenosis.<sup>14</sup>

- Like other forms of LVOT obstruction, severe supravalvar aortic stenosis can result in exertional symptoms and eventual reductions in LV systolic function.<sup>18</sup> Those symptoms may be unmasked during exercise stress testing, which can also reveal abnormal decreases in blood pressure response to exercise, related to supravalvar aortic stenosis. In adults with LV dysfunction related to supravalvar aortic stenosis and symptoms due to progressive obstruction, surgical repair is recommended to preserve cardiac function and alleviate symptoms. Although echocardiographic assessments for moderate (mean gradient 20-40 mm Hg) or severe (mean gradient >40 mm Hg) supravalvar stenosis are often extrapolated from valvular aortic stenosis, this extrapolation can be inaccurate because of anatomic variability. Adults who had surgical repair during childhood need to be followed, as long-term studies have shown higher reintervention rates related to residual lesion.<sup>5</sup> For patients with Williams syndrome, survival varies according to the type of original cardiac lesions. In a cohort of 200 patients operated on in childhood, overall 30-year survival was 90% but dropped to 83% in those with right- and left-heart obstructive lesions; 56% of late deaths were attributed to ischemic heart disease, arrhythmias, or heart failure.<sup>19</sup> Those outcomes may reflect some underlying coronary abnormalities or conduction system disorders in these patients.

- In contrast with other forms of LVOT obstruction, patients with supravalvar aortic stenosis have coronary arteries that are exposed to the higher pressure generated by the supravalvar obstruction.<sup>20</sup> Impaired coronary perfusion may occur because of varying degrees of aortic valve leaflet adhesion to the narrowed

sinotubular junction or because of fibrotic thickening in the area immediately surrounding the coronary ostia.<sup>21,22</sup> Those factors cause ostial stenosis with restriction in diastolic filling of the coronary arteries; the left coronary artery is most frequently involved. Patients who develop symptoms of coronary ischemia should undergo coronary revascularization to improve symptoms, reduce the risk for myocardial infarction, and preserve long-term ventricular function. The type of coronary revascularization, including the type of surgical repair, should be determined in collaboration with a congenital cardiac surgeon and/or a coronary interventionalist.

- Adults with severe supravalvar aortic stenosis without symptoms, normal LV size and function, and a normal exercise stress test can be considered for surgical repair, to prevent future symptomatic worsening and/or worsening LV function. Risk assessment to confirm the low-risk profile should be performed.<sup>23,24</sup> Echocardiographic assessments of supravalvar aortic stenosis severity often extrapolate the values used for valvular aortic stenosis, which may not be accurate.<sup>6</sup> Using the sinotubular junction, aortic annulus ratio has been suggested in the pediatric population but has not been shown in adults with supravalvar stenosis.<sup>25</sup> Careful assessment of anatomy with imaging and possible cardiac catheterization for hemodynamic assessment may be needed to determine degree of stenosis.

#### 4.2.6. Coarctation of the Aorta

**Recommendations for Coarctation of the Aorta**  
Referenced studies that support recommendations are summarized in the Evidence Table.

COR	LOE	RECOMMENDATIONS
<b>Diagnostic</b>		
1	B-NR	1. In adults with unrepaired COA, cross-sectional imaging is recommended to determine COA severity and delineate anatomy of the thoracic aorta. <sup>1,2</sup>
1	B-NR	2. In adults with repaired COA, periodic cross-sectional imaging is recommended to screen for recurrent COA, aortic root/ascending aorta aneurysms, and vascular complications related to COA repair (focal aortic aneurysm/pseudoaneurysms/dissection, and stent fracture). <sup>*1,3,4</sup>

Continued on the next page

Continued		
COR	LOE	RECOMMENDATIONS
1	B-NR	3. In adults with COA, blood pressure measurement at rest in the upper and lower extremities is recommended as part of routine clinical assessment to screen for hypertension and residual/recurrent COA. <sup>5</sup>
2a	B-NR	4. In adults with COA, ambulatory blood pressure measurement is reasonable to diagnose hypertension and monitor response to anti-hypertensive therapy. <sup>6-9</sup>
2a	B-NR	5. In adults with COA, exercise testing is reasonable to screen for exercise-induced hypertension. <sup>10,11</sup>
2a	B-NR	6. In adults with COA who present with exertional symptoms, evaluation for coronary artery disease is reasonable to guide management. <sup>12</sup>
2b	B-NR	7. In adults with COA, screening for intracranial aneurysms by brain MR or CT angiography may be considered to guide management. <sup>13</sup>
<b>Therapeutic</b>		
1	B-NR	8. In adults with native or repaired COA, surgical or transcatheter stent therapy is recommended for anatomically and hemodynamically significant COA to prevent irreversible LV dysfunction from chronic pressure overload. <sup>†1,14,15</sup>
1	B-NR	9. In adults with native or repaired COA and hypertension without hemodynamically significant COA, GDMT for hypertension is recommended to maintain controlled resting and ambulatory blood pressure. <sup>16,17</sup>

\*See Table 24. †See Table 25.

### Synopsis

COA, characterized by aortic isthmus stenosis, is sometimes associated with aortic arch hypoplasia, BAV, LVOT disease (subaortic stenosis), and LV inflow disease (supravalvar mitral stenosis, mitral valve stenosis, and

parachute mitral valve).<sup>4,18</sup> Collectively, those anatomic lesions (LVOT disease and aortic isthmus stenosis) cause LV pressure overload, which in turn leads to LV remodeling (hypertrophy, fibrosis, impaired relaxation and compliance, and impaired contractility).<sup>19,20</sup> In addition to those anatomic lesions, COA is characterized by physiological abnormalities such as endothelial dysfunction, abnormal smooth-muscle reactivity, and sympathetic hyperactivity.<sup>21-23</sup> These abnormalities lead to increased aortic stiffness and aortic pressure wave reflection, which in turn exacerbate LV remodeling caused by the anatomic lesions.<sup>21-23</sup>

Chronic LV remodeling initially manifests as asymptomatic LV diastolic and systolic dysfunction, as well as left atrial dysfunction.<sup>18,20,24</sup> LV remodeling may eventually progress to overt heart failure (mostly, heart failure with preserved ejection fraction), pulmonary hypertension, and atrial fibrillation.<sup>18,25,26</sup> COA is also associated with premature coronary artery disease and increased risk for stroke.<sup>11,12,27</sup> Table 24 shows the follow-up and testing schedule for adults with COA.

### Recommendation-Specific Supportive Text

1. COA diagnosis and repair mostly occur in infancy and early childhood. However, COA can be missed in childhood, leading to an initial diagnosis in adulthood, usually during evaluation for refractory hypertension.<sup>1,2</sup> Patients with a new or suspected COA diagnosis should undergo transthoracic echocardiography and cross-sectional imaging (CMR/CT angiography) to determine the severity of COA, aortic arch anatomy, and ascending aorta dimensions—and to rule out associated intracardiac lesions. Those findings provide critical information for choosing the optimal therapy for COA. If the severity of COA or aortic aneurysm at baseline does not warrant intervention, ongoing monitoring for disease progression with CMR or CT angiography may be required, with frequency of monitoring dependent on lesion severity.
2. Adults with repaired COA are at risk for developing vascular complications such as re-coarctation (restenosis of aortic isthmus); aortic wall injury and remodeling at the site of COA repair, leading to aneurysms/pseudoaneurysms; and aortic dissection involving any part of the thoracic aorta.<sup>1,3,4</sup> As a result, longitudinal imaging surveillance with transthoracic echocardiography and CMR/CT angiography is required for early detection of these complications, and then for timely intervention to reduce mortality risk. Furthermore, patients with COA and BAV (>60% of patients with COA) have increased risk for

**TABLE 24** Coarctation of the Aorta: Routine Follow-Up and Testing Intervals

Type of Follow-Up or Testing	Physiological Stage A* (mo)	Physiological Stage B* (mo)	Physiological Stage C* (mo)	Physiological Stage D* (mo)
Outpatient ACHD cardiologist	24	24	12	6
Electrocardiogram	24	24	12	6
Transthoracic echocardiogram	24	24	12	12

For recommendations on exercise testing, see Section 4.2.6 recommendation #5. For recommendations about timing of CMR and CT angiography, see Section 4.2.6 supportive text for recommendations #1 and #2.

Modified with permission from Stout et al.<sup>44</sup> Copyright 2018 American Heart Association, Inc. and American College of Cardiology Foundation.

\*See Section 2.2 for details on the ACHD anatomic and physiological classification system.

developing aortic root and ascending aorta aneurysms and, hence, need longitudinal imaging surveillance.<sup>4</sup> The frequency of imaging surveillance depends on cardiovascular lesions at baseline (Table 24). CMR is the preferred cross-sectional modality because it avoids radiation. However, CT angiography should be used in patients with prior COA stent implantation (because of stent artifacts associated with CMR) and may also provide screening for coronary artery disease. In patients without aortic aneurysm or residual COA, CMR/CT angiography may be performed every 5 years to monitor for development of aneurysm or recurrent COA; in patients with aortic aneurysm or residual COA, the frequency of CMR/CT angiography would depend on lesion severity.

- More than half of adults with repaired COA have systemic hypertension, which can occur even without hemodynamically significant residual COA.<sup>28</sup> Hypertension underpins the cardiovascular remodeling that ultimately leads to cardiovascular morbidity and mortality in this population.<sup>6</sup> LV pressure overload, resulting from the anatomic and physiological lesions of COA, leads to LV hypertrophy (cardiomyocyte hyperplasia); a normal physiological response is necessary for maintaining wall stress.<sup>6</sup> However, chronic LV pressure overload ultimately leads to myocardial ischemia with replacement fibrosis, manifesting clinically as impaired LV chamber relaxation and compliance (LV diastolic dysfunction) and impaired LV contractility.<sup>19,20,29,30</sup> Those maladaptive changes would eventually lead to left atrial dysfunction.<sup>24,30</sup> These pathophysiological changes are responsible for heart failure (mostly, heart failure with preserved ejection fraction) and atrial fibrillation in this population.<sup>26</sup> Routine blood pressure measurement is

therefore a critical component of cardiovascular care in patients with COA.<sup>5</sup> Blood pressure should be measured in all 4 extremities at the time of initial evaluation and then measured in the right arm/leg during routine evaluation to screen for hemodynamically significant residual COA.<sup>5</sup> Blood pressure should preferably be measured in the right arm (except in patients with aberrant origin of right subclavian artery) at every clinical encounter, to screen for hypertension or monitor response to antihypertensive therapy.

- Blood pressure measurement at rest (office blood pressure and home blood pressure) is the baseline screening test for hypertension, but it can sometimes miss hypertension in adults with COA.<sup>6-9</sup> Periodic ambulatory blood pressure is reasonable for diagnosis and monitoring of hypertension.<sup>6-9</sup> Ambulatory measurement also detects isolated nocturnal hypertension (absence of nocturnal dipping), a marker of vascular dysfunction and future cardiovascular events.<sup>8</sup>
- CPET assesses aerobic capacity, blood pressure response to exercise, and screening for exercise-induced arrhythmias and myocardial ischemia.<sup>10,11</sup> Exercise-induced hypertension, generally defined as systolic blood pressure at peak exercise >210 mm Hg in males and >190 mm Hg in females, is common in adults with COA.<sup>10,11</sup> Exercise-induced hypertension is associated with LV hypertrophy and higher risk for cardiovascular events, independent of resting blood pressure and other clinical characteristics.<sup>10,11</sup> No consensus exists on whether to initiate antihypertensive therapy in patients with exercise-induced hypertension who have normal resting and ambulatory blood pressures. However, blood pressure response to exercise can be used to guide titration of antihypertensive therapy in patients with a known diagnosis of hypertension.<sup>10,11</sup> In patients with COA and hypertension who already use antihypertensive therapy, exercise testing is reasonable every 5 years to assess adequacy of blood pressure control.
- Premature coronary artery disease is common in adults with COA, who have a higher incidence of myocardial infarction at a younger age than patients without COA.<sup>12</sup> The etiology of premature coronary artery disease in patients with COA is multifactorial; it is attributable to those patients' high prevalence of atherosclerotic cardiovascular disease risk factors (hypertension, hyperlipidemia, and type 2 diabetes) and, possibly, to an inherent vascular dysfunction that increases the predisposition for coronary artery disease.<sup>31</sup> Data are limited to guide screening for suspected coronary artery disease in this population, but

**TABLE 25** Features Suggestive of Hemodynamic Significance in Coarctation of the Aorta

Diagnostic Test	Index	Findings
Upper-to-lower extremity systolic blood pressure gradient	Systolic blood pressure	>20 mm Hg
Transthoracic echocardiography	Doppler mean gradient	>20 mm Hg*†
	Corrected COA MIG	>20 mm Hg*†
	Doppler profile	Diastolic tail in the descending aorta and diastolic forward flow in abdominal aorta
Cardiac catheterization	COA peak-to-peak gradient	>20 mm Hg*
MRA/CTA	Aortic isthmus ratio	<0.5-0.7
	Angiogram	Collateral arteries

\*Gradients may be lower in the context of LV dysfunction, severe aortic stenosis, or extensive collateral arteries. Of the Doppler-derived COA gradients, COA mean gradient provides the best approximation for catheterization-derived peak-to-peak gradient. Although corrected and uncorrected maximum instantaneous gradient both have similar correlations with catheterization-derived peak-to-peak gradient, the threshold to detect peak-to-peak gradient >20 mm Hg is different for both indices.<sup>45</sup> †In repaired aortic coarctation, Doppler gradients may be elevated, even without narrowing, because of poor arterial compliance and pressure recovery.

COA indicates coarctation of the aorta; CTA, computed tomography angiography; MIG, maximum instantaneous gradient; and MRA, magnetic resonance angiography.

coronary artery disease should be considered when assessing a patient with angina and exertional dyspnea.<sup>12</sup>

- Adults with COA may be at elevated risk for developing intracranial aneurysms, although the literature supporting this association remains controversial.<sup>32,33</sup> Studies of older patients with COA and a higher prevalence of hypertension showed a higher prevalence of intracranial aneurysm (compared with a general population of similar age), in contrast to studies of younger patients with COA that showed no association between COA and intracranial aneurysms.<sup>34,35</sup> The limited available data suggest that most of the intracranial aneurysms identified in patients with COA are generally small and remain stable over time, with low risk for rupture.<sup>33</sup> The role of routine screening for intracranial aneurysm in this population therefore remains unclear. However, performing baseline screening for intracranial aneurysm using brain MR or CT angiography may be considered in adults with COA.<sup>33</sup>
- Surgical or transcatheter COA repair, by an operator with ACHD expertise, is recommended for hemodynamically significant native or recurrent

COA.<sup>5,14,28,36-40</sup> Hemodynamically significant COA can be assessed by physiological severity (systolic blood pressure or COA pressure gradient) or anatomic severity (aortic isthmus ratio derived from CMR/CT angiography) (Table 25).<sup>15</sup> Aortic isthmus ratio is the ratio of the aortic isthmus (the smallest COA diameter) to the descending aorta at the level of the diaphragm. Although expert consensus generally has an aortic isthmus ratio <0.5 as the threshold for hemodynamic (anatomic) significance, recent empirical data suggest that a ratio <0.7 may be optimal for recommending COA repair, as this threshold provides the highest likelihood of postintervention regression of LV hypertrophy and normalization of LV function.<sup>41</sup> Anatomic severity for determining COA severity can also be used in clinical settings, when COA gradient may underestimate COA severity (eg, in patients with severe LV systolic dysfunction, severe aortic stenosis, or extensive collaterals). Surgical COA repair or transcatheter COA stent therapy provides similar immediate hemodynamic results (defined by postintervention residual COA gradient).<sup>5,14,28,36-39</sup> Long-term outcome studies are limited but suggest a higher risk for reintervention (due to stent fracture, restenosis, and aneurysm/pseudoaneurysms) and less-complete LV reverse remodeling in patients who received transcatheter COA stent therapy, compared with surgery. Therapy should be individualized according to the thoracic aorta anatomy, procedural risk, and institutional expertise.<sup>42,43</sup> COA repair should be performed by cardiovascular surgeons or interventionalists with expertise in managing congenital heart disease.

- Systemic hypertension is common in adults with COA and, once detected, should be treated aggressively.<sup>5</sup> Given the high prevalence of other arteriosclerotic cardiovascular disease risk factors in the COA population, the target systolic blood pressure should be <130 mm Hg. Resting blood pressure (office or home monitoring) can underestimate systolic blood pressure and lead to undertreatment. Ambulatory blood pressure and exercise testing may be considered for monitoring adequacy of blood pressure control, as on-treatment systolic blood pressure correlates directly with outcomes such as LV hypertrophy, LV dysfunction, and cardiovascular events.<sup>11,16,17</sup>

### 4.3. Right-Sided Lesions

#### 4.3.1. Ebstein Anomaly

**Recommendations for Ebstein Anomaly**  
Referenced studies that support recommendations are summarized in the [Evidence Table](#).

COR	LOE	RECOMMENDATIONS
<b>Diagnostic</b>		
1	B-NR	1. In adults with Ebstein anomaly, an electrophysiological study is recommended for patients with symptomatic arrhythmia or asymptomatic ventricular preexcitation to assess for substrates for ablation, including multiple or high-risk accessory pathways. <sup>1-3</sup>
2a	B-NR	2. In adults with Ebstein anomaly, CMR imaging can be useful to determine anatomy, RV dimensions, and systolic function to guide surgical planning and management. <sup>4-8</sup>
2a	B-NR	3. In adults with Ebstein anomaly, electrophysiological study (and catheter ablation, if needed) can be useful before tricuspid valve surgery to improve clinical outcomes. <sup>9,10</sup>
2a	C-LD	4. In adults with Ebstein anomaly, if transthoracic echocardiography is inadequate to guide surgical planning, transesophageal echocardiography can be beneficial to characterize tricuspid valve morphology and function. <sup>11</sup>
2b	B-NR	5. In adults with Ebstein anomaly and severe RV dysfunction in whom there is concern that the RV will not support the entire stroke volume, preoperative diagnostic cardiac catheterization may be considered to assess candidacy for a bidirectional superior cavopulmonary (Glenn) anastomosis. <sup>12-14</sup>
<b>Therapeutic</b>		
1	B-NR	6. In adults with Ebstein anomaly and at least moderate tricuspid regurgitation in the presence of heart failure, worsening exercise capacity, or progressive RV systolic dysfunction, surgical intervention is recommended to restore valve function and augment cardiac output. <sup>8,15-18</sup>

#### Continued

COR	LOE	RECOMMENDATIONS
1	B-NR	7. In adults with Ebstein anomaly and high-risk accessory pathway conduction or multiple accessory pathways, catheter ablation is recommended to reduce the risk for SCD. <sup>1,2,19</sup>
2a	B-NR	8. In asymptomatic adults with Ebstein anomaly and at least moderate tricuspid regurgitation in the presence of progressive RV enlargement, systemic desaturation from a right-to-left atrial shunt, recurrent arrhythmias, and/or paradoxical embolism, surgical intervention can be beneficial to improve clinical outcomes. <sup>17,20</sup>
2b	B-NR	9. In adults with Ebstein anomaly and severe RV dysfunction in whom there is concern that the RV will not tolerate supporting the entire stroke volume, a bidirectional superior cavopulmonary (Glenn) anastomosis at the time of tricuspid valve surgery may be considered in carefully selected individuals to improve cardiac output through ventricular unloading. <sup>12-14,20</sup>
2b	C-LD	10. In adults with Ebstein anomaly who have an ASD/patent foramen ovale, and cyanosis or paradoxical embolism, isolated closure may be considered after hemodynamic assessment to improve clinical outcomes. <sup>21</sup>

#### Synopsis

Ebstein anomaly, an uncommon congenital heart defect, occurs in about 1 in 1,000 live births in contemporary series.<sup>22</sup> Although Ebstein anomaly is classically considered a malformation of the tricuspid valve, the contemporary approach is to recognize that there is an inherent RV cardiomyopathy that may also extend to the left ventricle.<sup>23</sup> The anomaly can occur with other associated defects, including ASD, VSD, and pulmonary stenosis. Although often considered within the spectrum of normal, a patent foramen ovale may have significant impact on physiology in the context of Ebstein anomaly. Accessory pathways and arrhythmias are relatively common. Patient surveillance and management varies depending on patient age, severity of the lesion, and associated abnormalities, including heart failure,

*continued in the next column*

cyanosis, and arrhythmias. Surveillance includes multi-modality imaging (to assess valve morphology, right heart size, RV systolic function, and presence of an atrial level shunt), rhythm assessment, pulse oximetry, and stress testing. Treatments can include surgical intervention and catheter-based structural and electrophysiological interventions when indicated.

See **Table 26** for routine testing and follow-up intervals. Considerations pertaining to management of an Ebsteinoid valve in the setting of CCTGA are distinct and are not discussed here.

**Recommendation-Specific Supportive Text**

1. Approximately one-third of adults with Ebstein anomaly and ventricular preexcitation have multiple accessory pathways, associated with a high risk for SCD.<sup>2</sup> Adults with Ebstein anomaly also have a high prevalence of atrial tachyarrhythmias.<sup>1,24,25</sup> In the setting of ventricular preexcitation, atrial tachyarrhythmias may expose the patient to a higher risk for lethal ventricular arrhythmias. Although most symptomatic arrhythmias are atrial in adults with Ebstein anomaly,<sup>26</sup> a diagnostic electrophysiology study with therapeutic catheter ablation, if feasible, is a reasonable option in selected patients with symptomatic ventricular arrhythmias.<sup>9</sup> A retrospective study of children and young adults with Wolff-Parkinson-White syndrome diagnosed by electrophysiology study demonstrated the lack of preceding symptoms or presence of high-risk markers before the occurrence of a life-threatening event in a substantial number of patients (a life-threatening event was the sentinel event in 65% of this population); in this study, Ebstein anomaly was the strongest independent predictor of a life-threatening event on multivariate analysis (odds ratio, 4.1; 95% CI, 1.1-15.3;  $P=0.035$ ), suggesting that a proactive strategy should be considered in asymptomatic patients with Ebstein anomaly and known preexcitation.<sup>3</sup> A Pediatric and Congenital Electrophysiology Society/Heart Rhythm Society expert consensus document provides additional information on managing arrhythmias in patients with Ebstein anomaly.<sup>27</sup>
2. Comprehensive characterization of the anatomy and size of the right atrium and right ventricle in Ebstein anomaly is often difficult using echocardiography alone, particularly in adults. Data obtained from CMR imaging can inform clinical care and interventional planning because MR features correlate well with intraoperative findings.<sup>4</sup> Emerging data suggest that CMR measures can be useful for risk stratification<sup>6</sup> and to identify the extent of reverse remodeling after surgical repair. A baseline CMR study is recommended at the time of transfer to adult care; anatomic and

**TABLE 26 Ebstein Anomaly: Routine Follow-Up and Testing Intervals**

Type of Follow-Up or Testing	Physiological Stage A* (mo)	Physiological Stage B* (mo)	Physiological Stage C* (mo)	Physiological Stage D* (mo)
Outpatient ACHD cardiologist	12-24	12	6-12	3-6
Electrocardiogram	12-24	12	12	12
Transthoracic echocardiogram†	12-24	12-24	12	12

For recommendations about timing of CMR imaging, see [Section 4.3.1](#) supportive text for recommendation #2. Modified with permission from Stout et al.<sup>30</sup> Copyright 2018 American Heart Association, Inc. and American College of Cardiology Foundation.

\*See [Section 2.2](#) for details on the ACHD anatomic and physiological classification system.  
 †Routine transthoracic echocardiogram may be unnecessary in a year when CMR imaging is performed, unless clinical indications warrant otherwise.

ACHD indicates adult congenital heart disease; and CMR, cardiovascular magnetic resonance.

- physiological findings should guide the frequency of subsequent, periodic follow-up studies. Surveillance CMR imaging can be considered at 36- to 60-month intervals in stable patients who do not meet criteria for intervention; 12- to 24-month intervals may be appropriate in patients with moderate or severe tricuspid regurgitation and/or RV systolic dysfunction who may benefit from intervention. Although precise thresholds for intervention in patients with Ebstein anomaly have not been delineated, CMR can precisely define disease severity and interval change. Cardiac CT may be used if CMR is not feasible, although CT is not typically selected for routine surveillance given the inherent potential risks from radiation exposure.<sup>4,11</sup>
3. Concealed accessory pathways are common in Ebstein anomaly and may coexist with manifest accessory pathways. In addition, preexcitation may be present but difficult to appreciate on the surface electrocardiogram. Tricuspid valve surgery can hinder trans-catheter access to right-sided accessory pathways, the cavo-tricuspid isthmus, the slow pathway in atrio-ventricular node reentry, and ventricular tachycardia substrates within atrialized RV tissue, such that it may be reasonable to assess for arrhythmia substrates by diagnostic electrophysiology study and, if identified, proceed with catheter ablation before surgery.<sup>9</sup> Routine electrophysiological testing before surgery has been associated with a high diagnostic yield, effective catheter ablation of identified arrhythmias, and a potential reduction in the occurrence of post-operative arrhythmias and risk for SCD.<sup>10</sup>
  4. Given inherent limitations in standard 2-dimensional transthoracic echocardiography, anatomy and function of the tricuspid valve can be more precisely defined using 3-dimensional and/or transesophageal echocardiography to provide detailed information for guiding surgical repair.
  5. Preoperative catheterization to establish hemodynamics and to assess the feasibility of applying a

bidirectional superior cavopulmonary (Glenn) shunt is especially important in older patients, particularly those with long-standing hypertension and LV hypertrophy, which can lead to diastolic dysfunction (elevated left atrial and/or LV end-diastolic pressures) and elevated pulmonary arterial pressures.<sup>12-14,20</sup> Data pertaining to bidirectional superior cavopulmonary shunts in Ebstein anomaly are primarily available for children; multidisciplinary discussion is advisable if a shunt strategy is being considered in an adult.

6. Delaying surgery until onset of symptoms or RV systolic dysfunction has been associated with poorer outcomes in patients with Ebstein anomaly.<sup>15,16</sup> Exercise capacity is relatively low in Ebstein anomaly, compared with most other forms of congenital heart disease, and CPET has been cited as a useful tool for stratifying risk and guiding clinical management.<sup>28</sup> Because Ebstein anomaly is known to extend beyond tricuspid valve disease to include a broader myopathic process, the threshold for operation may be lower than in other RV volume-loading lesions, given heightened concern about RV tolerance of a volume load in the Ebstein population.

Surgical repair to address moderate or severe tricuspid valve disease generally consists of tricuspid valve repair or replacement, selective plication of the atrialized RV, reduction atrioplasty, arrhythmia surgery, and ASD/patent foramen ovale closure. Given the low risk from surgical intervention and the high probability of successful repair using contemporary surgical approaches, such as the Cone procedure, current practice favors earlier intervention, with some experts advocating for proactive intervention in cases of severe tricuspid regurgitation or progressive RV enlargement, even before clinical symptoms or signs appear.<sup>29</sup> Surgery may improve symptoms and functional ability (as measured on exercise testing) and may prevent or delay the worsening of symptoms.<sup>8,17,18</sup>

Although valve repair is the first-line surgical strategy for patients with Ebstein anomaly and suitable anatomy, prosthetic tricuspid valve implantation is preferable in some patients. Given the inevitability of prosthetic valve deterioration over time, valve-in-valve catheter intervention may be considered as an alternative to surgery, to restore valve function. In rare cases, surgical risk from tricuspid valve intervention would be considered to be prohibitively high, and cardiac transplantation should be considered.

7. Adults with Ebstein anomaly and ventricular pre-excitation often have multiple accessory pathways, which are associated with a higher risk for SCD, and generally can undergo ablation successfully.<sup>1,2,19</sup> Surgical interruption of accessory pathways is largely reserved for patients in whom multiple attempts at catheter ablation have not succeeded. High-risk pathways can allow rapid conduction of electrical impulses from the atria to the ventricles and, therefore, could provoke ventricular arrhythmias and SCD in the setting of atrial arrhythmias. Definition and discussion of high-risk pathways can be found in a previously published consensus statement.<sup>27</sup>
8. Systemic desaturation and arrhythmias are frequently signs of worsening hemodynamics, progressive tricuspid regurgitation, or worsening RV function.<sup>17,20</sup> In addition to surgery on the tricuspid valve (to preserve ventricular function and restore ventricular size), closure of the ASD or stretched patent foramen ovale and arrhythmia surgery can be beneficial.<sup>8</sup> Although an uncommon occurrence, refractory arrhythmias may be an indication for surgery. When arrhythmia surgery is required, it typically involves a modified right-atrial Maze procedure. In the presence of atrial fibrillation, adding a left-atrial Cox Maze III procedure can reduce the risk for recurrent atrial fibrillation.
9. The insertion of a bidirectional cavopulmonary (Glenn) shunt is more common in children than adults. In adults, this strategy is usually reserved for patients with severe RV dysfunction given the concern that the RV will not tolerate supporting the entire stroke volume. Hemodynamic factors (including LV systolic function and intracardiac pressures) require careful review if contemplating surgical intervention, and the decision to proceed with Glenn shunt insertion in adults is typically made with the input of multidisciplinary team members. Given the rarity and complexity of this procedure in adults, surgery should only be carried out in expert centers.<sup>12,14</sup>
10. Isolated closure of an ASD/patent foramen ovale (typically by percutaneous device) can be considered to address cyanosis (oxygen saturation <90% at rest or with exertion) or paradoxical embolism. However, careful review of hemodynamics is essential to ensure that intervention does not substantially increase right atrial pressures or compromise cardiac output.<sup>21</sup>

### 4.3.2. Valvular Pulmonary Stenosis

**Recommendations for Valvular Pulmonary Stenosis**  
 Referenced studies that support recommendations are summarized in the [Evidence Table](#).

COR	LOE	RECOMMENDATIONS
1	B-NR	1. In symptomatic adults with moderate or severe valvular pulmonary stenosis who have favorable valve anatomy, balloon valvuloplasty is recommended to improve symptoms. <sup>1,2</sup>
1	B-NR	2. In symptomatic adults with moderate or severe valvular pulmonary stenosis who are ineligible for or have had suboptimal results after balloon valvuloplasty, pulmonary valve replacement is recommended to improve symptoms. <sup>3,4</sup>
1	C-LD	3. In asymptomatic adults with moderate or severe valvular pulmonary stenosis and at least moderate tricuspid regurgitation or any RV dysfunction, pulmonary valve intervention is recommended to reduce pressure overload and improve valvular function. <sup>5,6</sup>
2a	C-EO	4. In asymptomatic adults with severe valvular pulmonary stenosis, intervention is reasonable to reduce pressure overload and improve valvular function.

#### Synopsis

Valvular pulmonary stenosis, one of the most common congenital heart defects, is estimated to occur in about 1 in 2,000 live births worldwide.<sup>7</sup> Findings commonly associated with isolated valvular pulmonary stenosis include a dilated main PA and dysplastic valve cusps. Referral for intervention depends on the degree of obstruction, RV pressure and function, and the presence of associated symptoms. Although the first-line approach is generally percutaneous, surgery is appropriate for patients deemed to be ineligible for, or for those who have suboptimal results after, a catheterization procedure. Patients with mild native pulmonary valve stenosis have a reassuring natural history, and intervention is not usually necessary<sup>3</sup>; patients with severe pulmonary stenosis typically require intervention in childhood and have a good prognosis into adulthood<sup>1,2,8,9</sup>; and patients with moderate stenosis may have a more variable course, with some referred for catheter or surgical intervention and others managed conservatively (see [Table 27](#)).<sup>3</sup>

**TABLE 27** Severity of Right Ventricular Outflow Tract Dysfunction<sup>13</sup>

Pulmonic stenosis severity*		
Degree of stenosis	Doppler velocity and gradient across the right ventricular outflow tract	
Mild	Peak gradient, <36 mm Hg (peak velocity <3 m/s)	
Moderate	Peak gradient, 36–64 mm Hg (peak velocity 3–4 m/s)	
Severe	Peak gradient, >64 mm Hg (peak velocity >4 m/s); Mean gradient >35–40 mm Hg	
Pulmonary regurgitation severity†		
Degree of regurgitation	Regurgitation fraction and volume, as measured by CMR imaging	Echocardiographic features associated with pulmonic regurgitation
Mild	Regurgitant fraction <20%; regurgitant volume <30 mL	<ul style="list-style-type: none"> <li>■ Diastolic flow reversal at the pulmonary valve level</li> <li>■ Narrow vena contracta</li> <li>■ Flat pressure half-time</li> <li>■ Faint density of spectral Doppler signal</li> </ul>
Moderate	Regurgitant fraction 20%–40%; regurgitant volume 30–59 mL	<ul style="list-style-type: none"> <li>■ Diastolic flow reversal at the main or branch pulmonary artery level‡</li> </ul>
Severe	Regurgitant fraction >40%; regurgitant volume 60 mL <sup>13</sup>	<ul style="list-style-type: none"> <li>■ Steep pressure half-time§</li> <li>■ Low PR index  </li> <li>■ Denser signal of the spectral Doppler signal</li> <li>■ Broad vena contracta</li> </ul>

Adapted with permission from Stout et al.<sup>16</sup> Copyright 2018 American Heart Association, Inc. and American College of Cardiology Foundation.

\*Severity of pulmonary valve stenosis may be underestimated in the context of ventricular dysfunction.

†CMR, the preferred imaging methodology for quantifying PR, is used to define the degree of PR. Echocardiographic features of mild and hemodynamically significant PR also are listed.

‡Assessment may be affected by pulmonary arterial compliance.

§Pressure half-time <100 ms, corresponding to significant PR (defined as regurgitant fraction ≥20% on CMR).

||PR index (defined as duration of PR signal/total diastolic period) <0.77, corresponding to PR fraction >24.5%.<sup>13–15</sup>

CMR indicates cardiovascular magnetic resonance; and PR, pulmonary regurgitation.

Outcomes after intervention are related to patient age at intervention, valve characteristics (morphology, diameter, and gradient), and/or presence of a genetic syndrome (eg, Noonan syndrome).<sup>10</sup> See [Table 28](#) for routine testing and follow-up intervals.

#### Recommendation-Specific Supportive Text

1. In most patients with moderate or severe isolated pulmonary valve stenosis, pulmonary balloon valvuloplasty is a safe and effective intervention that reduces the transvalvular gradient and improves symptoms.<sup>1,2,8,9</sup> Patients without overt symptoms may also benefit from intervention if they demonstrate worsening objective exercise capacity or exercise-induced hypoxemia due to a right-to-left shunt. Pulmonary balloon valvuloplasty has largely supplanted surgical pulmonary valvotomy as the first-line therapy for isolated valvular pulmonary stenosis.<sup>10</sup>

**TABLE 28** Valvular Pulmonary Stenosis: Routine Follow-Up and Testing Intervals

Type of Follow-Up or Testing	Physiological Stage A* (mo)	Physiological Stage B* (mo)	Physiological Stage C* (mo)	Physiological Stage D* (mo)
Outpatient ACHD cardiologist	36-60	24	6-12	3-6
Electrocardiogram	36-60	24	12	12
Transthoracic echocardiogram	36-60	24	12	12

Adapted with permission from Stout et al.<sup>16</sup> Copyright 2018 American Heart Association, Inc. and American College of Cardiology Foundation.

\*See Section 2.2 for details on the ACHD anatomic and physiological classification system.

ACHD indicates adult congenital heart disease.

- In symptomatic patients who are ineligible for balloon valvuloplasty or have had suboptimal outcomes, surgical intervention is recommended. Surgery may also be appropriate in patients without overt symptoms who demonstrate worsening objective exercise capacity or exercise-induced hypoxemia due to a right-to-left shunt. Pulmonary valve replacement may be required in cases of marked valvular dysplasia or significant annular hypoplasia.<sup>3,4</sup> Surgical valvotomy may be adequate for patients with adequate annular size.
- Pulmonary valve intervention alone can lessen tricuspid valve regurgitation, albeit not as efficiently as direct surgical intervention on the tricuspid valve.<sup>5,6,11</sup> How well percutaneous pulmonary valve intervention ameliorates tricuspid valve insufficiency has not been directly studied in patients with isolated pulmonary valve stenosis but can be extrapolated from cohort data that include heterogeneous anatomic lesions.<sup>11</sup> RV systolic dysfunction attributable to the valve in patients with valvular pulmonary stenosis is relatively uncommon and, if detected, should prompt valvular intervention.
- Relieving a severely stenotic pulmonary valve in an asymptomatic patient reduces the RV pressure and the likelihood of potential sequelae.<sup>12</sup> As in symptomatic patients, the procedure can be performed by surgery or interventional catheterization with low risks for morbidity and mortality. If intervention is deferred, careful follow-up to evaluate for symptoms, decline in exercise capacity, worsening RV function, or development of cyanosis is important and may prompt reconsideration of intervention.

#### 4.3.2.1. Isolated Pulmonary Regurgitation After Repair of Pulmonary Stenosis

Recommendations for Isolated Pulmonary Regurgitation After Repair of Pulmonary Stenosis Referenced studies that support recommendations are summarized in the Evidence Table.

COR	LOE	RECOMMENDATIONS
<b>Diagnostic</b>		
1	B-NR	1. In adults with moderate or greater pulmonary regurgitation resulting from treated isolated valvular pulmonary stenosis, CMR imaging is recommended to establish anatomy, quantify the degree of regurgitation, and measure RV volumes and systolic function. <sup>1-4</sup>
<b>Therapeutic</b>		
1	B-NR	2. In patients with symptomatic moderate or greater pulmonary regurgitation resulting from treated isolated valvular pulmonary stenosis, pulmonary valve replacement is recommended to improve symptoms. <sup>3-6</sup>
2a	C-LD	3. In asymptomatic patients with moderate or greater pulmonary regurgitation resulting from treatment of isolated pulmonary stenosis with RV systolic dysfunction, pulmonary valve replacement is reasonable to restore valve function and preserve RV systolic function. <sup>3,4</sup>
2b	C-LD	4. In asymptomatic patients who have moderate or greater pulmonary regurgitation resulting from treatment of isolated pulmonary stenosis and at least moderate tricuspid regurgitation and/or progressive RV dilation or progressive decline in exercise capacity,* pulmonary valve replacement may be reasonable to restore valve function, ameliorate RV size, and preserve RV systolic function. <sup>3,4,7-9</sup>

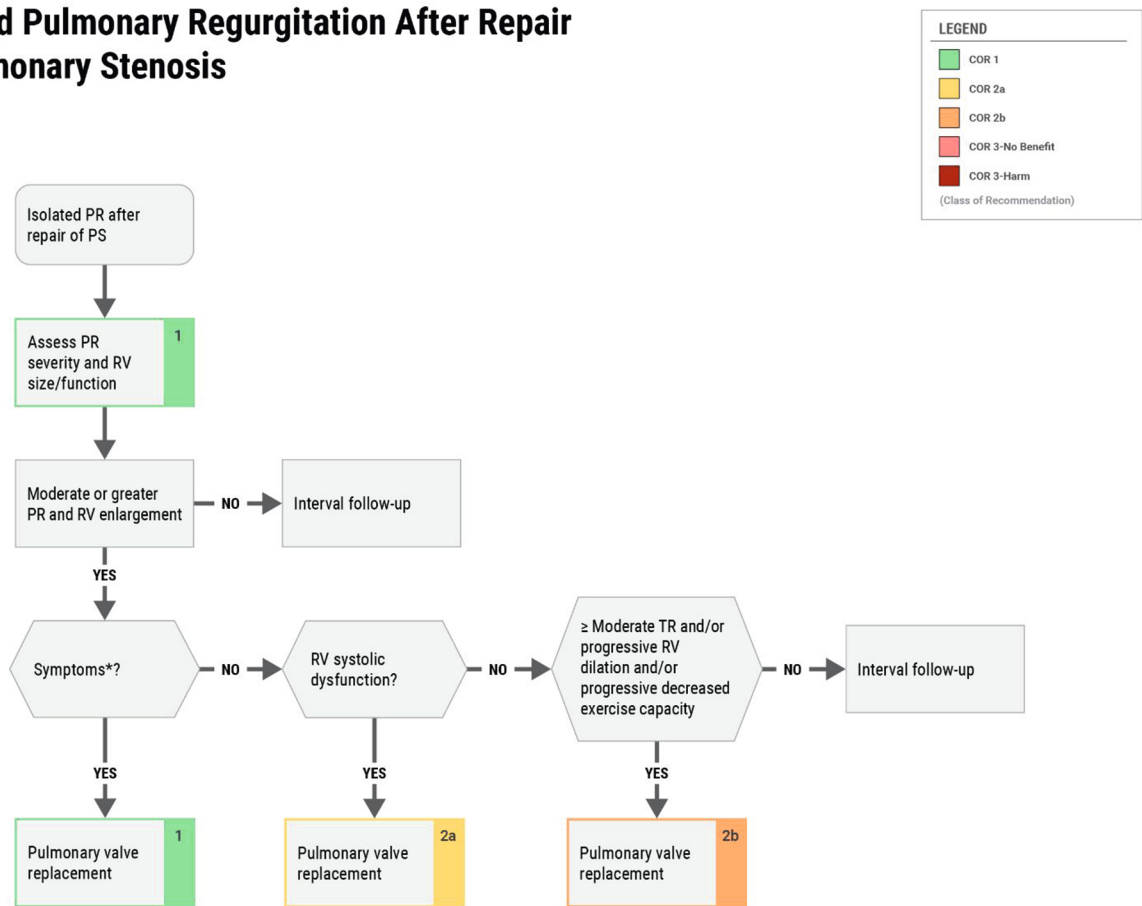
\*See Figure 5.

#### Synopsis

Although many patients with pulmonary valve stenosis do not require intervention, some have pulmonary stenosis that is severe enough to warrant intervention, often in infancy or childhood. Pulmonary stenosis can be

**FIGURE 5** Isolated Pulmonary Regurgitation After Repair of Pulmonary Stenosis

## Isolated Pulmonary Regurgitation After Repair of Pulmonary Stenosis



2025 Adults With Congenital Heart Disease  
 © 2025 by the American College of Cardiology Foundation and the American Heart Association, Inc.

For routine follow-up and testing intervals, see [Table 29](#). \*Symptoms may include dyspnea, chest pain, and/or exercise intolerance attributable to PR or otherwise unexplained. PR indicates pulmonary regurgitation; PS, pulmonary stenosis; RV, right ventricular; and TR, tricuspid regurgitation. Modified with permission from Stout et al.<sup>14</sup> Copyright 2018 American Heart Association, Inc. and American College of Cardiology Foundation.

alleviated either by surgical valvotomy or balloon valvuloplasty, which may result in hemodynamically important pulmonary regurgitation. Chronic pulmonary regurgitation can result in development of symptoms, and in RV enlargement and/or dysfunction, warranting pulmonary valve replacement. Although early reoperation is typically performed for residual stenosis, late intervention is commonly performed for significant regurgitation.<sup>10</sup> Transcatheter pulmonary valve implantation is an emerging alternative to surgical pulmonary valve replacement (although patients diagnosed with isolated valvular pulmonary stenosis make up a minority of patients with successful percutaneous valve

**TABLE 29** Isolated Pulmonary Regurgitation After Repair of Pulmonary Stenosis: Routine Follow-Up and Testing Intervals

Type of Follow-Up or Testing	Physiological Stage A* (mo)	Physiological Stage B* (mo)	Physiological Stage C* (mo)	Physiological Stage D* (mo)
Outpatient ACHD cardiologist	36-60	24	6-12	3-6
Electrocardiogram	36-60	24	12	12
Transthoracic echocardiogram	36-60	24	12	12

For recommendations about timing of CMR imaging, see [Section 4.3.2.1](#) supportive text for recommendation #1. Modified with permission from Stout et al.<sup>14</sup> Copyright 2018 American Heart Association, Inc. and American College of Cardiology Foundation.

\*See [Section 2.2](#) for details on the ACHD anatomic and physiological classification system.

ACHD indicates adult congenital heart disease; and CMR, cardiovascular magnetic resonance.

implantations in the published literature).<sup>5,6,11,12</sup> Isolated congenital pulmonary regurgitation is rare and, given the lack of focused study of this subset of patients, the recommendations above can likely be extended to that population.

### Recommendation-Specific Supportive Text

1. CMR, useful for establishing right heart anatomy, is the imaging modality of choice for quantifying pulmonary regurgitation and measuring ventricular size and systolic function. Although CMR can estimate the degree of pulmonary stenosis, echocardiography is generally preferred for assessing valve gradients.<sup>13</sup> In stable patients with moderate or severe pulmonary regurgitation, surveillance CMR imaging can be performed at 24- to 36-month intervals to monitor disease severity and interval changes in CMR measurements; however, 12- to 24-month intervals may be more appropriate in patients being considered for intervention.
2. Although data are insufficient to define a threshold of RV dilation or RV dysfunction to suggest appropriate timing for pulmonary valve replacement in this population, directly extrapolating from data in TOF cohorts is likely to be inappropriate.<sup>1</sup> Compared with patients with repaired TOF, patients with isolated pulmonary regurgitation after repair of pulmonary stenosis appear to have fewer adverse cardiovascular outcomes, to exhibit a greater extent of reverse remodeling after intervention, and to have less benefit from earlier (more proactive) timing of valve intervention.<sup>3,4</sup> Symptoms of heart failure attributable to pulmonary valve insufficiency should prompt intervention.
3. How pulmonary valve intervention affects clinical outcomes in asymptomatic patients with pulmonary regurgitation after repair of pulmonary stenosis is unknown. The thresholds for intervention are likely to be higher than for TOF. Notably, RV systolic dysfunction is relatively uncommon in patients with isolated pulmonary regurgitation (unlike in patients with TOF) and, when diagnosed, should prompt intervention.<sup>3,4</sup>
4. Thresholds for intervention based on RV volumes have not been well elucidated in patients with isolated pulmonary regurgitation. Favorable reverse remodeling can be expected to occur after valve competency is restored, but the clinical implications of persistent volume overload have not been adequately studied.<sup>3,4</sup> The decision to proceed with intervention should be balanced against the risk from the procedure itself, the need for future reintervention, and the potential for complications such as infective endocarditis.<sup>3,4,7-9</sup>

### 4.3.3. Management of Double-Chambered Right Ventricle

**Recommendations for the Management of DCRV**  
Referenced studies that support recommendations are summarized in the [Evidence Table](#).

COR	LOE	RECOMMENDATIONS
<b>Diagnostic</b>		
2a	C-LD	1. In adults with RV dysfunction or symptoms attributed to DCRV, cardiac catheterization is reasonable to characterize anatomy and severity. <sup>1-3</sup>
2a	C-EO	2. In adults with DCRV and moderate or greater RVOT obstruction, diagnostic assessment with CMR (or, if contraindicated, cardiac CT) can be beneficial to characterize the anatomy.* <sup>4</sup>
<b>Therapeutic</b>		
1	C-LD	3. In adults with DCRV, moderate or greater RVOT obstruction, and otherwise unexplained symptoms of heart failure, cyanosis, or exercise limitation, surgical repair is recommended to improve symptoms. <sup>5-7</sup>
2a	C-LD	4. In asymptomatic adults with DCRV and severe RVOT obstruction, surgical repair is reasonable to prevent symptoms and adverse RV remodeling. <sup>1,6,7</sup>

\*Table 27 delineates levels of severity of RVOT obstruction and their related echocardiographic parameters.

### Synopsis

DCRV is characterized by hypertrophied muscle bundles that develop within the RV cavity, creating RVOT obstruction.<sup>3,8,9</sup> It is commonly associated with a VSD that is often restrictive, resulting in a high-pressure inlet and a low-pressure outlet RV outflow chamber, with an intraventricular pressure gradient. Although DCRV is uncommonly discovered in adults, it can develop in the years after an earlier VSD repair.<sup>8,10</sup> Transthoracic echocardiography can miss DCRV if the defect is not sought specifically, and alternative imaging or cardiac catheterization is often required to confirm DCRV and its hemodynamic impact.<sup>2</sup> Adults with DCRV often are misdiagnosed because evaluating this complex condition requires expertise in noninvasive and invasive congenital heart disease. Diagnostic criteria for DCRV include echocardiographic or angiographic evidence of mid-RV obstruction, a systolic pressure gradient between the

proximal RV chamber (inflow) and RVOT caused by muscle bundles, and the absence of infundibular hypoplasia.<sup>11,12</sup>

Subpulmonary stenosis may occur in anatomic substrates other than DCRV,<sup>13</sup> including pre- and post-operative subpulmonary stenosis associated with other congenital heart defects. **Table 30** lists routine testing and follow-up intervals for patients with each physiological stage of DCRV.

**Recommendation-Specific Supportive Text**

1. Although patients with DCRV may be asymptomatic despite a moderate or severe degree of RVOT obstruction, symptoms of dyspnea on exertion, diminished exercise tolerance, chest pain, syncope/dizziness, and arrhythmias have been described.<sup>1,2</sup> Given the challenges of diagnostic assessment of DCRV in adults,<sup>2</sup> invasive evaluation is often necessary to assess anatomy and degree of obstruction before surgery.<sup>1,2,4,14</sup>
2. Diagnostic evaluation for DCRV typically includes echocardiography,<sup>2</sup> although it may not be conclusive. In addition, the presence of a VSD may contaminate the Doppler jet.<sup>1</sup> Cross-sectional imaging (CMR or cardiac CT) may be needed to further delineate the anatomy before intervention.<sup>14</sup> Published appropriate use criteria for multimodality imaging during follow-up of patients with congenital heart disease do not include specific recommendations for DCRV.<sup>15</sup> However, they refer to the risk for developing DCRV in patients with VSD as 1 reason for specific diagnostic testing. CMR and cardiac CT are characterized as “may be appropriate” during preoperative evaluation and pre- or postrepair, if a change in clinical status or new concerning signs or symptoms emerge.
3. Surgery typically involves resection of obstructive muscle bundles via transatrial, transventricular, transpulmonary, or a variable combination of approaches.<sup>5-7,12,16</sup> Closure of VSD, if present, is completed at the time. Right ventriculotomy is avoided, when possible, to minimize long-term risks for ventricular arrhythmias and dysfunction. Post-operative outcomes are excellent, and recurrence is rare.<sup>1,5,7,12,16</sup> VSD is often present and may communicate with the higher- or lower-pressure chamber in the right ventricle, with resulting differences in shunt direction and flow characteristics.<sup>2,9</sup> When the pressure gradient through the right ventricle is severely elevated (echocardiographic maximal instantaneous gradient >64 mm Hg) or when associated with supra-systemic RV pressure, the VSD may be associated with

**TABLE 30 Double-Chambered Right Ventricle: Routine Follow-Up and Testing Intervals**

Type of Follow-Up or Testing	Physiological Stage A* (mo)	Physiological Stage B* (mo)	Physiological Stage C* (mo)	Physiological Stage D* (mo)
Outpatient ACHD cardiologist	24-36	24	6-12	3-6
Electrocardiogram	24-36	24	12	12
Transthoracic echocardiogram	24-36	24	12	6-12

For recommendations about timing of CMR and CT imaging, see [Section 4.3.3](#) supportive text for recommendation #2. Modified with permission from Stout et al.<sup>17</sup> Copyright 2018 American Heart Association, Inc. and American College of Cardiology Foundation. \*See [Section 2.2](#) for details on the ACHD anatomic and physiological classification system. ACHD indicates adult congenital heart disease; CMR, cardiovascular magnetic resonance; and CT, computed tomography.

- right-to-left shunting (if proximal to the obstruction) or associated with left-to-right shunting (if distal).
- 4. Given the progressive nature of obstruction and known symptom development over time,<sup>5,8</sup> asymptomatic patients with severe DCRV can benefit from surgical repair of both the VSD and the RVOT obstruction.

**4.3.4. Isolated Branch Pulmonary Artery Stenosis**

**Recommendations for Isolated Branch Pulmonary Artery Stenosis**  
 Referenced studies that support recommendations are summarized in the [Evidence Table](#).

COR	LOE	RECOMMENDATIONS
<b>Diagnostic</b>		
1	B-NR	1. In adults with peripheral or branch PA stenosis, echocardiography and cross-sectional imaging (cardiac CT or CMR) are recommended to evaluate RV pressure and systolic function, degree of tricuspid regurgitation, and degree and location of stenosis. <sup>1</sup>
<b>Therapeutic</b>		
1	B-NR	2. In adults with symptoms related to peripheral or branch PA stenosis, pulmonary branch balloon angioplasty and/or stent implantation is recommended to improve hemodynamics and symptoms. <sup>2,3</sup>

*Continued on the next page*

Continued		
COR	LOE	RECOMMENDATIONS
2a	B-NR	3. In asymptomatic adults with isolated peripheral PA stenosis* and any of the following—RV hypertension that is more than half the systemic pressure, RV dysfunction, moderate or greater degree of tricuspid regurgitation, or worsening exercise performance—pulmonary branch balloon angioplasty and stent implantation can be useful to improve hemodynamics, reduce tricuspid regurgitation, and improve pulmonary blood flow. <sup>2-5</sup>

\*Angiographic narrowing and/or asymmetric pulmonary blood flow with a reduction >10% in expected perfusion to the affected lung.

**Synopsis**

Congenital pulmonary branch and peripheral PA stenosis can be isolated, occur as part of a constellation of RVOT obstruction, or be identified postoperatively (eg, after arterial switch with the Lecompte maneuver). Peripheral PA stenosis also can be associated with a syndrome (eg, Noonan, Alagille, Williams, maternal rubella exposure). In patients with suspected pulmonary hypertension and RV hypertension, peripheral PA stenosis may be the underlying cause.

Transthoracic echocardiography is useful in identifying proximal peripheral PA stenosis, obtaining RV pressure, and evaluating cardiac function, but it does not adequately image the peripheral PAs. Further cross-sectional imaging (eg, CMR or cardiac CT) can better visualize the branch PA anatomy, as well as any hypoplasia or obstruction. In addition, CMR with pulmonary

perfusion testing can quantify relative pulmonary blood flow.

In isolated branch PA stenosis, intervention decisions are typically based on symptoms, such as shortness of breath, as well as on elevated PA pressure and RV filling pressure, distribution of relative pulmonary blood flow, RV function, and systolic pressure. Intervention with balloon angioplasty or stenting can improve pulmonary blood flow and reduce RV hypertension. After intervention, adults with proximal peripheral PA stenosis need ongoing surveillance that includes echocardiography and cross-sectional imaging, as indicated (see **Table 31**).

**Recommendation-Specific Supportive Text**

1. Echocardiographic imaging is beneficial in quantifying the RV pressure, but cross-sectional imaging with CT<sup>6,7</sup> or CMR<sup>1</sup> is recommended to identify the location and degree of peripheral pulmonary stenosis and to assess the feasibility of intervention. Lung perfusion scan or CMR with pulmonary perfusion testing can quantify relative pulmonary blood flow.
2. In adults with symptoms related to peripheral or branch PA stenosis—including those with worsening exercise intolerance, signs of right heart failure, and cyanosis due to atrial level right-to-left shunting—the use of balloon angioplasty or stent implantation has been shown to improve exercise tolerance, lung perfusion, and ventilatory efficiency.<sup>2,3</sup>
3. Balloon angioplasty or stenting of a peripheral PA is safe and effective in reducing pressure gradients and improving relative pulmonary blood flow.<sup>4,8</sup> Indications for pulmonary angioplasty or stenting include symptoms attributable to the diminished pulmonary blood flow, focal narrowing, abnormal differential perfusion, and elevated RV pressure. Common indications for intervention can include symptoms, PA pressure gradient >20 to 30 mm Hg, elevation of RV pressure or proximal mean PA pressure to more than half the systemic pressure, and <35% blood flow to the affected lung.<sup>9,10</sup> The decision for intervention with PA angioplasty or stenting includes assessment of clinical symptoms, imaging, and discussion with an ACHD interventional cardiologist. Surgery (performed by a surgeon with ACHD expertise) is reserved for cases in which transcatheter intervention is not feasible,<sup>11</sup> or if in combination with other cardiac surgery. PA intervention can increase pulmonary blood flow to the affected lung and improve exercise capacity.<sup>3</sup> Restenosis has been reported, and ongoing surveillance with imaging is warranted, especially if the patient is symptomatic or has evidence of increased RV pressure

**TABLE 31** Isolated Branch Pulmonary Artery Stenosis: Routine Follow-Up and Testing Intervals

Type of Follow-Up or Testing	Physiological Stage A* (mo)	Physiological Stage B* (mo)	Physiological Stage C* (mo)	Physiological Stage D* (mo)
Outpatient ACHD cardiologist	24-36	24	6-12	3-6
Electrocardiogram	24-36	24	12	12
Transthoracic echocardiogram	24-36	24	12	12

For recommendations about timing of CT and MR angiography, see **Section 4.3.4** supportive text for recommendation #1.

Modified with permission from Stout et al.<sup>12</sup> Copyright 2018 American Heart Association, Inc. and American College of Cardiology Foundation.

\*See **Section 2.2** for details on the ACHD anatomic and physiological classification system.

ACHD indicates adult congenital heart disease; CT, computed tomography; and MR, magnetic resonance.

4.3.5. Tetralogy of Fallot

**Recommendations for Tetralogy of Fallot**  
 Referenced studies that support recommendations are summarized in the [Evidence Table](#).

COR	LOE	RECOMMENDATIONS
<b>Diagnostic</b>		
1	B-NR	1. In adults with repaired TOF, echocardiography is recommended for assessment of pulmonary and tricuspid valve dysfunction, right atrial size, ventricular size and function, residual VSDs, and estimation of RV systolic pressure to characterize residual hemodynamic sequelae. <sup>1</sup>
1	B-NR	2. In adults with repaired TOF and residual hemodynamic sequelae, CMR imaging is recommended for quantifying pulmonary valve function, ventricular size and function, and branch PA size and flow; characterizing the right and LVOT anatomy; quantifying residual shunts or aortopulmonary collateral flow; and assessing fibrosis of the ventricular myocardium. <sup>2</sup>
1	B-NR	3. In adults with repaired TOF undergoing right ventricle-to-pulmonary artery (RV-to-PA) conduit stenting or transcatheter pulmonary valve placement with a balloon-expandable platform, assessment of coronary artery compression risk is indicated to ensure absence of coronary artery compression from stent/valve placement. <sup>3</sup>
1	B-NR	4. In adults with repaired TOF and native RVOT anatomy being considered for transcatheter pulmonary valve replacement, cardiac CT is recommended to determine anatomic suitability. <sup>4,5</sup>
2a	B-NR	5. In adults with repaired TOF and moderate risk for future sustained ventricular tachycardia and/or SCD, invasive electrophysiology evaluation is reasonable to inform clinical management. <sup>6-8</sup>

*continued in the next column*

Continued		
COR	LOE	RECOMMENDATIONS
2a	C-EO	6. In adults with repaired TOF in whom adequate data cannot be obtained noninvasively in the setting of an arrhythmia, heart failure, unexplained ventricular dysfunction, suspected pulmonary hypertension, residual hemodynamic lesions, or cyanosis, cardiac catheterization with angiography is reasonable for assessing hemodynamics to direct management and therapies.
2b	C-LD	7. In adults with repaired TOF undergoing pulmonary valve placement (surgical or transcatheter), pre-procedural invasive electrophysiology evaluation with programmed ventricular stimulation and 3-dimensional mapping may be considered to identify and treat latent monomorphic ventricular tachycardia substrates. <sup>6,8-10</sup>
2b	C-LD	8. In adults with repaired TOF, noninvasive evaluation (12-lead electrocardiography, contrast-enhanced MR imaging, and/or CT angiography) may be considered to characterize ventricular tachycardia substrates. <sup>11-14</sup>
<b>Therapeutic</b>		
1	B-NR	9. In symptomatic adults with repaired TOF and moderate or greater pulmonary valve dysfunction,* pulmonary valve replacement (surgical or transcatheter) is recommended for relief of symptoms. <sup>15</sup>
2a	B-NR	10. In asymptomatic adults with repaired TOF, moderate or greater pulmonary valve dysfunction,* and at least 2 of the following—RV end-systolic volume index >80 mL/m <sup>2</sup> , RV end-diastolic volume ≥2× LV end-diastolic volume, RV ejection fraction ≤46%, LV ejection fraction ≤50%, or progressive decline in exercise capacity—pulmonary valve replacement (surgical or transcatheter) is reasonable for improving outcomes, including lowering risks for ventricular arrhythmias and death. <sup>16</sup>

*Continued on the next page*

Continued		
COR	LOE	RECOMMENDATIONS
2a	B-NR	11. In adults with repaired TOF and high risk (by clinical markers and/or multivariable score†) for SCD, placement of an ICD is reasonable to prevent SCD. <sup>17-19</sup>
2a	B-NR	12. In adults with repaired TOF and appropriate ICD therapies for monomorphic ventricular tachycardia, adjunctive catheter ablation is reasonable to reduce ventricular tachyarrhythmia burden. <sup>20,21</sup>
2a	C-LD	13. In adults with repaired TOF with moderate or greater pulmonary valve dysfunction* and progressive ventricular systolic dysfunction, pulmonary valve replacement (surgical or transcatheter) is reasonable to preserve ventricular function. <sup>22</sup>
2b	C-LD	14. In adults with repaired TOF with at least moderate pulmonary valve dysfunction* and progressive functional tricuspid regurgitation of a moderate or greater severity associated with RV dilation, pulmonary valve intervention may be reasonable to prevent worsening tricuspid valve dysfunction and RV dilation. <sup>23</sup>
2b	C-LD	15. For carefully selected patients with repaired TOF and hemodynamically tolerated monomorphic ventricular tachycardia related to a well-defined anatomical isthmus, ablation monotherapy may be considered in lieu of ICD placement at centers with ACHD electrophysiology expertise. <sup>24-26</sup>
2b	C-LD	16. In adults with repaired TOF and moderate or greater pulmonary regurgitation and ventricular tachyarrhythmia requiring treatment,‡ pulmonary valve replacement (surgical or percutaneous), in addition to electrophysiological intervention, may be considered. <sup>27,28</sup>

\*Pulmonary valve dysfunction defined as moderate PR (CMR-derived RF  $\geq$ 25%) or RVSP  $>$ 2/3 systemic pressure due to RVOT obstruction. †Refer to [Table 32](#) and [Table 33](#) for individual risk scores. ‡Antiarrhythmic classes I/III or amiodarone, catheter ablation, electrical cardioversion, defibrillation, pace termination, or ICD shock for sustained ventricular arrhythmia.

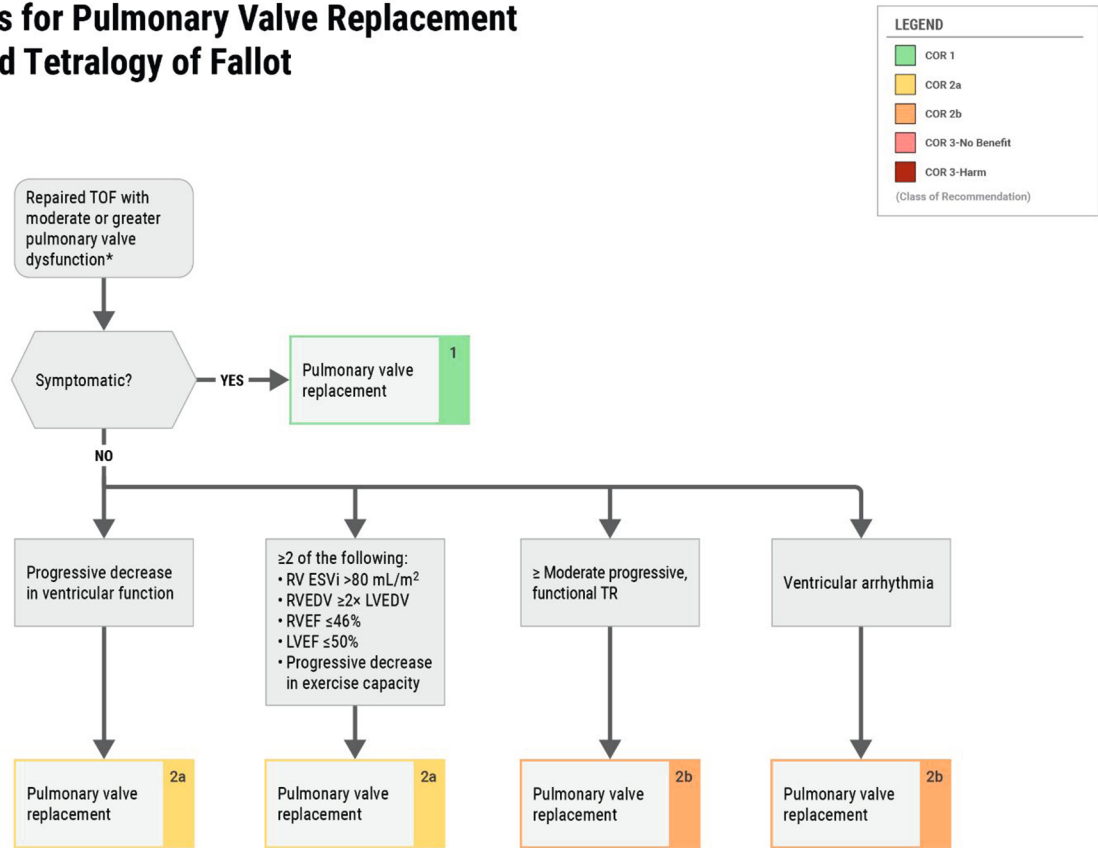
## Synopsis

TOF is one of the most common congenital heart disease conditions and requires lifetime surveillance. With advancing age, the prevalence of arrhythmias increases, resulting in electromechanical cardiomyopathy. The most common physiological sequela of TOF repair is RVOT dysfunction, manifesting as pulmonary regurgitation, pulmonary stenosis, or a combination thereof. Initial surgery may involve an infundibulotomy to resect obstructive muscle bundles and use of a transannular patch, which commonly result in large, dyskinetic, sometimes aneurysmal areas of the RV free wall, associated with fibrotic tissue or scar. Surgical strategies focus on preserving the pulmonary valve when possible with either subvalvar muscle bundle resection and relief of supralvalvar obstruction. At least 15% of patients born with TOF have pulmonary valve atresia; these patients often require a RV-to-PA conduit placement and necessitate conduit replacement as they age. Many patients with repaired TOF have residual RVOT dysfunction and branch PA stenosis. Pulmonary valve dysfunction may manifest as primary regurgitation, primary stenosis, or mixed. Moderate pulmonary regurgitation is defined as a CMR-measured regurgitant fraction of at least 25%. Moderate pulmonary stenosis is defined as an RV pressure that is at least two-thirds systemic because of RVOT obstruction. Of note, consideration is warranted for elevated RV systolic pressure in the setting of RVOT obstruction that does not reach two-thirds systemic pressure in the setting of significantly depressed RV function. Patients with significant pulmonary regurgitation often have RV dilation and may develop RV dysfunction. Much of the research in the past several decades has focused on the timing of subsequent interventions to the RVOT ([Figure 6](#)). Other hemodynamic sequelae are residual VSDs, tricuspid valve regurgitation, LV dysfunction (up to 20% of adults with TOF), and aortic root dilation. See [Table 34](#) for suggested routine testing and follow-up intervals for patients with repaired TOF.

Patients with repaired TOF are at risk for both atrial and ventricular arrhythmias. Most commonly, atrial flutter involves either a prior atriotomy, the anatomic tricuspid annulus, or a combination of the 2 substrates. Atrial flutter, and increasingly atrial fibrillation, can be definitively treated with catheter ablation. Atrial fibrillation has been associated with reduced survival in adults with repaired TOF.<sup>29</sup> Moreover, TOF is uniquely associated with sustained monomorphic ventricular tachycardia and SCD. Classically, patients experience an SCD rate of 1.5 per 1,000 patient-years.<sup>30</sup> This risk is dynamic, with a reported incidence rate of ventricular arrhythmia that is generally low during childhood and accelerated in the third and fourth decades of life.<sup>30-33</sup> The pathophysiology is complex and multifactorial, owing to variable

**FIGURE 6** Indications for Pulmonary Valve Replacement in Repaired Tetralogy of Fallot

## Indications for Pulmonary Valve Replacement in Repaired Tetralogy of Fallot



2025 Adults With Congenital Heart Disease  
 © 2025 by the American College of Cardiology Foundation and the American Heart Association, Inc.

\*Pulmonary valve dysfunction defined as moderate PR (CMR-derived RF  $\geq 25\%$ ) or RVSP  $>2/3$  systemic pressure due to RVOTO. CMR indicates cardiovascular magnetic resonance; ESVi, end-systolic volume index; LVEDV, left ventricular end-diastolic volume; LVEF, left ventricular ejection fraction; PR, pulmonary regurgitation; RF, regurgitant fraction; RV, right ventricular; RVEDV, right ventricular end-diastolic volume; RVEF, right ventricular ejection fraction; RVOTO, right ventricular outflow tract obstruction; RVSP, right ventricular systolic pressure; TOF, tetralogy of Fallot; and TR, tricuspid regurgitation. Modified with permission from Stout et al.<sup>90</sup> Copyright 2018 American Heart Association, Inc. and American College of Cardiology Foundation.

surgical scarring, suboptimal hemodynamics, and myocardial pathology that lead to electrical instability and ventricular arrhythmogenesis.<sup>11</sup> Fundamentally, ventricular tachycardia and SCD are believed to be related to evolving postsurgical residua that are superimposed on cardiomyopathy.<sup>34-36</sup> Accordingly, although sustained monomorphic ventricular tachycardia represents the index arrhythmia for most patients,<sup>19,32,37,38</sup> primary

ventricular fibrillation can also occur. Over the past decade, investigations into risk factors for SCD have informed primary-prevention ICD strategies and ablation outcomes for repaired TOF.

Of note, these specific guideline recommendations are for patients with TOF who have undergone a repair earlier in life and do not include the rare cases of adults who present with unrepaired TOF. Adults with TOF who

**TABLE 32** Established Risk Factors for Sustained Monomorphic Ventricular Tachycardia/Sudden Cardiac Death in Repaired Tetralogy of Fallot

QRS duration $\geq$ 180 ms
Moderate or greater LV or RV dysfunction
Prior ventriculotomy
Late age at definitive repair
Symptomatic nonsustained ventricular tachycardia/arrhythmic symptoms
QRS fragmentation
Inducible sustained ventricular arrhythmia at invasive electrophysiology study

LV indicates left ventricular; and RV, right ventricular.

have not undergone surgical repair often have pulmonary atresia and receive pulmonary blood flow through aortopulmonary collateral vessels. Encountering adults with unrepaired TOF is rare, and the literature on this condition is limited to case reports.<sup>39</sup>

**Recommendation-Specific Supportive Text**

1. Echocardiography is used to evaluate hemodynamic sequelae in adults with repaired TOF.<sup>40,41</sup> A comprehensive echocardiogram examination may include 2-dimensional, 3-dimensional, M-mode, and strain imaging; and color, spectral, and tissue Doppler imaging.<sup>42-44</sup> Echocardiography provides information on the mechanisms of valve dysfunction, presence of residual VSDs, and size and function of the cardiac chambers, as well as the pressure gradient across the RVOT and an estimate of RV pressure.
2. CMR imaging is the gold-standard imaging modality for quantifying ventricular function, valve regurgitation, and pulmonary and systemic flows, as well as for delineating PA anatomy and detecting scar tissue in the ventricular myocardium in patients with TOF. Serial CMR examinations allow for longitudinal follow-up of patients with repaired TOF and provide useful information that aids in the timing of pulmonary valve replacement and risk stratification for adverse outcomes.<sup>45,46</sup> For routine follow-up in patients with normal ventricular function and no greater than mild pulmonary regurgitation, CMR can be obtained every 3 to 5 years. In patients with ventricular dysfunction and/or moderate or greater pulmonary regurgitation, CMR can be obtained every 2 to 3 years.
3. Before any surgical or percutaneous intervention in patients with TOF, the origins and proximal courses of the coronary arteries should be delineated, given

that at least 5% of patients with TOF have an anomalous left anterior descending coronary artery from the right coronary artery. Patients with repaired TOF and abnormal coronary artery anatomy have a substantial risk for coronary artery compression during percutaneous pulmonary valve replacement of a balloon-expandable valve or direct injury to the coronary during surgical pulmonary valve replacement. Assessment of coronary artery compression risk is done during interventional catheterization with balloon expansion within the RVOT/PA, with simultaneous aortography or coronary angiography to assess for coronary artery compression. Cross-sectional imaging with CT angiography before surgery or intervention is excellent for delineating coronary artery anatomy and also can be useful in stratification of coronary artery compression risk.<sup>47</sup>

4. Cardiac CT is useful in determining suitability for transcatheter valve placement in native RVOT anatomy.<sup>5</sup> For adults with repaired TOF being considered for self-expanding transcatheter pulmonary valve replacement, cardiac CT is necessary to evaluate the valve geometry in both phases of the cardiac cycle. In patients being evaluated for balloon-expandable transcatheter pulmonary valve replacement by an operator with ACHD expertise, it is imperative to visualize the anatomy of the coronaries and their relationship to the RVOT/main PA. If this anatomy is not clearly delineated on CMR, cardiac CT is recommended.<sup>4</sup>
5. Risk stratification for sustained ventricular tachycardia and SCD has been refined during the past several decades. Clinical risk factors include QRS duration  $>$ 180 ms,<sup>37,48</sup> fragmentation of the QRS complex,<sup>13,49</sup> symptomatic nonsustained ventricular tachycardia,<sup>50</sup> and LV dysfunction (Table 32).<sup>34,35,51</sup> More recently, multiple clinical risk scores,<sup>17-19</sup> some that include late gadolinium-enhancement CMR,<sup>18</sup> have been devised to further refine the risk profile of these patients (Table 33). Separately, inducible sustained ventricular arrhythmia has been shown to carry independent prognostic value (likelihood ratio, 3.77:1) and is strongly associated with future cardiac events.<sup>6,52</sup> Therefore, for patients with moderate risk for sustained ventricular tachycardia/SCD (estimated annual risk equal to 1% to 11.5%) by conventional risk-factor analysis or clinical risk scores,<sup>13,19,35,37,38,48-51,53</sup> invasive electrophysiologic testing with programmed ventricular stimulation is useful for further risk prognostication.<sup>6,52</sup>

**TABLE 33** Published Risk Scores for Calculating Risk for Sustained Ventricular Tachycardia/Sudden Cardiac Death in Repaired Tetralogy of Fallot

PREVENTION-ACHD <sup>17</sup>		Brompton, UK <sup>18</sup>		PACES <sup>19</sup>	
Case-control design		Observational design		Case-control design	
Outcome: SCD		Outcome: SCD, sustained VT, resuscitated VF		Outcome: SCD, sustained VT, appropriate ICD shock	
783 patients		550 patients		286 patients	
8 events		29 events		70 events	
Risk factor*	Points	Risk factor†	Points	Risk factor* or †	Points
				Surgical era	<1980 ≥1980
Coronary artery disease	1	RV LGE extent		Arrhythmic symptoms	3 3
NYHA II-III symptoms	1	Moderate	22	≥ Moderate LV dysfunction	3 3
Supraventricular tachycardia	1	Severe	24	≥ Moderate RV dysfunction	2 1
Systemic EF <40%	1	LV LGE present	11	≥ Moderate RV pressure	1 1
Subpulmonary EF <40%	1	RVEF		≥ Moderate RV volume	1 1
QRS duration ≥120 ms	1	36%-47%	8	Age at repair <6.5 years	2 0
QT dispersion ≥70 ms	1	≤35%	16	Shunt pre-repair	2 1
		LVEF		Complex repair	1 2
		36%-55%	5	QRS duration ≥180 ms	1 1
		≤35%	17	Sustained/nonsustained VT	1 1
		Peak VO <sub>2</sub> ≤17 mL/kg/m <sup>2</sup>	9		
		BNP ≥127 ng/L	9		
		Akinetic RVOT length ≥55 mm	9		
		RV pressure ≥47 mm Hg	5		
Total score	Annual event rate	Total score	Annual event rate	Total score	Risk category
0-2	<1%	0-20	0.20%	<3	Low
3	1%-2%	21-39	0.90%	3-6	Moderate
4	3%-4%	≥40	3.70%	7-9	High
5	5%-10%			>9	Very high
6	11%-25%				
7	>25%				

ACHD indicates adult congenital heart disease; BNP, B-type natriuretic peptide; CMR, cardiovascular magnetic resonance; EF, ejection fraction; ICD, implantable cardioverter-defibrillator; LGE, late gadolinium enhancement; LV, left ventricular; NYHA, New York Heart Association; RV, right ventricular, RVOT, right ventricular outflow tract; SCD, sudden cardiac death; VF, ventricular fibrillation; and VT, ventricular tachycardia.

\*Echocardiographic values.

†CMR values

Conversely, for patients with a baseline high risk for sustained ventricular tachycardia/SCD, this testing is unlikely to affect risk assessment.<sup>53</sup>

- Cardiac catheterization is the only method that can accurately determine PA pressure and PVR. Echocardiographic indices of diastolic dysfunction, prevalent in repaired TOF, do not correlate with invasively measured RV end-diastolic pressure.<sup>54</sup>
- Pulmonary valve replacement is required for adults with TOF with chronic pulmonary regurgitation, RV dilation, and dysfunction. Despite many clinical benefits, there is limited impact on the risk for sustained monomorphic ventricular tachycardia or SCD after pulmonary valve replacement.<sup>55-57</sup> Utilizing

catheter ablation to treat ventricular tachycardia may be more challenging after valve insertion due to the presence of prosthetic material overlying anatomic conduction isthmuses.<sup>9,58</sup> Several observational studies have demonstrated high yield and safety associated with routine preemptive electrophysiology studies prior to pulmonary valve replacement,<sup>6,8,9</sup> with actionable results in approximately 25% of patients.<sup>8</sup> In most cases, monomorphic ventricular tachycardia substrates can be eliminated by catheter ablation.<sup>8,9,14</sup> In cases in which myocardial hypertrophy may preclude successful elimination of ventricular tachycardia substrates by a catheter-based approach, direct intraoperative exposure and

**TABLE 34** Repaired Tetralogy of Fallot: Routine Follow-Up and Testing Intervals

Type of Follow-Up or Testing	Physiological Stage A* (mo)	Physiological Stage B* (mo)	Physiological Stage C* (mo)	Physiological Stage D* (mo)
Outpatient ACHD cardiologist	12-24	12-24	12	3-6
Electrocardiogram	24	12-24	12	12
Transthoracic echocardiogram	24	12-24	12	6-12

For timing of routine CMR and cardiac CT, see Section 4.3.5 supportive text for recommendations #2-5.

Modified with permission from Stout et al.<sup>90</sup> Copyright 2018 American Heart Association, Inc. and American College of Cardiology Foundation.

\*See Section 2.2 for details on the ACHD anatomic and physiological classification system.

ACHD indicates adult congenital heart disease; CMR, cardiovascular magnetic resonance; and CT, computed tomography.

cryoablation may be useful.<sup>27,28,59,60</sup> Given the >10% lifetime risk for sustained ventricular tachycardia in patients with repaired TOF,<sup>30-32,37</sup> the late development of post-transcatheter valve monomorphic ventricular tachycardia is of particular concern.

- Patients with TOF are at risk for sustained monomorphic ventricular tachycardia related to well-conserved postoperative anatomic isthmuses, largely found within the RVOT region.<sup>26,61</sup> Several observational studies have confirmed that complete elimination of those abnormal conduction isthmuses yields excellent freedom from recurrent ventricular tachycardia.<sup>24-26</sup> Although invasive electrophysiologic assessment of abnormal conduction isthmuses is the gold standard for the detection of reentrant ventricular tachycardia substrate, emerging evidence shows that these regions may also be detected non-invasively. Assessment of the 12-lead electrocardiogram conveys critical information regarding QRS duration,<sup>62</sup> fragmentation,<sup>13</sup> and patterns associated with abnormal isthmus conduction.<sup>12,63</sup> Abnormal conduction isthmuses may also co-localize within regions of increased signal intensity by contrast-enhanced CMR imaging.<sup>11,64</sup> Multidetector CT angiography provides detailed information regarding wall thickness at established conduction isthmuses and can document the relationship of the coronary arterial anatomy to potential catheter ablation targets.<sup>14</sup>
- Symptomatic patients (with dyspnea, chest pain, and/or exercise intolerance otherwise unexplained) with repaired TOF and pulmonary valve dysfunction who undergo pulmonary valve replacement often report improved functional class. This improvement

correlates with a reduction in RV size.<sup>65</sup> Nevertheless, many adults with repaired TOF who meet guideline criteria for pulmonary valve replacement are not referred for intervention.<sup>66</sup> Notably, adults with repaired TOF may not recognize subtle changes in their exercise capacity or report symptoms in a timely fashion. Therefore, timing of pulmonary valve replacement should not be delayed once symptoms are recognized, as greater degrees of RV dilation are associated with lower chances of normalization of RV volumes following pulmonary valve replacement.<sup>65</sup>

- Adults with repaired TOF may not recognize subtle changes in exercise capacity and may not manifest symptoms until dysfunction is significant. CPET plays a valuable role in assessing exercise capacity in patients with repaired TOF and may be a valuable adjunct to current risk-stratification strategies.<sup>67</sup> Factors contributing to risk of death or sustained ventricular tachycardia in patients with repaired TOF include older age at pulmonary valve replacement and pre-replacement RV hypertrophy and ventricular dysfunction.<sup>68</sup> Because pulmonary valve replacement reduces the composite of mortality and ventricular arrhythmias in select patients with moderate or greater pulmonary regurgitation,<sup>16</sup> either surgical or transcatheter pulmonary valve replacement by an operator with ACHD expertise is reasonable in asymptomatic adults with repaired TOF with at least 2 of the following: RV end-systolic volume index >80 mL/m<sup>2</sup>, RV end-diastolic volume ≥2× LV end-diastolic volume, RV ejection fraction ≤46%, LV ejection fraction ≤50%, or progressive decline in exercise capacity.<sup>69</sup> Prior guidelines have included thresholds of right ventricular indexed end-diastolic volume (RVEDV) in the criteria to guide pulmonary valve replacement in asymptomatic patients. However, the emphasis on indexed RVEDV in prior guidelines was chosen to reflect the size at which RV volumes return to normal following pulmonary valve replacement. In a single-center study of 189 adults with rTOF, mild or moderate RV dilatation after pulmonary valve replacement was not associated with adverse clinical outcomes.<sup>70</sup> Current scientific statements and risk stratification scores have not included indexed RVEDV in the criteria for timing of pulmonary valve replacement, as other imaging features, such as indexed RV end-systolic volume and the biventricular global function index (which incorporates both diastolic and systolic volumes) have stronger correlation with outcomes.<sup>18,46,71,72</sup>

11. Prevention of SCD is a major priority for patients with TOF. Clinical factors associated with composite outcomes of sustained monomorphic ventricular tachycardia and SCD include QRS duration<sup>37,48</sup> and fragmentation,<sup>13,49</sup> symptomatic nonsustained ventricular tachycardia,<sup>50</sup> RV and LV function,<sup>35,51</sup> evidence of myocardial scarring as detected by contrast-enhanced MR imaging,<sup>18</sup> and inducible ventricular arrhythmia at invasive electrophysiology study (Table 32).<sup>6,19,52</sup> Various risk scores have been devised to further improve diagnostic accuracy for future cardiac events among patients with TOF (Table 33).<sup>17,19,38,73,74</sup> The addition of CMR imaging findings, for quantification of both functional and substrate parameters (ie, myocardial scarring), holds particular promise.<sup>18,73-78</sup>
12. Although ICD placement can be lifesaving for repaired TOF, recurrent defibrillator shocks can be frightening to patients, increase health care utilization,<sup>79</sup> and negatively affect quality of life.<sup>80</sup> Antiarrhythmic drugs may reduce cardiac events but may not be tolerated or may even be proarrhythmic.<sup>38</sup> Catheter ablation has been associated with a reduction in appropriate device therapies for TOF.<sup>20,21</sup> In a large observational study, Kawada et al<sup>20</sup> evaluated the outcomes of catheter or surgical ablation after ICD placement among patients with aborted cardiac arrest or sustained monomorphic ventricular tachycardia. Appropriate device therapies were significantly less likely following ablation versus medical therapy (10% versus 37%), with no events occurring after a catheter-based approach. Similarly, from a large registry cohort of patients with TOF, an ICD, and pulmonary valve placement, Bessi re et al<sup>21</sup> reported that ventricular tachycardia ablation was associated with a lower rate of appropriate device therapies (hazard ratio [HR]: 0.13; 95% CI: 0.03-0.48;  $P=0.003$ ). Such data support the role of ablation in patients with TOF with ICDs and recurrent monomorphic ventricular tachycardia.
13. Pulmonary valve replacement is recommended for adults with repaired TOF, moderate or greater pulmonary valve dysfunction, and a progressive decline in ventricular systolic function, regardless of symptoms. Measurements of ventricular function derived from a single imaging study must be interpreted with caution, and comparison with serial studies is recommended.<sup>81,82</sup> The decline in ventricular function is most often right sided; however, progressive LV dysfunction may occur.<sup>83</sup> It is important to rule out other causes of LV dysfunction, such as perioperative injury, atherosclerotic coronary artery disease, or inflammatory processes. An additional mechanism for LV dysfunction is mediated through ventricular-ventricular interaction and the reverse Bernheim effect. Ventricular dysfunction is one of the strongest risk factors for adverse outcomes in adults with repaired TOF. For patients with severe LV or RV dysfunction, pulmonary valve replacement may not be tolerated or sufficient; therefore, evaluation by ACHD cardiologists and heart failure cardiologists is appropriate to decide whether a patient may be appropriate for MCS or heart transplantation rather than pulmonary valve replacement.
14. Adults with repaired TOF have several potential underlying mechanisms of tricuspid regurgitation, including disruption of the integrity of the septal leaflet of the tricuspid valve during placement of the VSD patch, endocarditis, following device lead implantation, or due to annular dilation in the setting of RV dilation.<sup>84</sup> Several studies have shown improvement in tricuspid regurgitation following both surgical and percutaneous pulmonary valve replacement.<sup>23,85</sup> Hence, in those with at least moderate pulmonary valve dysfunction and progressive functional tricuspid valve regurgitation and RV dilation, pulmonary valve replacement should be considered. The evidence on concomitant tricuspid valve intervention at the time of surgical pulmonary valve replacement is mixed, with some studies demonstrating improved tricuspid valve function<sup>86</sup> and others showing no difference or worsening tricuspid valve function.<sup>87</sup>
15. For some patients with repaired TOF and clinically tolerated sustained monomorphic ventricular tachycardia related to a well-defined anatomic isthmus, isolated ablation may represent a durable form of therapy.<sup>24</sup> Several large observational studies have reported negligible risk for recurrent ventricular tachycardia after the thorough establishment of electrical block across a culprit anatomic-conduction isthmus.<sup>24-26</sup> This contrasts starkly with a residual risk for ventricular tachycardia recurrence when such isthmuses have not been successfully eliminated.<sup>26</sup> For patients with additional risk factors for SCD, particularly impaired ventricular function, ablation may be incompletely protective.<sup>28,88</sup> For instance, among 34 patients with clinical ventricular tachycardia undergoing catheter ablation without assessment for anatomic isthmus block, LV systolic dysfunction predicted recurrent events despite acute procedural success (HR: 16.4; 95% CI: 1.8-147;  $P=0.01$ ).<sup>88</sup> Catheter ablation of ventricular tachycardia in TOF requires substantial expertise for the proper identification of ventricular tachycardia substrates, avoidance of complications, assessment of procedural endpoints, and assessment of risk for SCD. Repeated electrophysiology study to ensure durable

block and noninducibility of the ventricular tachycardia is prudent. Procedural outcomes are expected to be optimal at experienced centers with a high volume of TOF ventricular tachycardia ablation.

16. In adults with repaired TOF and moderate or greater pulmonary regurgitation and ventricular tachyarrhythmias, pulmonary valve replacement (surgical or transcatheter by an operator with ACHD expertise), in addition to arrhythmia management, may be considered to reduce the incidence of sustained ventricular tachycardiac and death. The combination of intraoperative mapping with arrhythmia surgery, plus concomitant pulmonary valve replacement, has been shown to reduce future ventricular arrhythmia episodes.<sup>27,28</sup> In addition, in a large multicenter study of patients with repaired TOF, an ICD, and appropriate shocks for ventricular arrhythmia, the addition of catheter ablation for ventricular tachycardia was independently associated with a reduction of ICD therapies after pulmonary valve replacement.<sup>15</sup> Conversely, observational data suggest a lack of reduction in future episodes of ventricular tachycardia when isolated pulmonary valve replacement is pursued without concomitant arrhythmia intervention.<sup>89</sup>

#### 4.3.6. Pulmonary Atresia With Intact Ventricular Septum

##### Synopsis

Pulmonary atresia with intact ventricular septum (PA-IVS) is a rare congenital heart lesion associated with varying degrees of RV and tricuspid valve hypoplasia characterized by membranous or muscular atresia of the RVOT without any ventricular communication. In this condition, RV pressure overload can develop when tricuspid inflow is preserved in the setting of absent RV outflow, resulting in abnormal coronary circulation. Coronary sinusoids or fistulas can develop between the RV and coronary arteries, and stenoses may ensue, making coronary perfusion dependent on flow from the hypertensive RV, the so-called “RV-dependent coronary circulation,” which influences potential management and palliative strategies. Given the wide spectrum of disease, adults with PA-IVS may have followed various surgical pathways during childhood, including biventricular repair, 1 1/2 ventricular repair, Fontan procedure, transplantation, or shunt palliation.<sup>1</sup> Adults with a history of PA-IVS have a high incidence of need for reintervention and management of atrial arrhythmias.<sup>2,3</sup>

Restrictive RV physiology is common in adults with a history of PA-IVS and may be associated with substantial ventricular fibrosis<sup>4</sup> and RV-dependent coronary circulation. When RV-dependent coronary circulation is

present, survival is worse, and the rate of SCD is higher.<sup>3,5,6</sup> Regardless of surgical repair type, clinical heart failure is common,<sup>7</sup> and several studies have shown that morbidity and mortality is elevated for all patients but may be worst for patients with early definitive palliative strategy (versus those with early palliation followed by biventricular repair).<sup>8,9</sup>

Right atrial function is impaired in nearly all adults with PA-IVS, and early data suggest that right atrial strain is independently associated with clinical outcomes of functional status, atrial arrhythmia, heart failure, hepatorenal dysfunction, and cardiovascular death.<sup>10</sup> For recommendations on the management of heart failure/transplantation, and on Fontan physiology, where appropriate, see Sections 3.6, “Heart Failure and Transplantation,” and 4.4.5, “Fontan Palliation of Single-Ventricle Physiology,” respectively. Follow-up and testing for patients with PA-IVS largely depend on the type of repair and residual physiology. For patients with 2-ventricle repair, normal heart and valve function, and absence of arrhythmia, yearly follow-up is reasonable. For patients with heart failure, significant arrhythmia, or single-ventricle physiology, follow-up will be more frequent and contingent on the type of comorbid cardiac disease present.

#### 4.3.7. Management of Right Ventricle-to-Pulmonary Artery Conduits

**Recommendations for Management of Right Ventricle-to-Pulmonary Artery Conduits**  
Referenced studies that support recommendations are summarized in the Evidence Table.

COR	LOE	RECOMMENDATIONS
<b>Diagnostic</b>		
1	B-NR	1. In patients undergoing RV-to-PA conduit stent implantation and/or transcatheter pulmonary valve implantation, preprocedural assessment of the risk for coronary artery compression should be performed to prevent coronary artery obstruction. <sup>1,2</sup>
1	B-NR	2. In patients with a stent implanted within an RV-to-PA conduit who have unanticipated progression in conduit dysfunction, imaging should be performed to rule out conduit stent fracture. <sup>3,4</sup>

Continued on the next page

Continued		
COR	LOE	RECOMMENDATIONS
1	B-NR	3. In patients with an RV-to-PA conduit, with or without transcatheter pulmonary valve implantation, unexpected conduit dysfunction with worsening pulmonary stenosis or pulmonary regurgitation should prompt an evaluation to rule out infective endocarditis and/or thrombus. <sup>5-9</sup>
2a	C-LD	4. In adults with an RV-to-PA conduit and unexplained sustained arrhythmia, heart failure symptoms, ventricular dysfunction, or cyanosis, cardiac catheterization is reasonable to assess the hemodynamics to guide further management. <sup>10</sup>
2a	C-LD	5. In adults with an RV-to-PA conduit being considered for transcatheter intervention, preprocedural coronary CT is reasonable to assess conduit calcification, anatomic characteristics, and coronary artery proximity to guide procedural planning. <sup>2</sup>
<b>Therapeutic</b>		
1	B-NR	6. For adults with an RV-to-PA conduit, severe stenosis and/or severe regurgitation, and symptoms or worsening functional capacity or a sustained arrhythmia, conduit intervention should be performed to improve cardiovascular status. <sup>*11-13</sup>
2a	B-NR	7. For adults with an RV-to-PA conduit, moderate stenosis and/or moderate regurgitation, and symptoms or worsening functional capacity or a sustained arrhythmia, conduit intervention is reasonable to improve cardiovascular status. <sup>*11,12,14</sup>
2a	B-NR	8. For asymptomatic adults with an RV-to-PA conduit and severe stenosis and/or severe regurgitation, and reduced RV ejection fraction, RV dilation, or progressive tricuspid valve regurgitation to at least moderate, conduit intervention is reasonable to improve cardiovascular status. <sup>*13,15-19</sup>

\*For criteria for interventions in patients with repaired TOF and an RV-to-PA conduit, refer to Section 4.3.5, "Tetralogy of Fallot."

## Synopsis

Conduits are used to establish continuity from ventricle to PA in complex defects when the native outflow tract is not amenable to direct repair. Conduits can be placed in the context of anatomies such as pulmonary atresia, truncus arteriosus, or complex TOF (ie, anomalous coronary artery course or absent pulmonary valve); conduits may also be incorporated into surgical strategies to address aortic stenosis or transposition of the great arteries (Ross or Rastelli procedures). This section focuses on conduits placed between the right ventricle and PA in a biventricular circulation. (Considerations pertaining to conduits between the left ventricle and PA in the setting of CCTGA are unique<sup>20</sup> and are discussed in Section 4.4.2, "Management of CCTGA." Review of conduits placed in patients with single-ventricle physiology [ie, Sano shunt] are beyond the scope of this document.)

Conduits may be homografts (aortic or pulmonary), xenografts, or prosthetic conduits with or without a bioprosthetic valve within the conduit. There is no ideal conduit, and all are expected to deteriorate over time, typically requiring replacement or intervention because of progressive stenosis within the conduit or at the valve, and/or valvular regurgitation, at a mean interval of 10 to 15 years after placement, although some conduits may last longer.<sup>21</sup> Factors associated with longevity include conduit type, sizing of the initial conduit, and patient age at implantation.<sup>21,22</sup> See Table 35 for routine testing and follow-up intervals.

## Recommendation-Specific Supportive Text

- The risk for coronary artery compression should always be evaluated, using cross-sectional imaging or conventional angiography, before stent implantation or pulmonary valve implantation. Coronary compression testing should be strongly considered in patients with high-risk coronary artery anatomies. Coronary compression testing generally involves simultaneous selective coronary angiography or aortography and balloon dilation in the RVOT to the anticipated target diameter, to ascertain whether a balloon-expanded stent will compress the coronary arteries. Coronary artery compression with conduit balloon angioplasty or stenting occurs in 5% to 14% of patients with RV-to-PA conduits and usually involves the left main/left anterior descending artery in patients with conventional coronary anatomy.<sup>1,2</sup> Patients with anomalous right or left coronary arteries are at particular risk for coronary compression, as are patients with reimplanted coronary arteries.<sup>1,3</sup>
- RV-to-PA conduit stent fracture was a common finding in the Melody Valve Investigational Device Exemption trial,<sup>3,14,23</sup> particularly in patients who did not undergo

**TABLE 35** Right Ventricle to Pulmonary Artery Conduit: Routine Follow-Up and Testing Intervals

Type of Follow-Up or Testing	Physiological Stage A* (mo)	Physiological Stage B* (mo)	Physiological Stage C* (mo)	Physiological Stage D* (mo)
Outpatient ACHD cardiologist	N/A	12	6-12	3-6
Electrocardiogram	N/A	12	12	12
Transthoracic echocardiogram†	N/A	12	12	6-12

Modified with permission from Stout et al.<sup>32</sup> Copyright 2018 American Heart Association, Inc. and American College of Cardiology Foundation.

\*See Section 2.2 for details on the ACHD anatomic and physiological classification system.

ACHD indicates adult congenital heart disease; and N/A, not applicable.

prestenting before conduit placement. Prestenting was associated with a 3-year rate of freedom from stent fracture of 74% (±3), and from conduit reintervention of 85% (±2).<sup>4</sup> Stent fracture typically manifests with progressive stenosis and, in patients with transcatheter valves, potentially also with worsening pulmonary regurgitation. Patients with unexpected progression in conduit dysfunction should have fluoroscopic, x-ray assessment, and/or cross-sectional imaging to rule out stent fracture.<sup>24</sup>

- Infective endocarditis is an important potential complication after transcatheter pulmonary valve implantation, with variability in complication rate according to valve type.<sup>25</sup> Other recognized risk factors include younger age at implantation, previous history of endocarditis, impaired immunity, and residual invasive gradient (>15 mm Hg).<sup>6-8</sup> Patients typically present with fever and malaise, as well as worsening pulmonary stenosis or pulmonary regurgitation. Although cases may respond well to medical management with intravenous antibiotics if infective endocarditis is identified and if treatment is initiated early in the disease course, surgical removal of the valve is often necessary. Some data suggest that medical management is less effective, specifically that valve explantation is more common with *Staphylococcus aureus* pathogens than *Streptococcus* species infections. Infective endocarditis has been associated with the presence of subclinical thrombus formation, and aspirin is often used to reduce this risk.<sup>26,27</sup> Bioprosthetic pulmonary valve thrombosis is a recognized complication, although it is more commonly seen with bioprosthetic valves in other positions.<sup>9</sup>
- Although noninvasive imaging with echocardiography, CMR imaging, or coronary CT angiography

provides a reasonably comprehensive assessment of ventricular function, conduit function, patency, and PA anatomy, cardiac catheterization is appropriate to directly assess hemodynamics in cases of clinical decompensation. Direct assessments of intracardiac and pulmonary arterial pressures and cardiac output provide useful information about volume status, pulmonary arterial resistance, and degree of conduit stenosis or regurgitation. Because of anatomic and technical factors, noninvasive imaging may provide equivocal information and may underestimate the degree of conduit stenosis or regurgitation; invasive assessment is especially important in such cases.<sup>10</sup>

- Cross-sectional imaging, ideally with gated cardiac CT angiography prior to transcatheter intervention on an RV-to-PA conduit, provides excellent resolution of anatomic detail, such as degree of conduit stenosis, extent and pattern of calcification, branch PA anatomy, coronary arterial anatomy, and proximity of coronary arteries to the conduit.<sup>2,24</sup> Some authors have suggested that electrocardiographic gating may not be necessary if coronary arteries are adequately opacified on CT angiography.<sup>2</sup> CMR angiography and a coronary sequence can be considered a reasonable alternative to CT angiography.
- RV-to-PA conduit intervention includes surgical replacement, percutaneous stenting, and/or transcatheter valve placement. Patients with severe conduit regurgitation or stenosis (Table 27) who have worsening exercise capacity or sustained arrhythmias (atrial or ventricular) can benefit from surgical or transcatheter conduit intervention, by an operator with ACHD expertise, to relieve stenosis and/or regurgitation.<sup>11-14,28</sup> Transcatheter stent implantation and pulmonary valve replacement may be performed with high procedural success and low mortality rates, and the procedure may improve cardiovascular status (specifically, amelioration of hemodynamics and exercise capacity).<sup>23,29,30</sup> Surgical conduit replacement carries a higher risk for periprocedural complications with good long-term outcomes.<sup>21,22</sup> Predictors of conduit dysfunction and reoperation include placement of small-diameter conduits; therefore, insertion of conduits with the largest possible diameter should be attempted,<sup>21,22</sup> anticipating possible subsequent transcatheter valve replacement. A growing body of literature—showing significant, sustained hemodynamic and functional benefits of judicious conduit intervention, including

transcatheter pulmonary valve replacement—has resulted in this recommendation being upgraded from COR 2a in the 2018 ACC/AHA ACHD guidelines to COR 1 for patients with severe regurgitation or stenosis in the 2025 guidelines.<sup>21-24,28-30</sup>

7. For moderate severity conduit dysfunction (regurgitation or stenosis) (Table 27), intervention should be considered in patients who demonstrate reduced exercise capacity or arrhythmias in order to improve hemodynamics and, by extension, reduce adverse outcomes and improve functional status and exercise capacity. Imaging and clinical outcomes after intervention are favorable in the short, medium, and long term.<sup>11,14,15,23,29</sup>
8. RV-to-PA conduit intervention—which includes surgical replacement, percutaneous stent implantation, and/or transcatheter valve placement—may be reasonable in asymptomatic patients with severe RV-to-PA conduit stenosis or regurgitation in the presence of reduced RV systolic function or dilation. Although suggested thresholds for intervention based on RV dilation have been published for patients with repaired TOF (see Section 4.3.5, “Tetralogy of Fallot”), similar metrics are not yet available for patients with an RV-to-PA conduit in the context of other anatomies (notably, interval dilation continues to be an important marker of ventricular instability, which may justify an intervention). Intervention is expected to result in improved hemodynamics, decreased RV size, improved RV stroke volume, increased RV ejection fraction, and decreased tricuspid regurgitation (if present).<sup>18,19,28</sup> Moreover, peak oxygen consumption and anaerobic threshold may also improve with conduit intervention.<sup>15-17</sup> Favorable clinical and imaging results have been reported after implantation of balloon-expandable percutaneous valves.<sup>23,31</sup> Emerging data on self-expanding valve technologies designed for larger, more compliant RVOTs are discussed in Section 4.3.5, “Tetralogy of Fallot.” The growing body of literature on judicious conduit interventions, including transcatheter valve placement, that show improvement in hemodynamics and objective exercise capacity in patients who are not overtly symptomatic have resulted in adjustment of the strength of this recommendation from COR 2b in the 2018 ACC/AHA ACHD guidelines to COR 2a in the 2025 guidelines.<sup>15-17,23,28,31</sup>

#### 4.4. Complex Lesions

##### 4.4.1. dextro-Transposition of the Great Arteries

##### 4.4.1.1. Patients With dextro-Transposition of the Great Arteries and Atrial Switch

**Recommendations for Patients With dextro-Transposition of the Great Arteries and Atrial Switch**  
 Referenced studies that support recommendations are summarized in the Evidence Table.

COR	LOE	RECOMMENDATIONS
<b>Diagnostic</b>		
1	B-NR	1. Adults with dextro-transposition of the great arteries (d-TGA) and atrial switch who have progressive exercise intolerance or heart failure should undergo imaging with transthoracic echocardiogram and CMR imaging to assess ventricular, valve, baffle, and pathway function to detect and identify treatable hemodynamic lesions. <sup>1-3</sup>
1	B-NR	2. Adults with d-TGA and atrial switch who present with progressive exercise intolerance or heart failure should undergo CPET to assess for potential intervention targets, including arrhythmia and desaturation. <sup>4-6</sup>
1	B-NR	3. Adults with d-TGA and atrial switch with progressive exercise intolerance, heart failure, pulmonary hypertension, worsening atrial or ventricular tachyarrhythmia, pathway obstruction, or baffle leak should undergo invasive hemodynamic assessment to identify targets for medical, percutaneous, or surgical intervention. <sup>7-10</sup>
1	C-LD	4. Adults with d-TGA and atrial switch who require permanent pacemaker or an ICD should undergo pre-procedural imaging, in addition to intraprocedural contrast venography, to detect baffle stenosis and residual baffle leaks. <sup>11-13</sup>

*Continued on the next page*

Continued		
COR	LOE	RECOMMENDATIONS
2a	B-NR	5. For adults with d-TGA and atrial switch, biomarkers and validated disease-specific risk scores can be useful to identify patients at high risk for adverse cardiac events, prompting closer follow-up and referral to specialized heart failure transplant centers. <sup>1,14,15</sup>
2a	B-NR	6. In adults with d-TGA and atrial switch with new or progressive symptoms of heart failure, it is reasonable to obtain a resting electrocardiogram and outpatient ambulatory rhythm monitoring to ensure timely diagnosis and treatment of tachyarrhythmia or bradyarrhythmia. <sup>15-19</sup>
2b	B-NR	7. In adults with d-TGA and atrial switch, it may be reasonable to apply disease-specific scores to identify patients at increased risk for sustained ventricular tachyarrhythmia and/or SCD, in order to determine eligibility for a primary-prevention ICD. <sup>1,16,17</sup>
<b>Therapeutic</b>		
1	B-NR	8. In adults with d-TGA and atrial switch who have atrial arrhythmias, rhythm control strategies are preferable to rate control strategies to reduce symptoms and prevent heart failure. <sup>14,18-21</sup>
1	C-LD	9. Adults with d-TGA and atrial switch who have symptoms attributable to a baffle leak should undergo closure of the leak to improve symptoms and quality of life. <sup>22,23</sup>
1	C-LD	10. In adults with d-TGA and atrial switch who have symptoms attributable to systemic or pulmonary venous pathway stenosis or liver congestion, intervention to relieve the stenosis is indicated to improve symptoms and prognosis. <sup>23,24</sup>

continued in the next column

Continued		
COR	LOE	RECOMMENDATIONS
1	C-LD	11. Adults with d-TGA and atrial switch who have worsening symptoms of exercise intolerance, heart failure, or arrhythmia refractory to treatment should be referred to a heart failure program for assessment for mechanical support and transplantation in consultation with an ACHD cardiologist, to improve quality of life and prolong survival. <sup>10,25,26</sup>
2a	C-LD	12. In adults with d-TGA and atrial switch who have sustained intra-atrial reentrant arrhythmias or atrial fibrillation, oral anti-coagulation can be useful to prevent embolic events. <sup>27,28</sup>
2a	C-EO	13. Adults with d-TGA and atrial switch who require transvenous lead placement can benefit from catheter-based interventions to address residual baffle leaks or obstruction before lead placement, to reduce the risk for systemic thromboembolism and/or future baffle occlusion. <sup>11-13</sup>
2b	B-NR	14. Symptomatic adults with d-TGA and atrial switch who have a failing systemic right ventricle and a QRS duration >150 ms related to chronic ventricular pacing may be considered for CRT to improve symptoms. <sup>26</sup>
2b	B-R	15. In adults with d-TGA and atrial switch who have heart failure with reduced RV function, it may be reasonable to use GDMT for heart failure with reduced ejection fraction in order to treat the heart failure and improve symptoms, ventricular function, and outcomes. <sup>29-31</sup>

## Synopsis

Although atrial switch was replaced by arterial switch more than 3 decades ago, there remains a large population of patients with d-TGA who have undergone atrial switch and whose morbidity and mortality rates are increasing as they get older.<sup>15</sup> The ventricle supporting the systemic circulation is morphologically right and is prone to progressive systolic dysfunction and heart failure: 42.8% with moderate or severe systemic ventricular dysfunction at a median age of 29 years.<sup>1</sup> In addition, the systemic atrioventricular valve is a tricuspid valve that is prone to regurgitation (moderate or severe in a quarter of patients).<sup>1</sup> Exercise intolerance and heart failure are common (44% of patients by age 45 years) and often caused by multiple related factors such as ventricular or valve dysfunction, chronotropic incompetence, pathway obstruction or baffle leaks, arrhythmia, and PAH (which is typically postcapillary but occasionally precapillary [1.6% of patients treated with PAH therapies] or combined).<sup>1,4</sup>

Up to one-half of patients referred to cardiac catheterization had stenosis of the pulmonary and systemic venous pathways, which can cause pulmonary or systemic venous congestion.<sup>23</sup> Baffle leaks have been described in up to 65% of cases, allowing left-to-right shunting with ventricular overload or bidirectional shunting with cyanosis and risk for paradoxical emboli.<sup>13,23</sup>

Atrial arrhythmias affect 28.9% of patients,<sup>1</sup> related to the extensive surgical scar and hemodynamic load. There also are risks for ventricular arrhythmias (5.8% of patients in the same study<sup>1</sup>) and sudden death (incidence, 0.63%/year).<sup>16</sup> Progressive loss of sinus rhythm is common (24.9% of patients), requiring permanent pacing. See [Table 36](#) for suggested routine testing and follow-up intervals for d-TGA with atrial switch operation.

## Recommendation-Specific Supportive Text

1. Imaging, an important component of the specialist follow-up of patients with d-TGA after atrial switch, should be goal-directed, cognizant of potential long-term sequelae, and individualized to each patient. Transthoracic echocardiography is the first-line investigation, is widely available and, in expert hands, can detect most structural and hemodynamic long-term sequelae of atrial switch using a combination of views, with the potential for enhancement by machine learning.<sup>32-34</sup> Ventricular function, both systemic and subpulmonary, and the severity of tricuspid regurgitation are independent predictors of outcomes in this population.<sup>2,14</sup> Data from transthoracic echocardiography should be complemented by CMR imaging, which can more accurately quantify systemic RV function and offer detailed visualization of the systemic and pulmonary venous pathways. CMR should be used routinely barring contraindications (eg, a permanent pacemaker or ICD that is not conditional on MR imaging).<sup>3</sup> Late gadolinium enhancement is an important MR tool that can identify areas of myocardial scar that are associated with adverse clinical markers, including atrial arrhythmia. CT also has a role in defining venous return and pathways, especially in the presence of a permanent pacemaker, ICD, stent, or closure device that can cause artifact or prohibit the use of MR imaging. The frequency of CMR scanning depends on the presence of ventricular dysfunction or residual hemodynamic lesions: Patients with normal or mildly impaired RV systolic function and no significant hemodynamic lesions should undergo CMR every 3 to 5 years, and otherwise every 1 to 3 years.
2. CPET is integral to assessing patients with complex congenital heart disease, including in the surveillance of adults with d-TGA and atrial switch.<sup>4,35</sup> Peak oxygen consumption (<52.3% of predicted) and the slope of ventilation to carbon dioxide output ( $\geq 35.4$ ) are independent predictors of death or emergency cardiac hospitalization in this cohort. Exercise-induced cyanosis can also identify patients with baffle leaks. Finally, CPET can elucidate the safety of physical activity, its risk for adverse events (eg, tachyarrhythmias, bradyarrhythmias), and the intensity of exercise training that is appropriate for improving the patient's exercise capacity and perceived physical functioning.<sup>36,37</sup> Patients with normal or mildly impaired RV systolic function and no significant hemodynamic lesions should undergo CPET every 3 to 5 years, and otherwise every 1 to 3 years.
3. Heart failure is often multifactorial in patients with d-TGA after atrial switch, and targets for intervention and medical therapy should be sought early. Cardiac catheterization is important in detecting and establishing the severity of abnormalities in the systemic and pulmonary venous pathways: Baffle leaks can be detected and shunts quantified through serial oximetry. Pulmonary hypertension, common in patients with atrial switch, should be identified and characterized; it is most often postcapillary (ie, related to abnormalities of the systemic right ventricle, tricuspid valve, and pulmonary venous pathways).

**TABLE 36** Patients With d-TGA and Atrial Switch: Routine Testing and Follow-Up Intervals

Type of Follow-Up or Testing	Physiological Stage A* (mo)	Physiological Stage B* (mo)	Physiological Stage C* (mo)	Physiological Stage D* (mo)
Outpatient ACHD cardiologist	N/A	12-24	12	3-6
Electrocardiogram	N/A	12-24	12	12
Transthoracic echocardiogram	N/A	12-24	12	12

For recommendations on routine Holter monitoring, see supportive text for recommendation #6. For recommendations about timing of CMR, see supportive text for recommendation #1. Modified with permission from Stout et al.<sup>63</sup> Copyright 2018 American Heart Association, Inc. and American College of Cardiology Foundation.

\*See Section 2.2 for details on the ACHD anatomic and physiological classification system.

ACHD indicates adult congenital heart disease; CMR, cardiovascular magnetic resonance; d-TGA, dextro-transposition of the great arteries; and N/A, not applicable.

However, precapillary pulmonary hypertension is well described in d-TGA and can be severe and progressive, sometimes related to late repair in patients with a large VSD, or it can occur for no apparent reason. There is very limited evidence for the use of pulmonary hypertension therapies in such cases. In advanced heart failure, pulmonary hypertension is often combined pre- and postcapillary, and special provocation protocols may be required in the catheterization laboratory to distinguish between patients eligible for heart versus heart-lung transplantation.

4. Implantation of a permanent pacemaker or ICD in patients with d-TGA after atrial switch may be complicated by the presence of a narrow superior vena cava pathway, with the risk for obstruction to flow and upper body congestion after lead implantation if the azygos vein cannot act as an offloading pathway. An invasive venogram prior to device implantation can be helpful for delineating anatomy. Before implantation, transthoracic echocardiography, CMR, and cardiac CT can provide valuable information on the size of the superior vena cava pathway. Baffle leaks are very common (up to 65% of affected patients) and may increase the risk for thromboembolic complications from transvenous pacing leads, with a small risk for inadvertent implantation of leads in the systemic ventricle.<sup>13,22</sup> Echocardiography using agitated saline contrast is a sensitive method for detecting baffle leaks, although injection into the upper and lower extremities may be necessary in some patients.<sup>38</sup>
5. Risk stratification for mortality and other major events is integral to routine assessment of patients with d-TGA after atrial switch. Broberg et al<sup>1</sup>

described the following independent predictors of death, transplantation, or MCS: prior ventricular arrhythmia or heart failure admission, complex anatomy, QRS duration >120 ms, and severe systemic RV dysfunction on echocardiography. Albertini et al<sup>39</sup> provided external validation of the prediction model developed by Woudstra et al,<sup>15</sup> which included the following components: age >30 years, prior ventricular arrhythmia, age >1 year at repair, at least moderate dysfunction of the systemic right ventricle, severe tricuspid regurgitation, and at least mild LV dysfunction. Indeed, it is now well established that the characteristics of the subpulmonary left ventricle have prognostic implications in this population.<sup>2</sup>

6. Sinus node dysfunction, supraventricular arrhythmias, and ventricular arrhythmias are common in adults with d-TGA after atrial switch, and they are major contributors to morbidity and mortality.<sup>15,16,18,40</sup> Pacemaker implantation is required in 15% to 30% of patients by the time they reach adulthood.<sup>18,41</sup> Atrial and ventricular arrhythmias are prognostic markers of morbidity and death, and they should be detected and managed early.<sup>1,14,15</sup> The frequency and length of Holter monitoring in asymptomatic patients and the role of routinely implanted loop recorders for the early detection of atrial and ventricular arrhythmia remain unclear although it is reasonable to repeat Holter monitoring in asymptomatic patients every 3 to 5 years.<sup>42</sup>
7. Malignant arrhythmias and SCD, also well described in this population, occur in patients who are younger at the time of the event than patients dying of other causes.<sup>1,19</sup> Ladouceur et al<sup>16</sup> have described a prognostic model for SCD, sustained ventricular tachycardia, or appropriate ICD therapy in this population: It includes age, history of heart failure, syncope and QRS duration, severe systemic RV dysfunction, and LVOT obstruction. Aborted SCD related to malignant arrhythmia in this population warrants ICD implantation for secondary prevention in patients who are not in an end-of-life pathway. Khairy et al, however, found an exceedingly low rate of appropriate ICD shocks in patients with primary prevention indications.<sup>17,19,39,43,44</sup> Transvenous ICD implantation is preferable in this population, which is prone to supraventricular tachycardias, although superior vena cava pathway stenosis must be excluded or treated. Subcutaneous ICDs are a valid alternative, although less able to distinguish between ventricular and supraventricular tachycardia, increasing the risk

for inappropriate shocks. CRT may be considered in this setting.<sup>26</sup> Although risk stratification is integral to managing patients with d-TGA after atrial switch, the role of ICD implantation in primary prevention remains unclear.

8. Sustained intra-atrial reentrant tachycardia is common and can cause rapid decompensation and death, depending on the patient's ventricular rate and underlying clinical status.<sup>14,18,19</sup> Atrial arrhythmias have been shown to precede or coexist with ventricular tachycardia in 50% of cases, suggesting that atrial arrhythmias are a common trigger for ventricular arrhythmias.<sup>19</sup> Atrial arrhythmias also carry risk for thromboembolism. Timely treatment to restore and maintain sinus rhythm is desirable, including early electrical cardioversion, antiarrhythmic medication, or catheter ablation using modern techniques such as 3-dimensional image integration, mapping, or robotic magnetic navigation.<sup>20,21</sup> Expert anesthetic care during such procedures is essential to minimizing risk. When such patients present with arrhythmia to nonspecialist centers, it is important to contact a specialist ACHD center as soon as possible to discuss the management plan and anesthesia risk.
9. Indications for intervening on a baffle leak include symptoms related to significant left-to-right shunting that is causing LV volume overload, right-to-left shunting that allows cyanosis at rest and/or on exercise, or paradoxical emboli, keeping in mind that baffle leaks are often asymptomatic. The benefits of closing a baffle leak should be weighed against the risk for pulmonary congestion in patients with severe systemic ventricular dysfunction or tricuspid regurgitation. Baffle leaks are now typically addressed percutaneously because surgical revision can carry significant risks related to systemic RV dysfunction and other comorbidities, as well as the risk for further sensitization through blood transfusions that may have an impact on future transplantation.<sup>22</sup>
10. Percutaneous intervention should be offered to relieve systemic or pulmonary venous pathway stenosis that contributes to systemic or pulmonary venous congestion. Relief of superior vena cava pathway stenosis may also be considered in patients requiring permanent pacemaker or ICD implantation, to reduce the risk for obstruction to flow and congestion caused by the pacemaker and, especially, ICD leads. Relief of inferior vena cava pathway stenosis is also indicated in the presence of significant liver congestion. Surgical revision can also be considered, but it typically carries perioperative risks that should be balanced against the projected benefits.<sup>23,24</sup>
11. The natural history of d-TGA after atrial switch repair is one of progressive systemic RV dysfunction and heart failure, which can be refractory to treatment for heart failure, with no hemodynamic or arrhythmic targets that can be addressed at reasonable risk. Advanced heart failure therapies such as transplantation and MCS are options for patients with heart failure or refractory arrhythmias. Early referral to a heart failure specialist for collaborative care and planning is appropriate, although the limited availability of organs and risks related to complex anatomy, prior cardiac surgery, multiorgan failure, and human leukocyte antigen sensitization are common impediments to transplantation in this population.<sup>45</sup> MCS has been increasingly used, despite technical difficulties in applying standard devices to the systemic right ventricle,<sup>10,46</sup> and it can be a bridge to transplantation in select patients, such as those who are frail or have elevated PVR.<sup>10,25,47,48</sup> Intravenous diuretics are the mainstay of management for decompensated heart failure in patients with d-TGA after atrial switch.<sup>49</sup> In parallel, anatomic or other causes and triggers for heart failure (eg, arrhythmia, pathway stenosis, or anemia) should be sought and, when possible, addressed. Tricuspid regurgitation, a major contributor to heart failure in this population, is associated with adverse outcomes. Tricuspid valve repair or replacement should be considered but may provide little benefit at significant perioperative risk when secondary to systemic RV dilatation and dysfunction, rather than intrinsic tricuspid valve abnormalities.<sup>50,51</sup> Early involvement of heart failure and palliative care teams in symptomatic patients can help to control symptoms and to optimize outcomes and quality of life.
12. Sustained arrhythmias defined as duration >30 seconds should be considered for anticoagulation, regardless of CHA<sub>2</sub>DS<sub>2</sub>-VASC score.<sup>28,52</sup> Data on the choice between vitamin K antagonists and direct oral anticoagulants in this setting are limited, although recent evidence suggests that the latter may be safe and effective in this population.
13. Patients who require transvenous pacing or ICD implantation and have evidence of a baffle leak should be considered either for baffle leak closure or anticoagulation, to minimize the risk for paradoxical emboli. Baffle leaks often manifest as desaturation during exercise and can be diagnosed by echocardiography with injection of agitated saline, followed by

transesophageal echocardiography if intervention is contemplated.<sup>11-13,38</sup>

14. Kharbanda et al<sup>26</sup> provide evidence of benefit from cardiac resynchronization in patients with a failing systemic right ventricle who were previously paced, though not those implanted de novo. Yin et al<sup>53</sup> describe an improvement in functional class in an ACHD population, a quarter of whom had a systemic right ventricle, with a short- but not a long-term reduction in systemic right ventricle size. However, fewer than half of patients were deemed to be “responders” to CRT. Carefully selecting patients is important, in terms of both anatomic suitability and maximizing efficacy, and should include echocardiographic optimization to device setting.
15. Small randomized controlled trials, retrospective studies, and a meta-analysis by the AHA have failed to detect a benefit of treatment with RAAS inhibitors, beta blockers, or tadalafil (a phosphodiesterase-5 inhibitor) across the spectrum of patients with systemic right ventricle.<sup>54-61</sup> More novel treatments for heart failure (eg, sacubitril/valsartan and dapagliflozin) appear to be safe and potentially effective in non-randomized studies of patients with a systemic right ventricle.<sup>30,31,62</sup> Recently, Woudstra et al<sup>29</sup> have detected an improvement in prognosis in symptomatic adults with d-TGA and atrial switch with severe systemic RV systolic dysfunction who were treated with RAAS inhibitors and beta blockers.

4.4.1.2. Arterial Switch Operation

**Recommendations for Arterial Switch Operation**  
Referenced studies that support recommendations are summarized in the Evidence Table.

COR	LOE	RECOMMENDATIONS
<b>Diagnostic</b>		
1	B-NR	1. In adults with an arterial switch operation, baseline and serial imaging with both echocardiography and CMR imaging should be performed periodically to assess neo-aortic size, valve function, PA or branch PA morphology, and ventricular function. <sup>1-4</sup>

*continued in the next column*

Continued		
COR	LOE	RECOMMENDATIONS
1	C-LD	2. In adults with an arterial switch operation and symptoms concerning for myocardial ischemia, coronary evaluation with coronary angiography, cross-sectional imaging, and/or functional coronary assessment for an anatomic etiology should be performed. <sup>5</sup>
2a	B-NR	3. In asymptomatic adults with an arterial switch operation, baseline anatomic assessment of coronary artery anatomy and patency with gated cardiac CT is reasonable to evaluate for postoperative complications and/or high-risk features. <sup>6-10</sup>
<b>Therapeutic</b>		
1	C-EO	4. In adults with an arterial switch operation and evidence of myocardial ischemia, coronary revascularization should be performed to reduce symptoms and improve outcomes.
2a	C-EO	5. In adults with an arterial switch operation and symptoms attributable to moderate or greater supra-valvar or branch PA stenosis, intervention is reasonable to improve symptoms and functional class.
2a	C-EO	6. In asymptomatic adults with an arterial switch operation who have moderate or greater supra-valvar or branch PA stenosis—in addition to RV hypertension, RV dysfunction, progressive tricuspid regurgitation, and/or objective decline in exercise capacity—intervention can be useful to relieve obstruction.
2b	B-NR	7. In adults with an arterial switch operation and severe neo-aortic root dilation who have progressive neo-aortic valve insufficiency and/or rapid root growth or for whom a neo-aortic valve intervention is planned, neo-aortic root replacement may be considered to prevent worsening neo-aortic regurgitation. <sup>2,11,12</sup>

**Synopsis**

The arterial switch operation is the standard of care for patients with d-TGA given superior long-term outcomes relative to the atrial switch operation.<sup>13-15</sup> Although survival to early and middle adulthood is excellent and overall reintervention rates are low, longer-term sequelae remain less well known because the earliest cohort of patients undergoing arterial switch operations were born in the 1980s. Routine longitudinal follow-up is warranted to monitor for the most common postsurgical complications, including neo-aortic root dilation, neo-aortic regurgitation, supravalvar (suture line) or branch PA stenosis, and coronary obstruction.<sup>1-3,16-21</sup> In addition, this population has increased rates of neurocognitive disorders that, when present, may worsen quality of life.<sup>22,23</sup> Emerging data exist about increased risk for acquired coronary disease following arterial switch operation; it may be beneficial to ensure regular assessment and treatment of traditional cardiovascular risk factors.<sup>10,24,25</sup>

Little evidence exists about thresholds for intervention in the well-described complications after arterial switch operation. In adults with an arterial switch operation and severe neo-aortic regurgitation, guidelines for aortic valve disease should be used to determine the timing of intervention to alleviate symptoms and improve outcomes.<sup>26</sup> Given the anatomic and physiological differences among the various other complications after an arterial switch operation, an individualized approach to other interventions is warranted. See **Table 37** for suggested routine testing and follow-up intervals for patients with d-TGA after arterial switch operation.

**Recommendation-Specific Supportive Text**

1. Imaging in adults with d-TGA following an arterial switch operation should be routinely performed to evaluate for the late development of complications that may include neo-aortic valve stenosis or regurgitation, neo-aortic root enlargement, neopulmonic valve stenosis or regurgitation, branch PA stenosis, and/or ventricular dysfunction related to coronary complications.<sup>1,12,18,27,28</sup> Echocardiography is often adequate to assess valvular and ventricular function, but CMR is superior in assessing neo-aortic root size and PA anatomy. CMR is also of great importance in the overall assessment of patients with suboptimal acoustic

**TABLE 37 Patients With d-TGA and Arterial Switch: Routine Follow-Up and Testing Intervals**

Type of Follow-Up or Testing	Physiological Stage A* (mo)	Physiological Stage B* (mo)	Physiological Stage C* (mo)	Physiological Stage D* (mo)
Outpatient ACHD cardiologist	12-24	12	6-12	3-6
Electrocardiogram	12-24	12-24	12	6
Transthoracic echocardiogram†	12-24	12-24	12	12

For recommendations about timing of cardiac CT and CMR imaging, see supportive text for recommendations #1-3. For suggested frequency of CMR imaging,‡ see supportive text for recommendation #1.

Modified with permission from Stout et al.<sup>44</sup> Copyright 2018 American Heart Association, Inc. and American College of Cardiology Foundation.

\*See Section 2.2 for details on the ACHD anatomic and physiological classification system.

†Routine transthoracic echocardiography may be further deferred during an interval when CMR is performed.

‡CMR should include assessment of neo-aortic size, the origin and proximal course of the coronary arteries, branch pulmonary arteries, ventricular function, and valvular function.

ACHD indicates adult congenital heart disease; CMR, cardiovascular magnetic resonance; and CT, computed tomography.

windows.<sup>2-4,29</sup> For patients with a neo-aortic diameter <5 cm and unobstructed or mildly obstructed branch PAs, CMR may be obtained every 3 to 5 years. For patients with a neo-aortic diameter >5 cm at any segment and/or moderate or greater branch PA stenosis, CMR every 1 to 2 years is likely an appropriate interval. Cardiac CT may also be used if CMR is not feasible to evaluate the neo-aortic root and/or branch PA anatomy, especially after PA stent placement.

2. In patients with an arterial switch operation, new symptoms concerning for ischemia should be investigated with anatomic assessment of the reimplanted coronary arteries. CT remains the gold standard for focused coronary artery assessment and should in most instances be the initial diagnostic test, but CMR provides diagnostic-quality coronary assessment in up to 95% of cases and may be combined with protocol elements that allow for dynamic testing.<sup>30,31</sup> Given the potential for dynamic obstruction, further assessment with perfusion imaging and/or cardiac catheterization may be needed if routine cross-sectional imaging is unrevealing.<sup>32</sup> Regadenoson stress CMR perfusion abnormalities correlated well with cardiac catheterization data in a study of children and young adults with arterial switch operation: Approximately one-third of perfusion studies in symptomatic patients identified a perfusion defect.<sup>5</sup>

3. Coronary abnormalities are common after an arterial switch operation (6% to 10% of cases), although most are identified soon after repair in childhood.<sup>8,9</sup> Recent studies have identified high-risk coronary features associated with increased risk for ventricular tachycardia and SCD, although still at very low rates; these features include intramural course, acute angulation of the left coronary artery, clockwise rotation of the left coronary ostium, and smaller distance between the left coronary ostium and the neopulmonary artery.<sup>6,7,33</sup> The overall rate of acute coronary complications with an arterial switch operation is extremely low in adults, with 96% freedom from coronary reintervention at 25 years following the initial operation, and limited guidance about interventional strategies is available for instances when complications do occur.<sup>6,7,33</sup> No existing data support routine, serial coronary-specific imaging after the coronary anatomy is defined, although such imaging may be reasonable if high-risk features are identified.
4. Anatomic coronary complications and interventions after an arterial switch operation are rare in the modern era, with the majority occurring in childhood.<sup>6,33,34</sup> Given that the oldest patients with an arterial switch operation are now in young adulthood, natural history studies have not yet shown whether there is increased risk for atherosclerotic coronary artery disease after an arterial switch operation. Percutaneous and/or surgical coronary interventions should be considered on an individual basis by a multidisciplinary team that includes interventional and congenital cardiologists.
5. PA stenosis, either at the main PA anastomotic site or in the branch PAs due to their position following the Lecompte maneuver, is common after an arterial switch operation. Most hemodynamically significant stenosis is identified in childhood, but subsequent progression in adults can occur and is often related to progressive aortic enlargement, especially for the left PA.<sup>20,35-37</sup> PA stenosis is associated with diminished exercise capacity after an arterial switch operation.<sup>38</sup> No studies have yet examined outcomes of PA interventions in adults after an arterial switch operation even though these interventions are among the most common procedures in this population.<sup>28</sup> In patients with symptoms attributable to PA stenosis, alleviating obstruction may improve functional status. Procedural planning should consider the anatomic position of the PAs in the Lecompte position, especially in planning transcatheter interventions, to avoid the creation of aortopulmonary fistulas.<sup>39</sup>
6. PA stenosis, even in a single branch PA, may affect the RV pressure load. Pediatric literature suggests that even single PA stenosis affects RV hemodynamics over time, but whether intervention reverses those changes is unknown.<sup>40</sup> Extrapolating from recommendations for asymptomatic pulmonary valve stenosis, it is reasonable to consider intervention on PA stenosis to reduce the risk for sequelae from long-term pressure loading of the right ventricle.<sup>41</sup> If no intervention is planned, patients should be monitored longitudinally for new symptoms, worsening exercise capacity, and/or worsening RV function.
7. Neo-aortic root intervention after an arterial switch operation should be considered on an individual basis, especially in the setting of progressive neo-aortic insufficiency, rapid aortic dilatation (>3 mm/year), and/or if neo-aortic valve intervention is planned to limit progression of neo-aortic regurgitation. Moderate or greater neo-aortic insufficiency correlates well with root diameter, and several retrospective studies have identified root growth over time as a risk factor for worsening neo-aortic regurgitation.<sup>2,11,12</sup> Data from high-volume studies of valve-sparing aortic root replacements in patients with a BAV and connective tissue disease have documented stabilization of aortic valve function after root replacement.<sup>42</sup> Although neo-aortic root dilation is extremely common after an arterial switch operation, there have been no reports of aortic dissection at any diameter in this population. Given that the mechanism of dilation differs from that of other forms of aortopathy, the risk for aortic dissection appears to remain low, even with increased neo-aortic root diameters. Accordingly, guidelines for thoracic aortic disease regarding the diameter for prophylactic root replacement<sup>43</sup> may expose patients with arterial switch to increased surgical interventions without the benefit of preventing dissection.

4.4.1.3. Patients With d-TGA and Rastelli Repair

**Recommendation for Patients With d-TGA and Rastelli Repair**  
 Referenced studies that support recommendation are summarized in the Evidence Table.

COR	LOE	RECOMMENDATION
<b>Diagnostic</b>		
1	B-NR	1. In adults with d-TGA and Rastelli repair, imaging is recommended to ensure timely identification of complications, including stenosis and/or regurgitation of the RV-to-PA conduit, residual VSDs, LVOT obstruction, and RV dysfunction. <sup>1-3</sup>

**Synopsis**

The Rastelli operation is performed in patients with d-TGA who have a VSD and pulmonary stenosis.<sup>4,5</sup> The operation consists of an intracardiac baffle that directs oxygenated blood from the LV via a nonrestrictive VSD to the aorta, ligation of the subpulmonary outflow, and an RV-to-PA conduit, which is typically valved. Modifications of this procedure are also used in patients with variations of double-outlet right ventricle. Although the procedure has perioperative and short-term morbidity and mortality risks that are acceptably low, conduit calcification, valve dysfunction, LVOT obstruction, and residual VSDs confer a high likelihood of reoperation within the first 2 decades of life.<sup>1,6-9</sup> The operation also has associated long-term risks for arrhythmia (38% within a median 24 years) and heart failure (with a high prevalence of RV systolic and diastolic dysfunction), and an increased risk for infective endocarditis.<sup>1,2,10-12</sup>

Alternatives to the Rastelli operation include the réparation à l'étage ventriculaire and Nikaidoh procedures.<sup>11,13-17</sup> Réparation à l'étage ventriculaire comprises VSD enlargement and a baffle to direct LV flow to the aorta, aortic transection to perform a Lecompte maneuver, and direct RVOT reconstruction using an anterior patch, resulting in pulmonary insufficiency.<sup>11,18</sup> The Nikaidoh procedure, or aortic translocation repair, involves aortic root mobilization, transection of the PA, resection of the subpulmonary stenosis, and division of the pulmonary annulus that opens the LVOT. The LVOT is reconstructed by repositioning the aortic root posteriorly, closing the VSD, suturing the posterior wall of the

**TABLE 38 Patients With d-TGA and Rastelli Operation: Routine Follow-Up and Testing Intervals**

Type of Follow-Up or Testing	Physiological Stage A* (mo)	Physiological Stage B* (mo)	Physiological Stage C* (mo)	Physiological Stage D* (mo)
Outpatient ACHD cardiologist	N/A	12-24	12	3-6
Electrocardiogram	N/A	12-24	12	12
Transthoracic echocardiogram	N/A	12-24	12	12

For recommendations about timing of cardiac CT and CMR imaging, see supportive text for recommendation #1.

\*See Section 2.2 for details on the ACHD anatomic and physiological classification system.

ACHD indicates adult congenital heart disease; d-TGA, dextro-transposition of the great arteries; and N/A, not applicable.

aortic root to the open pulmonary annulus, and reconstructing the RVOT with a pericardial gusset.<sup>14</sup> The Nikaidoh procedure may be complicated by RVOT obstruction, pulmonary regurgitation, neoaortic insufficiency, or coronary stenosis.<sup>9,11,15,19</sup>

**Recommendation-Specific Supportive Text**

1. Degeneration of a Rastelli conduit is common and drives a high reoperation/reintervention rate in patients with d-TGA and Rastelli repair. Conduit stenosis and/or insufficiency have consequences similar to those for pulmonary stenosis and pulmonary regurgitation (see Section 4.3.7, “Management of Right Ventricle-to-Pulmonary Artery Conduits”) and require regular follow-up. Transthoracic echocardiography can have difficulty visualizing Rastelli conduits, and direct echocardiographic interrogation of the conduit should be combined with indirect signs of RV pressure or volume overload (estimation of RV pressure by tricuspid regurgitation velocity, RV hypertrophy, or RV dilatation) and assessment of RV function. CMR can provide valuable information on the RVOT and LVOT and should be repeated every 3 to 5 years in asymptomatic patients with no significant stenosis or regurgitation of the conduit and otherwise every 1 to 3 years. Cardiac CT angiography can also provide anatomic information on the conduit, as well as the position of the coronary arteries, and should be performed when planning intervention or when echocardiography and CMR have not provided adequate anatomic information.<sup>20</sup> (See Table 38 for details on routine testing and follow-up.) Patients are prone to infective endocarditis, which may involve the conduit, LVOT, or residual VSD patch material or percutaneous pulmonary valve.<sup>21-23</sup> Physicians must be aware of the potential for infective endocarditis to cause rapidly progressive conduit stenosis in these patients, requiring early recognition and immediate intervention.

## 4.4.2. Management of CCTGA

**Recommendations for Management of CCTGA**  
Referenced studies that support recommendations are summarized in the [Evidence Table](#).

COR	LOE	RECOMMENDATIONS
<b>Diagnostic</b>		
1	B-NR	1. In adults with congenital CCTGA, periodic* transthoracic echocardiography is recommended to assess chamber function, systemic tricuspid valve function, and associated anatomic lesions such as septal defects and LVOT stenosis. <sup>1-3</sup>
2a	B-NR	2. In adults with CCTGA, periodic cross-sectional imaging (preferably, CMR) is reasonable to assess systemic ventricular volumes and function, quantify the severity of systemic tricuspid regurgitation, and assess the severity of associated anatomic lesions. <sup>2-4</sup>
2a	B-NR	3. In adults with CCTGA without symptoms, periodic ambulatory rhythm monitoring is reasonable to screen for high-grade atrioventricular block. <sup>5-7</sup>
<b>Therapeutic</b>		
1	B-NR	4. In symptomatic adults with CCTGA, severe systemic tricuspid regurgitation, and normal or mildly impaired RV systolic function, surgical tricuspid valve replacement is recommended to relieve symptoms and preserve RV function. <sup>3,8,9</sup>
2a	B-NR	5. In asymptomatic adults with CCTGA, severe systemic tricuspid regurgitation, and normal or mildly impaired RV systolic function, surgical tricuspid valve replacement is reasonable to preserve RV systolic function. <sup>3,8,9</sup>

*continued in the next column*

## Continued

COR	LOE	RECOMMENDATIONS
2a	B-NR	6. In symptomatic adults with CCTGA and high-grade atrioventricular block, physiological pacing (CRT or conduction system pacing) is reasonable to relieve symptoms. <sup>5,10</sup>
2b	B-NR	7. In adults with CCTGA and heart failure with RV dysfunction, the use of GDMT may be reasonable to improve ventricular function and functional capacity. <sup>11,12</sup>
2b	B-NR	8. In symptomatic adults with CCTGA and severe LVOT stenosis, surgical or transcatheter therapy to relieve LVOT obstruction may be considered to improve symptoms and preserve LV systolic function while accounting for the potential risk of worsening the severity of tricuspid regurgitation. <sup>13</sup>

\*See [Table 39](#) for details on the periodicity of testing.

**Synopsis**

CCTGA is characterized by atrioventricular and ventriculoarterial discordance, resulting in the right ventricle as the systemic ventricle.<sup>14</sup> The right ventricle is not optimally adapted for the systemic circulation because of its thin wall and a single coronary artery blood supply, leading to RV systolic dysfunction in many patients with CCTGA.<sup>1-3</sup> More than 80% of patients with CCTGA have associated structural heart lesions, such as tricuspid valve dysplasia (Ebstein-like anomaly), VSD, and LVOT obstruction.<sup>1-3</sup> Those lesions lead to volume and pressure overload of the different cardiac chambers, eventually resulting in cardiac remodeling, heart failure, and cardiovascular mortality.<sup>1-3</sup> The common surgical management strategy for adults with unrepaired CCTGA is physiological repair, which aims to address specific hemodynamic lesions such as systemic tricuspid regurgitation or LVOT stenosis. However, anatomic repair (the combination of atrial switch operation and arterial switch operation) may be a viable strategy in selected patients.<sup>15</sup>

Patients with CCTGA also are at risk for high-grade atrioventricular block because of the abnormal position of the underlying conduction system, as well as for atrial

and ventricular arrhythmias related to cardiac remodeling from hemodynamic lesions.<sup>5-7,10</sup> Patients with high-grade atrioventricular block require cardiac pacing. However, ventricular pacing of the subpulmonary left ventricle may exacerbate systemic ventricular dysfunction and heart failure.<sup>3,5,10</sup> Limited data indicate that pacing-induced ventricular dysfunction and worsening heart failure can be prevented by physiological pacing (CRT or conduction system pacing).<sup>5,10</sup> Comprehensive evaluation—cardiac imaging,<sup>1-3</sup> rhythm monitoring,<sup>5,10</sup> CPET,<sup>4,9,16,17</sup> and biomarker assay (such as NT-proBNP) are required to identify and characterize all structural and functional lesions and rhythm abnormalities, before choosing optimal therapy (Table 39). Management options include surgical or transcatheter valve intervention by an operator with ACHD expertise, medical therapy for heart failure, physiological pacing, and exercise training.<sup>11,12,18</sup>

**Recommendation-Specific Supportive Text**

1. Systemic RV systolic dysfunction and subpulmonic LV systolic dysfunction are common in adults with CCTGA, with prevalences of 50% to 80% and 11% to 40%, respectively.<sup>1-3</sup> The presence of RV and/or LV systolic dysfunction is associated with increased risk for cardiovascular mortality.<sup>1-3</sup> Adults with CCTGA also have biatrial remodeling and dysfunction, which can further exacerbate atrial arrhythmias and heart failure.<sup>1-3</sup> In addition, adults with CCTGA commonly have valvular and outflow lesions (especially systemic tricuspid regurgitation and LVOT stenosis), further exacerbating chamber remodeling and heart failure. Comprehensive transthoracic echocardiogram (2-dimensional Doppler and speckle tracking) should be performed to assess chamber and valve function.<sup>1-3</sup>
2. CMR imaging can be used to assess RV volume and ejection fraction and to quantify the volume of system tricuspid regurgitation. It can also be used to assess LVOT (or left ventricle to PA conduit) anatomy and the relationship to neighboring structures, such as coronary arteries.<sup>2-4</sup> In patients with pacemakers or other contraindications to CMR, CT may be a reasonable alternative. The severity of tricuspid regurgitation or RV systolic dysfunction will determine the frequency of CMR imaging. CMR can be obtained every 3 to 5 years in patients with less than moderate RV systolic dysfunction or tricuspid regurgitation, and every 1 to 3 years in patients with moderate or greater RV systolic dysfunction or tricuspid regurgitation.
3. High-grade atrioventricular block is common in patients with CCTGA, owing to inherent structural abnormalities of the atrioventricular conduction system.

**TABLE 39** Congenitally Corrected Transposition of the Great Arteries: Routine Follow-Up and Testing Intervals

Type of Follow-Up or Testing	Physiological Stage A* (mo)	Physiological Stage B* (mo)	Physiological Stage C* (mo)	Physiological Stage D* (mo)
Outpatient ACHD cardiologist	N/A	12	12	6
Electrocardiogram	N/A	12	12	12
Transthoracic echocardiogram	N/A	12	12	12

For recommendations regarding CMR and cardiac CT, see supportive text for recommendation #2. For recommendations regarding ambulatory rhythm monitoring, see supportive text for recommendation #3.

Modified with permission from Stout et al.<sup>19</sup> Copyright 2018 American Heart Association, Inc. and American College of Cardiology Foundation.

\*See Section 2.2 for details on the ACHD anatomic and physiological classification system.

ACHD indicates adult congenital heart disease; CMR, cardiovascular magnetic resonance; CT, computed tomography; and N/A, not applicable.

- The use of antiarrhythmic drug therapy to manage atrial arrhythmias in this population can further exacerbate chronotropic incompetence and atrioventricular block. Ambulatory rhythm monitoring can identify patients with asymptomatic conduction system disease, who may benefit from an electrophysiologist’s evaluation of whether cardiac pacing is required.<sup>5</sup> In patients without preexisting conduction system disease, performing ambulatory rhythm monitoring every 5 years is reasonable to monitor for new-onset atrioventricular block. In patients with preexisting conduction system disease who currently do not have pacemakers, the frequency of ambulatory rhythm monitoring should be based on symptoms or severity of atrioventricular block.
4. Systemic tricuspid regurgitation is common in adults with CCTGA, owing to underlying tricuspid valve dysplasia and further exacerbated by tricuspid annular dilation from systemic RV dilation and dysfunction. The severity of tricuspid regurgitation tends to progress, prompting a need for tricuspid valve surgery to preserve systemic RV function. Tricuspid valve replacement with a mechanical prosthesis offers the best prospect for long-term outcomes. Tricuspid valve repair or replacement with a bioprosthesis has limited durability and, thus, is less suitable for this population; however, it may be appropriate in selected cases, such as when anticoagulation with a vitamin K antagonist is contraindicated or not desired.<sup>3,8</sup>
  5. Postoperative recovery of RV systolic function is more likely when the tricuspid valve is replaced before the onset of significant RV systolic dysfunction.<sup>3,8</sup> Residual RV systolic dysfunction after tricuspid valve replacement is associated with cardiovascular events and has not been shown to respond consistently to GDMT for heart failure.<sup>3,8</sup> Hence, tricuspid valve

**TABLE 40** Truncus Arteriosus: Routine Follow-Up and Testing Intervals

Type of Follow-Up or Testing	Physiological Stage A* (mo)	Physiological Stage B* (mo)	Physiological Stage C* (mo)	Physiological Stage D* (mo)
Outpatient ACHD cardiologist	N/A	12	3-6	3-6
Electrocardiogram	N/A	12	6-12	6-12
Transthoracic echocardiogram	N/A	12	6-12	6-12

\*See Section 2.2 for details on the ACHD anatomic and physiological classification system. ACHD indicates adult congenital heart disease; and N/A, not applicable.

replacement is reasonable in asymptomatic patients with severe tricuspid regurgitation and normal or mildly impaired RV systolic function (RV ejection fraction 40% to 50%) to prevent progressive RV dysfunction.

- Cardiac pacing is recommended in patients with symptomatic bradycardia to relieve symptoms. However, LV pacing is associated with systemic RV systolic dysfunction that may be acute or progressive. Data supporting the role of physiological pacing (CRT or conduction system pacing) in adults with CCTGA remain limited. However, evidence shows that physiological pacing prevents pacing-induced systemic ventricular dysfunction and, therefore, physiological pacing is the preferred therapy when technically feasible in patients who require cardiac pacing.<sup>5,10</sup> Similarly, patients who already receive LV pacing may be considered for an upgrade to CRT if they are being paced more than 40% of the time.
- Data are limited to support the role of GDMT to manage heart failure in adults with CCTGA and RV systolic dysfunction. A recent study suggests that use of an angiotensin-receptor neprilysin inhibitor may improve ventricular systolic function, heart failure symptoms, and neurohormonal activation.<sup>11</sup> Given that GDMT is effective in treating LV systolic dysfunction, it may be considered in patients with CCTGA who have LV systolic dysfunction, which is an independent risk factor for adverse cardiovascular outcomes and can accelerate progression of RV systolic dysfunction.<sup>11,12</sup> Patients who do not respond to GDMT should be referred for evaluation for advanced heart failure therapies.

8. LVOT stenosis (both valvular and subvalvar) is a common structural lesion in patients with CCTGA. Severe LVOT stenosis can lead to LV systolic/diastolic dysfunction and heart failure. Surgical or transcatheter interventions to relieve LVOT stenosis, by an operator with ACHD expertise, may be considered in patients with progressive LV dysfunction and heart failure, after excluding other potential causes of the symptoms. There is a theoretical risk that relief of LVOT stenosis would cause progressive tricuspid regurgitation by altering ventricular septal geometry. That risk should be discussed with the patient as part of a risk-benefit analysis.<sup>13</sup> Partial relief of LVOT stenosis may be considered to preserve ventricular septal geometry.

#### 4.4.3. Truncus Arteriosus

##### Synopsis

Truncus arteriosus, a rare cyanotic cardiac defect, results from the failure of septation of the common truncus arteriosus into the aorta and PAs. Usually repaired in the neonatal period, the defect can be associated with pulmonary hypertension if repair is delayed<sup>1</sup> and, rarely, can manifest in adulthood with PAH and cyanosis due to pulmonary vascular obstructive disease.

Surgical repair of truncus arteriosus involves separation of the PAs or pulmonary arterial trunk from the single arterial trunk, closure of the VSD, and establishment of an unobstructed pathway from the right ventricle to the PA.<sup>2</sup> Associated conditions such as truncal valve insufficiency, interrupted aortic arch, and coronary anomalies can influence near-term surgical outcomes and long-term clinical outcomes.<sup>3,4</sup> Chromosome 22q11 deletion is common, especially in patients with aortic arch anomalies, including right aortic arch,<sup>5</sup> and merits genetic testing if present. Excluding mortality in infancy, survival rates exceed 90% at 20 years.<sup>3,4</sup>

Reintervention for the RV-to-PA pathway is nearly inevitable, with a cumulative incidence rate of 95.4% at 20 years.<sup>6</sup> Neoaortic insufficiency is the second-most common indication for reintervention.<sup>4</sup> Neoaortic dilation is frequently observed but may not require intervention unless it progresses rapidly or is accompanied by significant neoaortic insufficiency. Recommendations for assessment and management of truncus arteriosus can generally be inferred from those for RV-to-PA conduit,

VSD, and aortic valve disease. See [Table 40](#) for suggested routine testing and follow-up intervals for patients with truncus arteriosus repair.

#### 4.4.4. Double-Outlet Right Ventricle

##### Synopsis

Double-outlet right ventricle is an anatomic term that refers to abnormalities in which a patient has a VSD, occasionally with mitral-aortic discontinuity (in those with malposition), with both great arteries arising primarily from the morphologic right ventricle. The exact anatomy varies significantly: Some cases can approximate TOF in patients where the aorta is not malposed but emerges predominantly from the right ventricle, whereas other cases most closely approximate d-TGA, with the aorta anteriorly dextroposed and the PA more closely related to the VSD.<sup>1</sup>

Initial surgical repairs depend on the underlying anatomy and involve the creation of a left ventricle to aorta baffle through the VSD or, in some cases, translocation of the aorta; relief of pulmonary stenosis if present; RV-to-PA conduit placement if necessary; or Rastelli-type repair ([Table 41](#)).<sup>2,3</sup> Therefore, recommendations for the management of an individual adult with repaired double-outlet right ventricle should align with the recommendations for lesions with similar anatomy and surgical treatment (eg, TOF with RV-to-PA conduit or d-TGA with arterial switch). Complex anatomy—defined by the presence of atrial isomerism, AVSD, multiple VSDs, hypoplastic right or left ventricles, straddling atrioventricular valves, and major PA anomalies—further dictates the surgical treatment strategy, including the likelihood of success with biventricular versus univentricular repair.

LVOT obstruction may occur, and indications for surgical management could be similar to those with other forms of LVOT obstruction. However, given the potential complexity of reoperations for baffle obstructions, the decision to reoperate for LVOT obstruction should involve the surgical team and carefully weigh the individual risk-benefit ratio of reoperation.<sup>4</sup> Careful interrogation for patch leaks along the VSD repair should be performed routinely.

Finally, in patients with double-outlet right ventricle and a hypoplastic ventricle with single-ventricle physiology who have undergone Fontan palliation, management should be similar to that for patients with other forms of single-ventricle physiology with a Fontan.

**TABLE 41** Surgical Management Options for Types of Double-Outlet Right Ventricle

Type of Double-Outlet Right Ventricle Physiology	Surgical Management Options
Ventricular septal defect type with double-outlet right ventricle	Left ventricle to aorta intracardiac baffle
Tetralogy of Fallot type with pulmonary stenosis or atresia	Left ventricle to aorta intracardiac baffle with right ventricular outflow tract reconstruction or right ventricle to pulmonary artery conduit
Dextro-transposition of the great arteries type	Arterial switch operation with closure of ventricular septal defect; Rastelli-type repair; aortic translocation
Hypoplastic ventricle with single-ventricle type physiology	Fontan operation

#### 4.4.5. Fontan Palliation of Single-Ventricle Physiology

**Recommendations for Fontan Palliation of Single-Ventricle Physiology**  
 Referenced studies that support recommendations are summarized in the [Evidence Table](#).

COR	LOE	RECOMMENDATIONS
<b>Diagnostic</b>		
1	B-NR	1. In adults with Fontan circulation and evidence of progressive Fontan circulatory failure, formal evaluation by a heart failure/transplant cardiologist with experience in heart transplantation in the adult Fontan population is recommended. <sup>1,2</sup>
1	C-LD	2. In adults with Fontan circulation, imaging and laboratory evaluation of the liver should be performed at least annually to screen for hepatocellular carcinoma and for evidence of progressive Fontan-associated liver disease (FALD). <sup>3,4</sup>
1	C-EO	3. In adults being considered for Fontan palliation or Fontan conversion, cardiac catheterization should be performed to ensure the presence of acceptable hemodynamics.
1	C-EO	4. In adults with Fontan circulation and new-onset or worsening atrial tachyarrhythmias, evaluation with imaging and follow-up cardiac catheterization as indicated is recommended to assess for potential contributory anatomic or hemodynamic abnormalities and Fontan-pathway thrombosis.

Continued on the next page

Continued		
COR	LOE	RECOMMENDATIONS
1	C-EO	5. In adults with Fontan circulation and new or progressive symptoms, hypoxemia, declining functional status, or evidence of progressive or new-onset noncardiac organ dysfunction, hemodynamic evaluation with cardiac catheterization is recommended to guide therapy.
1	C-EO	6. In adults with Fontan circulation and newly progressive or severe hypoxemia or hypotension, evaluation with advanced cardiac imaging (MR, CT, transesophageal echocardiography) is recommended to rule out thrombus or emboli in the Fontan or pulmonary vasculature.
1	C-EO	7. In adults with Fontan circulation undergoing CT angiography to rule out thrombus or emboli in the Fontan or pulmonary vasculature, imaging should be performed using protocols to avoid false-negative or false-positive results.
1	C-EO	8. In adults with Fontan circulation, annual laboratory evaluation is recommended to assess for evidence of organ-system dysfunction or hematologic abnormality.
2a	C-EO	9. In adults with Fontan circulation, consultation by a hepatologist, in collaboration with an ACHD cardiologist, is reasonable to facilitate interpretation of hepatic testing, diagnose and treat complications related to portal hypertension, and participate in timing and management decisions specific to organ transplantation.
2a	C-LD	10. In adults with Fontan circulation, liver biopsy can be helpful to delineate the degree of hepatic fibrosis or cirrhosis before consideration of transplantation. <sup>5</sup>

continued in the next column

Continued		
COR	LOE	RECOMMENDATIONS
2b	C-LD	11. In adults with Fontan circulation undergoing cardiac catheterization (diagnostic, interventional, or electrophysiological), it may be reasonable to exclude Fontan-related thrombus before catheter placement to avoid pulmonary or systemic thromboembolism. <sup>6</sup>
<b>Therapeutic</b>		
1	B-NR	12. In adults with Fontan circulation and a known or suspected thrombus, atriopulmonary Fontan, a history of thromboembolism, or a history of sustained atrial flutter or fibrillation, anticoagulation is recommended to reduce the likelihood of thromboembolic disease. <sup>7</sup>
1	B-NR	13. In adults with Fontan circulation and the absence of high-risk features (history of thromboembolism, sustained atrial flutter/fibrillation, or atriopulmonary Fontan) or bleeding contraindications, treatment with either aspirin or anticoagulation is recommended to reduce the probability of thromboembolic disease. <sup>8,9</sup>
1	B-NR	14. In adults with Fontan circulation and sinus node dysfunction requiring pacemaker placement, atrial-based pacing with programming to minimize ventricular pacing is recommended to improve patient symptoms and to avoid pacing-induced cardiomyopathy. <sup>10</sup>
1	C-LD	15. In adults with Fontan circulation with new-onset atrial flutter or atrial fibrillation, timely cardioversion (pharmacological or electrical) is recommended to prevent clinical decompensation. <sup>11</sup>

Continued on the next page

Continued		
COR	LOE	RECOMMENDATIONS
1	C-EO	16. Adults with Fontan circulation referred for cardiac transplantation should undergo pretransplantation review by a committee with broad multidisciplinary representation to improve patient selection and posttransplant outcomes.
2a	B-NR	17. In adults with Fontan circulation and atrioventricular block whose burden of ventricular pacing is likely to be high (ie, >40%), apical site pacing is preferred over non-apical sites to improve transplant-free survival. <sup>12,13</sup>
2a	B-NR	18. In adults with Fontan circulation, formal exercise programs and/or cardiac rehabilitation (appropriate to the patient's ability) can be beneficial in improving functional capacity. <sup>14,15</sup>
2a	C-LD	19. In adults with Fontan circulation and recurrent supraventricular tachycardia, catheter ablation performed by an electrophysiologist with experience in ACHD is reasonable to reduce arrhythmia recurrence and associated morbidity. <sup>16,17</sup>
2a	C-EO	20. In adults with Fontan circulation and hemodynamically significant stenosis of the Fontan or PAs, catheter-based stenting of the stenosis to reduce Fontan pressure and improve flow is reasonable to improve hemodynamics.
2a	C-EO	21. In symptomatic adults with Fontan circulation, or those with evidence of systemic ventricular volume overload, closure of aortopulmonary collaterals to improve symptoms and reduce the likelihood of pathologic ventricular remodeling can be useful.

*continued in the next column*

Continued		
COR	LOE	RECOMMENDATIONS
2b	B-R	22. In adults with Fontan circulation, treatment with pulmonary vasodilators may be considered to improve exercise capacity. <sup>18,19</sup>
2b	C-LD	23. In adults with an atriopulmonary Fontan, preserved ventricular function, and acceptable surgical risk with atrial arrhythmias refractory to medical and catheter-based therapies, Fontan conversion surgery may be considered to reduce arrhythmia recurrence. <sup>20,21</sup>
2b	C-EO	24. In adults with Fontan circulation and symptoms or Fontan circulatory failure attributable to significant intracardiac structural or anatomic abnormalities, reoperation may be considered to improve symptoms or reduce the likelihood of progressive Fontan circulatory failure.

### Synopsis

The Fontan procedure allows systemic venous blood to flow to the pulmonary arteries in the absence of a sub-pulmonic ventricle and is used to palliate a variety of forms of single-ventricle congenital heart disease. The Fontan circulation is defined by obligate systemic venous hypertension and low cardiac output. Years of exposure to Fontan circulation can culminate in a multisystem disease state manifesting in different phenotypes of circulatory failure<sup>22</sup> and noncardiac disease.

Management of adults with Fontan circulation focuses on recognizing lesions or physiological states that can accelerate Fontan circulatory failure, while addressing symptoms, and should be performed in a multidisciplinary setting. Routine cardiac evaluation and surveillance of systems affected by Fontan circulation, especially the liver, is necessary for early recognition of organ dysfunction. Routine referral to hepatology, and to other subspecialists as needed, is recommended. Medical treatment options with evidence of efficacy are sparse and limited to thromboprophylaxis. Treatment of arrhythmia and structured exercise programs may offer

**TABLE 42** Fontan Palliation: Routine Follow-Up and Testing Intervals

Type of Follow-Up or Testing	Physiological Stage A* (mo)	Physiological Stage B* (mo)	Physiological Stage C* (mo)	Physiological Stage D* (mo)
Outpatient ACHD cardiologist	N/A	12	6-12	3-6
Electrocardiogram	N/A	12	6-12	6-12
Transthoracic echocardiogram	N/A	12	12	6-12

For recommendations about timing of CMR imaging, see Section 4.4.5 supportive text for recommendations #6 and #7. For recommendations about timing of liver imaging, see Section 4.4.5 supportive text for recommendation #2.

Modified with permission from Stout et al.<sup>92</sup> Copyright 2018 American Heart Association, Inc. and American College of Cardiology Foundation.

\*See Section 2.2 for details on the ACHD anatomic and physiological classification system.

ACHD indicates adult congenital heart disease; CMR, cardiovascular magnetic resonance; and N/A, not applicable.

benefit. Catheter-based interventions may be of benefit in the setting of Fontan pathway obstruction. In patients with evidence of Fontan circulatory failure, early referral to cardiac heart failure/transplant programs with expertise in advanced cardiac therapies in the Fontan population is recommended.

Table 42 describes routine follow-up testing and intervals.

**Recommendation-Specific Supportive Text**

1. The ideal timing of referral for transplantation in adults with Fontan circulation remains uncertain. The diversity of phenotypes of Fontan circulatory failure complicates the establishment of pertinent criteria, and no singular definition of Fontan circulatory failure is widely accepted. Dysfunction of the Fontan circulation that results in an inability to carry out daily activities,<sup>23</sup> along with the presence of dysfunction of organ systems affected by Fontan circulation,<sup>24</sup> are important elements of Fontan circulatory failure and should inform decision making about the timing of transplantation. Accumulating data suggest that outcomes are worse with additional time to referral after the onset of progressive Fontan circulatory failure<sup>1</sup> and/or multiorgan dysfunction.<sup>2,25</sup> Consequently, it is necessary for clinicians caring for this population to actively surveil for evidence of cardiac and noncardiac organ dysfunction that can impact transplant listing and posttransplant outcomes including, but not limited to, ventricular dysfunction, Fontan pathway dysfunction, lymphatic dysfunction, and noncardiac organ dysfunction such as renal and/or hepatic disease.<sup>26</sup> Referral for evaluation for transplantation is

recommended in patients with evidence of Fontan circulatory failure, before the onset of multiorgan dysfunction, to minimize the likelihood of listing denial and/or posttransplant morbidity and to allow for multidisciplinary discussion about optimal timing of transplantation. Select patients may benefit from early referral to heart failure providers to help address potential barriers to transplantation including obesity, social obstacles, and/or substance use. The decision to proceed with transplantation should be made on a patient-by-patient basis by a multidisciplinary team with expertise in advanced cardiac therapies in patients with Fontan circulation, detailed data on each patient, and sufficient knowledge of the capabilities and expertise of the treating center.

2. Patients with Fontan circulation have an increased risk for liver cirrhosis and hepatocellular carcinoma, so they require active surveillance, particularly >10 years after completion of Fontan palliation.<sup>4</sup> However, there are conflicting data on risk factors for the development of liver cirrhosis and/or hepatocellular carcinoma.<sup>3,27,28</sup> Given the risk associated with hepatocellular carcinoma and the importance of early diagnosis,<sup>3,29,30</sup> all adults with Fontan circulation should undergo hepatic screening with imaging at least yearly. Serologic evaluation of hepatic function, including alpha-fetoprotein levels, may provide additional diagnostic information beyond routine imaging, and should be obtained at least yearly. Decisions about imaging modality should be tailored according to each patient’s risk for hepatocellular carcinoma and/or cirrhosis, as well as their current clinical state, and may need to be modified over time. Liver MR imaging offers advantages in characterizing liver nodules<sup>31</sup> and in quantifying the degree of hepatic fibrosis, without the need for ionizing radiation.<sup>27,32</sup> Because noninvasive assessment of liver stiffness using elastography may overestimate the degree of liver fibrosis in the Fontan population secondary to venous hypertension, results must be interpreted cautiously.<sup>33</sup> Patients with imaging or clinical evidence of liver cirrhosis may benefit from more frequent imaging (at least every 6 months) to ensure early detection of hepatocellular carcinoma. Patients with significant hepatic fibrosis or focal liver lesions should be followed by hepatologists with experience in FALD to facilitate patient-specific surveillance protocols and interpretation of results.

3. Before Fontan completion or Fontan revision in adults, hemodynamic assessment to assess the pulmonary circulation and function of the single ventricle is important in evaluation of the patient's candidacy for the procedures.
4. Atrial arrhythmias occur in more than 60% of adults with Fontan circulation and are a significant source of morbidity and mortality.<sup>34,35</sup> Hemodynamic abnormalities secondary to ventricular dysfunction, valvular disease, outflow tract obstruction, thrombosis, or progressive narrowing or obstruction of the Fontan pathway have the potential to aggravate underlying anatomic and electrophysiologic substrates for arrhythmia in adults with Fontan circulation.<sup>36</sup> Consequently, new-onset or a progressive burden of atrial tachyarrhythmias warrants an extensive evaluation that includes imaging assessment, to ensure the absence of potentially treatable contributing factors and to re-evaluate the patient for progressive Fontan circulatory failure. Invasive hemodynamic assessment may be indicated in individuals with evidence of structural lesions on imaging, with a potential association with the arrhythmia.
5. Clinical examination and noninvasive imaging may be insufficient to accurately assess Fontan hemodynamics. Consequently, invasive hemodynamic assessment by a provider with expertise in single-ventricle congenital heart disease may be necessary for a patient with new-onset or progressive decompensation. Decompensation may manifest as worsening symptomatology or dysfunction of organ systems affected by Fontan circulation, including new or progressive hepatic disease, renal disease, lymphatic dysfunction, respiratory decompensation or hemoptysis, and/or stroke or neurocognitive decline. Hemodynamic and angiographic assessment provides essential diagnostic data including, but not limited to, quantification of Fontan, pulmonary, and ventricular pressures; anatomic assessment of the Fontan pathway and pulmonary vascular tree; identification of arteriovenous malformations; quantification of veno-venous and/or aortopulmonary collaterals and the degree of associated shunting; and delineation of pulmonary and systemic vascular resistance.
6. Thrombotic complications are common in patients with Fontan circulation, secondary to a variety of mechanisms that include endothelial dysfunction, venous stasis, disruption of normal clotting mechanisms, and hepatic dysfunction. Consequently, new-onset or progressive hypotension or hypoxemia or acute liver congestion requires urgent evaluation for thromboembolic disease of the Fontan pathway. Transthoracic echocardiography is not sufficient to adequately delineate the Fontan pathway to rule out thrombus.<sup>37,38</sup> Transesophageal echocardiography, cardiac CT angiography, or CMR are preferred and should be performed and interpreted by experts in assessing the Fontan pathway.
7. Optimal opacification of the Fontan pathway with CT angiography is complicated by the unique anatomy and hemodynamics of adults with Fontan circulation. Because blood flow from the Fontan pathway and the Glenn pathway may preferentially favor one PA over the other, streaming artifact from the incomplete mixture of opacified blood (from the contrast injection site) and unopacified blood (from venous return from a noninjection site) may inadvertently appear to represent a filling defect. Several methodologies have been proposed to circumvent this issue, including dual injection (from the upper and lower extremities)<sup>39</sup> and/or multiple phases of image acquisition.<sup>40</sup> In the interest of accuracy, all CT angiographies performed to evaluate for thrombus or emboli in adults with Fontan circulation should be protocolized and interpreted by radiologists who are familiar with the specific patient's anatomy or in consultation with a regional ACHD center in emergent situations when individuals with such expertise are not available locally.
8. Annual laboratory evaluation is reasonable to assess for evidence of organ-system dysfunction or hematologic abnormality in the setting of Fontan circulation. Routine evaluation of renal function is important in adults with Fontan circulation, given the risk for progressive kidney dysfunction. Cystatin C may be a more robust measurement of renal function than creatinine in this population.<sup>41</sup> Periodic hematologic evaluation is important to screen for thrombocytopenia, a potential consequence of progressive FALD; for erythrocytosis associated with chronic hypoxemia; and for lymphopenia associated with protein-losing enteropathy. Serial assessment of NT-proBNP may facilitate early detection of deterioration in cardiac function. Albumin should be assessed routinely to screen for protein-losing enteropathy, with follow-up testing to include 24-hour stool alpha-1 antitrypsin clearance when indicated. Routine assessment of iron studies—including serum iron, total iron-binding capacity, and ferritin—is helpful in identifying iron deficiency, particularly in patients with Fontan circulatory failure.<sup>42</sup>
9. Adults with Fontan circulation require multidisciplinary care across specialties with expertise in organs affected by Fontan circulation. Given the potential morbidity and mortality associated with FALD-related complications, routine evaluation by a hepatologist is reasonable to facilitate interpretation

- of imaging and pathology, define patient-specific surveillance protocols, screen for and manage sequelae of FALD-associated portal hypertension, and participate in treatment decisions about the timing of and need for combined heart-liver transplantation when applicable. Hepatology evaluation of adults with Fontan circulation is also important to ensure that non-Fontan-specific factors (ie, infections, hepatic toxic medications, or exposures) are not contributing to hepatic disease.
10. Liver biopsy is considered to be the gold standard for assessing the degree of liver fibrosis in FALD.<sup>31,43</sup> Nonetheless, biopsy has several limitations, including bleeding and other procedural complications, and an inherent risk for sampling error secondary to the patchy nature of FALD.<sup>44</sup> Despite those limitations, liver biopsy is recommended when precise delineation of the degree of fibrosis can influence treatment decisions. This information is relevant when heart transplantation is being considered, to facilitate decisions about the risk-benefit ratio of combined heart-liver transplantation. Liver biopsy may also be helpful if non-FALD etiologies of liver disease are being considered. Given the lack of correlation between liver fibrosis and clinical outcomes in published studies, routine liver biopsy for FALD surveillance remains controversial and should be discussed in consultation with hepatology on a patient-by-patient basis when biopsy results have the potential to affect non-transplant-related treatment recommendations.<sup>5</sup>
  11. The prevalence of Fontan-associated thrombus is high, particularly in patients with evidence of Fontan circulatory failure. Transthoracic imaging is inadequate for ruling out the presence of Fontan-associated thrombus. Consequently, before catheter placement, additional imaging with transesophageal echocardiography, CT angiography or CMR may be reasonable, to ensure that thrombus is not present and reduce the likelihood of catheter-induced embolization.
  12. Patients with a history of sustained (>30 s) atrial flutter or fibrillation,<sup>7,45</sup> prior thrombus and/or thromboembolic disease, or cerebrovascular accident—or those who have atriopulmonary Fontan<sup>46,47</sup>—represent a high-risk cohort and require treatment with anticoagulation unless otherwise contraindicated.<sup>46</sup> Given a lack of clinical trials, data are limited to inform the choice of anticoagulation agent for secondary prevention in adults with Fontan circulation. Recent small studies and meta-analyses have shown comparable results, for both prophylaxis and bleeding risk, between warfarin and non-vitamin K oral anticoagulants<sup>8,9,48</sup> in patients with Fontan circulation without a history of thromboembolic disease; however, data comparing efficacy across agents are lacking.
  13. Antithrombotic prophylaxis is recommended to reduce the probability of thromboembolic disease in adults with Fontan circulation without bleeding contraindications.<sup>9,49,50</sup> For primary prevention in patients without a history of sustained atrial arrhythmia (>30 s), prior thrombus and/or thromboembolic disease, cerebrovascular accident, or atrio-pulmonary Fontan, there is a lack of evidence to suggest treatment superiority for antiplatelet agents versus anticoagulants in adults with Fontan circulation.<sup>8,9,48,51</sup> Limited data suggest that oral anticoagulants may slightly reduce the risk for thromboembolic events<sup>8</sup> but at the possible expense of higher risk for bleeding.<sup>52</sup> Data pertaining to additional anatomic and physiologic risk factors are sparse. Some factors may include significant right-to-left shunting,<sup>53</sup> conduits used to deviate hepatic flow to the PA in patients with a previous Kawashima procedure,<sup>47</sup> and the presence of a transvenous pacemaker system.<sup>54</sup> The risk for thromboembolism associated with those factors, and the degree to which that risk is mitigated by medication, remains uncertain.
  14. Ventricular pacing in adults with Fontan circulation can lead to significant decline in ventricular function and is associated with adverse outcomes.<sup>10,55-57</sup> Sinus node dysfunction is common after Fontan palliation.<sup>58</sup> Loss of atrial rhythm—which is associated with decreased ventricular preload, pulmonary venous flow reversal, and a decrease in functional status—may result in chronotropic incompetence, tachy-brady syndromes, or symptomatic bradycardia. Additional hemodynamic alterations, including worsened atrioventricular valve function or poor ventricular relaxation, can also occur. Patients with symptomatic sinus node dysfunction should be evaluated by an electrophysiologist who has experience in device therapy in adults with Fontan circulation and who can offer advice on indications for placement of a permeant device, the device type, and the mode of lead placement. When a device is placed, device programming should maximize atrial pacing and minimize ventricular pacing.
  15. Atrial arrhythmias can occur in up to 60% of adults with Fontan circulation and are associated with significant morbidity and mortality.<sup>59,60</sup> Acute cardioversion of new-onset atrial flutter/intra-atrial re-entrant tachycardia or atrial fibrillation can be performed safely and is recommended to prevent progressive ventricular dysfunction or Fontan circulatory failure.<sup>11</sup> Consultation with an

electrophysiologist with expertise in the Fontan population is recommended to inform decision-making regarding choice of cardioversion strategy and the potential need for antiarrhythmic medication. Because of the high thrombosis risk in the Fontan population, transesophageal echocardiography prior to cardioversion is necessary to rule out thrombosis regardless of duration of the arrhythmia or cardioversion strategy.<sup>61,62</sup> Anticoagulation is recommended both immediately after cardioversion and over the long-term.

16. The decision to proceed with heart transplantation in adults with Fontan circulation is complex. Careful assessment of each patient's anatomy and physiological state is necessary to balance the procedural and perioperative risks with potential benefits. Although cardiac transplantation can be performed successfully in adults with Fontan circulation, careful planning by a diverse multidisciplinary team with experience in Fontan transplantation is necessary to address pretransplant optimization, intraoperative planning, and postoperative care. Teams should have representation across specialties, including ACHD, heart failure/transplantation, congenital heart disease surgery, transplant surgery, cardiac anesthesia/critical care, cardiac imaging, hepatology, social work, and psychiatry. Additional subspecialty representation may be required, depending on the unique needs of the patient. The role for combined heart-liver transplantation in adults with Fontan circulation remains uncertain. Some studies have suggested improved outcomes in patients with evidence of liver cirrhosis and clinical evidence of portal hypertension, including ascites, varices, and splenomegaly,<sup>1,63,64</sup> but prospective studies and long-term data are lacking. Those studies are limited by a small number of adults with Fontan circulation undergoing recent heart-only transplantation who have similar degrees of FALD, compared with combined heart-liver transplantation recipients, and by a paucity of studies on the trajectory of FALD after heart-only transplantation in adults. Published experiences of patients undergoing combined heart-liver transplant in adults with Fontan circulation show similar survival rates as in as heart-only transplantation recipients but high rates of postoperative complications and lengthy posttransplant hospitalizations.<sup>65</sup> Patients with decompensated FALD—manifesting as cirrhosis on pathology with clinical evidence of portal hypertension including variceal disease, ascites, and splenomegaly—benefit from evaluation by transplant hepatology at the time of referral for heart transplantation. The complex decision to proceed with combined heart-liver

transplantation should be made for each patient by a multidisciplinary team with expertise in performing combined heart-liver transplantation in adults with Fontan circulation and who have extensive knowledge of locally available expertise.

17. In adults with Fontan circulation and high-grade atrioventricular block, epicardial apical site pacing may be associated with greater ventricular synchrony and a lower rate of ventricular dysfunction.<sup>12,13,66</sup> Determination of the appropriate pacing strategy in adults with Fontan circulation and atrioventricular block should be made by an electrophysiologist with experience in device therapy.
18. Exercise training in adults with Fontan circulation has low risk<sup>67</sup> and has shown benefits that include improvements in peak VO<sub>2</sub> and quality of life<sup>14,15,68</sup> across different exercise modalities.<sup>69</sup> Because many adults with Fontan circulation may be prone to a sedentary lifestyle and have a predisposition to reduced skeletal muscle mass and increased adiposity from perceived limitations and prior instructions to minimize physical activity, clinician-directed, supervised exercise programs may offer particular benefit.<sup>69</sup> Resistance training, particularly of the lower extremities, may offer advantages in this population by facilitating increases in muscle mass and venous return.<sup>68</sup>
19. Catheter ablation can substantially reduce atrial arrhythmia burden in adults with Fontan circulation.<sup>16,17</sup> Scar-mediated intra-atrial reentrant tachycardia and focal atrial tachycardias predominate, and treatment frequently requires integration of multiple interventions, including anticoagulation, cardioversion, antiarrhythmic medical therapy, pacing, and catheter ablation.<sup>7,36,70</sup> Management should be performed in consultation with ACHD providers and electrophysiologists with experience in managing adults with Fontan circulation. Because catheter ablation of atrial arrhythmias in this population is associated with significant challenges, including multiple arrhythmia circuits, difficult access, atrial scarring, and a high risk for conduction system injury,<sup>71</sup> it should be performed only by electrophysiologists with expertise in ablation of patients with Fontan circulation.
20. Stenosis of the Fontan pathway can manifest in extracardiac conduits and lateral tunnel Fontans as a consequence of changes in the shape of the conduit over time, inadequate baffle patches, neointimal proliferation, and/or thrombosis. Fontan pathway stenosis can increase Fontan pressure and result in exaggerated venous hypertension. No studies to date have been powered to detect differences in long-term clinical outcomes; however, many have shown that

stenting can be performed safely and may improve functional status and hemodynamics.<sup>72-75</sup> Although there is debate regarding what constitutes a hemodynamically significant degree of Fontan obstruction, an internal reduction of 25% in size or a pressure gradient of at least 1 mm Hg at pullback has been utilized.<sup>73</sup> Because the degree of anesthesia can affect pressure gradients at the time of catheterization, thereby not reflecting the hemodynamics at peak activity, the decision to stent Fontan pathways or PAs must be made by providers who have significant experience with cardiac catheterizations in adults with Fontan circulation.

21. Aortopulmonary collaterals are common in patients with single-ventricle physiology. Because aortopulmonary collaterals can increase ventricular loading and PA pressure, while decreasing systemic cardiac output, closure may be associated with improvement in systemic blood flow, particularly in patients with progressive ventricular enlargement or elevated end-diastolic pressure.<sup>76</sup> Closure before transplantation may also be beneficial to reduce the potential for intraoperative bleeding.<sup>77,78</sup> Decisions about closure of aortopulmonary collaterals should be made in consultation with a congenital interventional cardiologist who has experience with adults with Fontan circulation.
22. Use of pulmonary vasodilators to reduce PVR and increase ventricular preload can improve exercise performance in select adults with Fontan circulation without evidence of elevated ventricular end-diastolic pressure. Mixed data exist regarding which parameters are affected and the degree of benefit, and the evidence focuses largely on pediatric populations. Measures of exercise performance at the anaerobic threshold have shown the most consistent improvement<sup>79,80</sup>; however, a few smaller studies have also demonstrated improvement in additional exercise-based metrics.<sup>19,81-83</sup> The impact of pulmonary vasodilators on non-exercise-related Fontan parameters, including progression of FALD, remains unclear.
23. Conversion to a total cavopulmonary Fontan from an atriopulmonary Fontan may be reasonable in patients with symptomatic recurrent atrial arrhythmias that are refractory to both medical and catheter-based interventions.<sup>20</sup> A simultaneous, modified right- or

left-sided Maze procedure at the time of Fontan conversion may also offer benefit depending on the type of atrial arrhythmia.<sup>84</sup> Because the mortality risk with Fontan conversion can be significant,<sup>85,86</sup> particularly in patients with risk factors,<sup>21,86,87</sup> appropriate patient selection is important. The impact on progression of other Fontan-associated complications, including FALD, remains unclear. The decision to proceed with Fontan conversion surgery should be made while accounting for the potential effects on future advanced cardiac therapeutic options, including transplantation.

24. The role for additional, nontransplant cardiac surgical procedures in adults with Fontan circulation and evidence of Fontan circulatory failure remains controversial and may be considered after multidisciplinary discussion and careful review of the risk-benefit ratio when compared with alternative treatment options, including advanced cardiac therapies. Atrioventricular valve dysfunction in adults with Fontan circulation is relatively common, particularly in those with a common atrioventricular valve or a morphologic tricuspid valve.<sup>88</sup> Although moderate or greater atrioventricular valve regurgitation is associated with increased mortality, whether atrioventricular valve repair or replacement improves outcomes remains a matter of debate.<sup>89,90</sup> Risk factors for poor outcomes after atrioventricular valve surgery—including a morphologic tricuspid valve, a history of protein-losing enteropathy, and ventricular dysfunction—should be considered when identifying candidates for operative valvular intervention.<sup>91</sup>

#### 4.4.5.1. HLHS/Norwood Repair

**Recommendation for HLHS/Norwood Repair**  
Referenced studies that support recommendation are summarized in the [Evidence Table](#).

COR	LOE	RECOMMENDATION
<b>Diagnostic</b>		
2a	C-EO	1. In patients with HLHS, routine 3-dimensional imaging of the neoaorta to assess for dilation and obstruction is reasonable.

**Synopsis**

Patients with HLHS have unique risks within the adult Fontan population. HLHS is defined by underdevelopment of the left ventricle and by hypoplasia of the aortic valve and ascending aorta. Like other forms of single-ventricle congenital heart disease, individuals with HLHS undergo staged surgical palliation, typically to Fontan physiology. The first procedure, stage 1 or Norwood repair, in HLHS palliation consists of transection and ligation of the distal main PA, anastomosis of the hypoplastic aorta to the pulmonary stump, and either a Blalock-Taussig-Thomas or an RV-to-PA shunt. Additional concerns include, but are not limited to, sequelae of the Norwood procedure, the presence of a morphologic right ventricle as the systemic ventricle, and a single systemic tricuspid atrioventricular valve. Neoaortic dilation and obstruction of the Norwood anastomosis can occur. Because the native coronary arteries arise from the hypoplastic aortic root, coronary ischemia may also be more prevalent in patients with HLHS.

In addition to concerns regarding the neo-aorta, some data suggest that patients with HLHS are at increased risk for early Fontan failure,<sup>1</sup> ventricular and atrioventricular valve dysfunction,<sup>2</sup> and neurocognitive dysfunction.<sup>3</sup> Thus, although the standard surveillance protocol for adult Fontan populations may be applied to the HLHS population, additional or more frequent evaluations may be warranted in certain patients with HLHS.

**Recommendation-Specific Supportive Text**

1. Periodic imaging of the neo-aorta with MR angiography or CT angiography is reasonable in adults with HLHS to evaluate for obstruction or progressive neo-aortic dilation. Echocardiography is generally insufficient to adequately image the distal ascending aorta. The risk associated with neo-aortic dilation in patients with HLHS has yet to be established; however, significant neo-aortic-root pathology can increase operative complexity at the time of cardiac transplantation. The need for follow-up imaging, and the timing between imaging studies, should be determined on an individual basis based on the size of the neo-aorta, the rate of change across prior imaging studies, and the probability that the patient may need to be considered for advanced cardiac therapies in the near future.

**4.4.6. Eisenmenger Syndrome**

**Recommendations for Eisenmenger Syndrome**  
 Referenced studies that support recommendations are summarized in the Evidence Table.

COR	LOE	RECOMMENDATIONS
<b>Diagnostic</b>		
1	B-NR	1. In adults with suspected Eisenmenger syndrome, invasive hemodynamic assessment should be performed to confirm the diagnosis and to exclude concomitant disease that contributes to right-to-left shunting or PAH. <sup>1-3</sup>
1	B-NR	2. Adults with Eisenmenger syndrome should be managed by specialists with expertise in both congenital cardiology and PAH to improve outcomes. <sup>4,5</sup>
3: Harm	B-NR	3. Adults with Eisenmenger syndrome should be advised against pregnancy to decrease the risk associated with excess maternal morbidity and mortality. <sup>6-8</sup>
<b>Therapeutic</b>		
1	B-R	4. In adults with Eisenmenger syndrome and an LV ejection fraction >40% who are symptomatic or have reduced exercise capacity, initial monotherapy with PAH-directed therapy* is recommended to improve symptoms, hemodynamics, <sup>9-12</sup> and overall survival. <sup>13</sup>
1	B-NR	5. In adults with Eisenmenger syndrome and an LV ejection fraction >40% who remain symptomatic or have worsening exercise capacity on a single PAH therapy, dual combination therapy with an endothelin receptor antagonist and a phosphodiesterase-5 inhibitor is recommended to improve symptoms, hemodynamics, and overall survival. <sup>13-15</sup>

*Continued on the next page*

Continued		
COR	LOE	RECOMMENDATIONS
1	C-LD	6. In adults with Eisenmenger syndrome who present with atrial arrhythmias, prompt restoration and maintenance of sinus rhythm is recommended to avoid hemodynamic deterioration. <sup>11,16-18</sup>
2a	C-LD	7. In adults with Eisenmenger syndrome, a regular exercise program in combination with directed PAH therapy can be effective in improving exercise capacity. <sup>19,20</sup>
2b	C-LD	8. In adults with Eisenmenger syndrome and LV ejection fraction >40% who are deemed to be at high risk for adverse outcomes† or who have rapidly progressive disease, inhaled or subcutaneous prostacyclin therapy may be considered as initial therapy or as an addition to other PAH therapy to improve symptoms, exercise capacity, and hemodynamics. <sup>21,22</sup>
2b	C-EO	9. In adults with Eisenmenger syndrome, anticoagulation therapy may be considered for patients with high-risk features (atrial arrhythmia, new or enlarging pulmonary arterial thrombosis, or prior thromboembolic event) and low bleeding risk to prevent thromboembolic complications.
3: No Benefit	B-NR	10. Adults with Eisenmenger syndrome should not be routinely prescribed oral anticoagulation given the high bleeding risk and lack of long-term survival benefit. <sup>23-25</sup>
3: Harm	B-NR	11. In adults with Eisenmenger syndrome, closure of any intracardiac or vascular shunt should not be performed given the increased perioperative risks and risks for short- and long-term morbidity and mortality. <sup>26-28</sup>

continued in the next column

Continued		
COR	LOE	RECOMMENDATIONS
3: Harm	B-NR	12. In adults with Eisenmenger syndrome and intracardiac shunts who meet indications for permanent pacing or an ICD, endocardial leads may be potentially harmful given the increased risk for systemic thromboembolism. <sup>29,30</sup>

Recommendations on managing chronic cyanosis—including, but not limited to, management of iron supplementation, hyperviscosity, and risk and management of central nervous system infections—generally apply to patients with Eisenmenger syndrome and are provided in Section 3.5, “Management of Cyanosis.”

\*See Table 43 for evidence and recommendations on specific PAH therapies.

†Patients at high risk include patients with World Health Organization functional class 3 or 4, a 6-minute walk distance <165 m, tricuspid annular plane systolic excursion <16 mm, and NT-proBNP level >1,400 pg/mL.<sup>31</sup>

### Synopsis

Eisenmenger syndrome results from intra- and/or extracardiac left-to-right shunt defects, causing high PVR and subsequent bidirectional shunting. The risk for developing the syndrome is influenced by concomitant congenital syndromes, congenital cardiac anatomy, shunt size, genetic factors, and environmental exposure.

Chronic cyanosis, abnormal loading conditions, and abnormalities of the systemic and pulmonary perfusion all contribute to the potential for multiorgan system dysfunction, diastolic and systolic cardiac dysfunction, arrhythmias, and SCD. Across the ACHD population, patients with Eisenmenger syndrome have among the lowest exercise tolerance and quality of life.<sup>32,33</sup>

Patients with Down syndrome and Eisenmenger syndrome have more comorbidities, such as obstructive sleep apnea and thyroid dysfunction, that may adversely affect disease severity and trajectory. Commonly used risk-assessment tools, such as 6-minute walk distance, are consistently shown to have lower accuracy in reflecting the disease severity in patients with Down syndrome.<sup>31</sup>

Supplemental oxygen should be considered on an individual basis, avoiding high volumes aimed to “normalize” saturations. Prolonged high-altitude stay, pregnancy, exposure to extremely hot or humid environments, nephrotoxin exposure, extreme exertion, and large shifts in intravascular volume should be avoided.

**TABLE 43 First-Line PAH-Directed Therapy in Patients With Eisenmenger Syndrome**

Medication Class	Clinical Trial Evidence	2022 ESC/ERS Guidelines for the Diagnosis and Treatment of Pulmonary Hypertension <sup>37</sup>	2025 ACC/AHA Guidelines for the Management of Adults with Congenital Heart Disease
Endothelin receptor antagonists	Two moderate-size randomized controlled trials of bosentan (BREATHE 5 trial, 54 patients) <sup>9</sup> and macitentan (MAESTRO trial, 226 patients) <sup>10</sup> evaluated the effects of endothelin receptor antagonists in Eisenmenger syndrome. BREATHE 5 showed improvement in hemodynamics and functional class after 16 weeks of treatment. The MAESTRO trial design was different and included a more heterogeneous patient population, including wider age range, wider spectrum of functional classes, patients on background therapy with PDES inhibitors, and patients with Down syndrome. The primary endpoint, which consisted of 6MWD, was neutral. Secondary endpoints of functional class and NT-proBNP levels favored macitentan therapy. In a subgroup of patients aged ≥18 years who had a follow-up invasive hemodynamic assessment and did not have Down syndrome, those in the macitentan group had hemodynamic improvement, which was also associated with an improvement in 6MWD.	Bosentan is a class 1 recommendation; other endothelin receptor antagonists “should be considered” in patients with Eisenmenger syndrome (class 2a recommendations).	All endothelin receptor antagonists are recommended as initial treatment in patients with Eisenmenger syndrome (class 1 recommendation).
Phosphodiesterase-5 inhibitors	A small randomized controlled trial (28 patients) <sup>11</sup> and a retrospective observational study <sup>12</sup> showed improvements in 6MWD, functional status, and hemodynamics without a significant reduction in SVR.	Phosphodiesterase-5 inhibitors “should be considered” in patients with Eisenmenger syndrome (class 2a recommendation).	All phosphodiesterase-5 inhibitors are recommended as initial treatment in patients with Eisenmenger syndrome (class 1 recommendation).
Soluble guanylate cyclase stimulator (riociguat)	Data on Eisenmenger syndrome are currently lacking. A subgroup analysis of the trials that had shown benefit in PAH (PATENT 1+2) demonstrated that in patients with persistent or recurrent PAH after congenital heart defect correction, riociguat use was associated with sustained improvement in 6MWD, PVR, NT-proBNP level, and WHO functional class at 2 years. <sup>55</sup>	Riociguat “should be considered” in patients with Eisenmenger syndrome (class 2a recommendation).	No specific recommendation due to lack of data.
Prostacyclin analogs and receptor agonists	Data on the effects of inhaled iloprost are conflicting, with 1 small randomized controlled trial (16 patients) showing no effect on 6MWD, BNP levels, or quality of life, <sup>45</sup> whereas 1 small single-arm study (11 patients) showed an increase in 6MWD, subjective quality of life, and RV function. <sup>21</sup> There are no data on subcutaneous/intravenous prostacyclin or oral prostacyclin receptor agonist therapy (selexipag) as a stand-alone initial treatment.	Initial prostacyclin therapy “should be considered” in patients with Eisenmenger syndrome (class 2a recommendation).	Initial inhaled prostacyclin therapy may be considered in patients with Eisenmenger syndrome (class 2b recommendation).
Activin signaling inhibitors	No data are currently available on the activin signaling inhibitor sotatercept in patients with Eisenmenger syndrome.	No recommendation	No recommendation

6MWD indicates 6-minute walk distance; ACC, American College of Cardiology; AHA, American Heart Association; BNP, B-type natriuretic peptide; BREATHE-5, Bosentan Randomized Trial of Endothelin Antagonist Therapy-5; ERS, European Respiratory Society; ESC, European Society of Cardiology; MAESTRO, Macitentan in Eisenmenger Syndrome to Restore Exercise Capacity; NT-proBNP, N-terminal prohormone of B-type natriuretic peptide; PAH, pulmonary arterial hypertension; PATENT 1+2, Pulmonary Arterial hyperTENSION sGC-stimulator Trial; PVR, pulmonary vascular resistance; SVR, systemic vascular resistance; and WHO, World Health Organization.

High-altitude simulation testing can be used for risk stratification before air travel. Therapy for PAH in symptomatic patients or in those with significantly reduced exercise capacity improves symptoms and hemodynamics,<sup>9-15,21,22,34</sup> with retrospective data suggesting improvement in overall survival.<sup>35</sup>

The evidence base on mechanical circulatory and pulmonary support, lung transplantation with repair of

underlying cardiovascular defects, or heart-lung transplantation has been extended to patients with Eisenmenger syndrome. Although optimal timing and eligibility remain controversial, high-risk patients who remain symptomatic despite optimal medical management should be considered for transplantation.<sup>36</sup> Palliative care and advance care planning are important, especially given that survival in an intensive care setting

**TABLE 44 Eisenmenger Syndrome: Routine Follow-Up and Testing Intervals**

Type of Follow-Up or Testing	Physiological Stage A* (mo)	Physiological Stage B* (mo)	Physiological Stage C* (mo)	Physiological Stage D* (mo)
Outpatient ACHD cardiologist	N/A	N/A	6-12	3-6
Electrocardiogram	N/A	N/A	6-12	6-12
Transthoracic echocardiogram	N/A	N/A	12	6-12

\*See Section 2.2 for details on the ACHD anatomic and physiological classification system. ACHD indicates adult congenital heart disease; and N/A, not applicable.

is poor. See Table 44 for suggested routine testing and follow-up intervals for patients with Eisenmenger syndrome.

**Recommendation-Specific Supportive Text**

1. Bidirectional shunting through large septal defects or large communications between the great arteries associated with severely elevated PVR may be diagnosed as Eisenmenger syndrome. Accurate diagnosis of PAH, along with a detailed shunt run, should be obtained in all patients with Eisenmenger syndrome. Potential contributors to bidirectional shunting—such as postcapillary pulmonary hypertension, blood streaming related to a valvular regurgitant lesion, and RV pressure overload related to outflow tract obstruction—should be excluded by careful clinical examination, imaging studies, and further information from cardiac catheterization.<sup>1-3,37</sup> After an Eisenmenger diagnosis has been established, routine follow-up invasive hemodynamics are typically not needed, but they can be contemplated in cases of clinical worsening or as part of planning for MCS or transplantation.
2. Despite the distinctive hemodynamic and pathophysiological features of Eisenmenger syndrome, it has similarities with other forms of PAH in terms of risk stratification, treatment strategies, and follow-up. Management therefore optimally involves PAH subspecialists. Risk stratification using BNP or NT-proBNP, 6-minute walk distance, and functional class assessment—similar to the 4-strata risk models proposed for other patients with PAH<sup>37</sup>—can be helpful in patients with Eisenmenger syndrome after the proposed cutoffs are adjusted (although less helpful in patients with Down syndrome).<sup>31,36,38,39</sup> Prognostic factors specific to Eisenmenger syndrome are the presence of Down syndrome and pretricuspid shunt, older patient age, worse hypoxemia, reduced glomerular filtration rate, and echocardiographic indices of RV dysfunction.<sup>36</sup> Although treatment with PAH therapies is recommended, special considerations—such as maintaining a fine balance between

the systemic and the PVR, to avoid worsening hypoxia; and avoidance of volume overload in patients with functional univentricular hearts—are unique to patients with Eisenmenger syndrome.

3. Hemodynamic changes associated with pregnancy may lead to increased right-to-left shunting, worsening RV dysfunction and hypoxemia, small-for-gestational-age births, spontaneous miscarriages (especially in the first trimester), PAH crises in the early postpartum era, and increased risks for thromboembolic events and paradoxical embolism. Thus, pregnancy carries very high risk in women with Eisenmenger syndrome, classified in the highest-risk group (World Health Organization class 4) for maternal and fetal morbidity and mortality. Maternal mortality risk in patients with Eisenmenger syndrome is reported at 30% to 50%, with heart failure exacerbation rates of up to 50% and a rate of perinatal fetal loss or morbidity of about 30%.<sup>6,7,40</sup> Patients who choose to proceed with pregnancy should be closely followed during the entire pregnancy by a multidisciplinary cardio-obstetrics team of experts in maternal-fetal medicine, ACHD, pulmonary hypertension, and obstetric anesthesia.
4. Details on the clinical trials evaluating PAH-directed therapy in Eisenmenger syndrome patients are outlined in Table 43. Given that endothelin receptor antagonist therapy has been shown to improve 6-minute walk distance, biomarker levels, and overall hemodynamics, this therapy is recommended in symptomatic patients or those with low 6-minute walk distance. Although the MAESTRO trial<sup>10</sup> showed no significant change in 6-minute walk distance with macitentan, a benefit of that therapy was found in the subgroup of patients without Down syndrome and in patients who had a follow-up invasive hemodynamic assessment. Anecdotal data also suggest that dual endothelin 1 receptor inhibition, as offered by macitentan but not bosentan, is associated with improved platelet function<sup>41</sup> and that macitentan's pharmacokinetic and pharmacodynamic profiles are excellent.<sup>42</sup> One side effect that is associated with macitentan use is new anemia, which may not be advantageous in patients with Eisenmenger syndrome. Data on initial treatment with phosphodiesterase-5 inhibitors is less robust than for endothelin receptor antagonists but did not raise safety concerns pertaining to a significant reduction in systemic vascular resistance or oxygen saturations. Phosphodiesterase-5 inhibitor therapy is associated with improved 6-minute walk distance, symptoms, and hemodynamics<sup>11,12</sup> and, thus, is recommended as another option for initial treatment of adults with Eisenmenger syndrome.

5. Data are scarce on the safety and efficacy of upfront combination PAH therapy, compared with monotherapy in adults with Eisenmenger syndrome. One study showed mixed results when combined upfront sildenafil and ambrisentan therapy was compared with sildenafil alone,<sup>15</sup> with better 6-minute walk distance in the sildenafil-only group but better New York Heart Association functional class and lower pulmonary pressures in the combination group. Addition of a second PAH therapy, evaluated in a nonrandomized fashion for patients who continued to experience clinical deterioration, was associated with improvement in functional class, 6-minute walk distance, oxygen saturation, NT-proBNP levels, and PVR—with only a slight reduction in systemic vascular resistance and an increase in the Qp:Qs.<sup>14</sup> There are data to support triple vasodilator therapy with the addition of subcutaneous treprostinil, although data on inhaled iloprost and the oral prostacyclin analog selexipag are less conclusive.<sup>21,22,43</sup> Intravenous prostacyclin treatment is typically avoided to minimize the risk for paradoxical embolization from the indwelling catheter, although data are limited.
6. Arrhythmias are a major cause of morbidity and mortality in adults with Eisenmenger syndrome.<sup>11,16-18,44</sup> Reasons include disruption of the delicately balanced hemodynamic and shunt status, with rapid deterioration of the subpulmonic ventricular function and high risk for systemic embolization. Prompt cardioversion with the assistance of expert cardiac anesthesia is, thus, recommended for patients with atrial arrhythmias, even in the presence of hemodynamic stability at the time of presentation.
7. Supervised or carefully prescribed mild-to-moderate-intensity exercise appears to be safe in adults with Eisenmenger syndrome. One retrospective study that included 20 patients with PAH, of whom 10 had Eisenmenger syndrome, showed that 3 weeks of an in-hospital-based training program, followed by 15 weeks of home training, were associated with greater 6-minute walk distance, higher peak oxygen consumption, maximal workload, and quality of life—but no change in World Health Organization functional class.<sup>19</sup> In a subgroup analysis of adults with congenital heart disease and PAH, those with Eisenmenger syndrome randomized to a home-based exercise training program showed improved 6-minute walk distance compared with patients who did not receive this training.<sup>20</sup> Patients with Eisenmenger syndrome should generally avoid very strenuous activity, competitive sports, and extreme isometric exercise.
8. See [Table 43](#) for details on clinical trials of PAH-directed medications, including prostacyclin therapy, in patients with Eisenmenger syndrome. Single therapy with inhaled prostacyclin has been studied in a small prospective trial of adult symptomatic patients with normal LV function. Patients in the treatment group had greater improvements in hemodynamics, RV function, oxygen saturations, symptoms, and functional class.<sup>21</sup> Data on combination therapy with inhaled or subcutaneous prostacyclin are scarce, and results conflict: In 1 retrospective study that mainly used subcutaneous treprostinil (thus avoiding the risks for embolic events and sepsis with intravenous therapy) for treatment escalation, clinical benefits in functional class, 6-minute walk distance, and hemodynamics were shown<sup>22</sup>; another study that used inhaled iloprost showed no benefit.<sup>45</sup> Thus, prostacyclin therapy may be considered in patients with Eisenmenger syndrome, especially when oral therapies show lack of efficacy or are not well tolerated, or when treatment is being escalated. Data on the safety and efficacy of the oral prostacyclin analog selexipag are scarce, with 1 retrospective study showing no clinical benefit in patients with Eisenmenger syndrome.<sup>43</sup> There are currently no data on riociguat use in Eisenmenger syndrome patients.
9. Thrombosis is common in patients with Eisenmenger syndrome and may occur in the setting of grossly dilated PAs, dilated and/or dysfunctional cardiac chambers, atrial arrhythmia, and in relation to intracardiac prosthetic or foreign material (eg, pacemaker leads). One observational study reported a very high prevalence (up to 30%) of laminated (in situ) thrombi in aneurysmal, partially calcified PAs of adults with Eisenmenger syndrome.<sup>46</sup> Cerebrovascular events are also not uncommon, estimated to affect 8% to 14% of the population,<sup>47,48</sup> with many more silent cases (47% on routine cerebral MR imaging).<sup>49</sup> Although prospective or retrospective data on the timing, type, and efficacy of systemic anticoagulation are lacking, it is well recognized that systemic arterial and venous thromboembolic events can have a devastating effect on patients with Eisenmenger syndrome.<sup>50</sup> Systemic anticoagulation treatment may, thus, be reasonable in patients with prior thromboembolic episodes or those with evidence of pulmonary arterial thrombosis who have not previously experienced a major bleeding event, defined as bleeding that led to a drop in hemoglobin of  $\geq 2$  g/dL or to transfusion of  $>2$  red blood cell units.<sup>51</sup> For patients with atrial fibrillation or any type of atrial flutter, risk stratification for systemic embolism, using accepted methods such as the

CHA<sub>2</sub>DS<sub>2</sub>-VASc score, is not applicable. Anticoagulation should be considered on an individual basis, also considering the patient's HAS-BLED score (score >2 reflects a high risk for bleeding).<sup>52</sup> There are no direct comparative data on the risks and benefits of vitamin K antagonists versus low-molecular-weight heparin versus direct oral anticoagulants in Eisenmenger syndrome, nor are there comparative data among the different types of direct oral anticoagulants.

10. Patients with Eisenmenger syndrome have high bleeding risk related to alterations in the coagulation system that include low factor II, V, VII, IX, X, and von Willebrand levels, along with increased fibrinolytic activity and platelet number/function abnormalities.<sup>25</sup> Although spontaneous bleeding events are usually minor and self-limiting, recurrent hemoptysis is common and is attributable to intrapulmonary hemorrhage related to erosion of a dilated bronchial artery, often at the time of a low respiratory chest infection. Hemoptysis is often self-limiting, but it can cause major bleeding and become life-threatening. In evaluating the effects of antithrombotic and antiplatelet treatment in Eisenmenger syndrome, the German National Congenital Heart Disease Registry showed that 17.6% of patients with Eisenmenger syndrome were treated with oral anticoagulants, whereas 23.5% received aspirin, with neither showing a beneficial effect on survival.<sup>24</sup> Thus, in the absence of an additional indication for anticoagulation treatment, routine anticoagulation for preventive purposes is not recommended.
11. Once significant pulmonary vascular disease develops and the shunt becomes bidirectional, defect closure should be avoided because the defect serves as a "pop-off" mechanism that assists the RV in coping with the elevated afterload. Transcatheter or surgical closure of those defects carries significant periprocedural risks, and it is likely to exacerbate RV strain and increase morbidity and mortality.
12. In the presence of intracardiac shunts and bidirectional flow, transvenous leads of a permanent pacemaker or ICD incur an increased risk for systemic thromboembolism. Alternative approaches such as epicardial lead placement or a subcutaneous ICD should be considered on an individual basis. Given the low pressurized flow in the pulmonic atrium, compared with the ventricular flow, the concern for thrombus formation is higher for atrial leads. Some case reports of Eisenmenger syndrome describe successful ventricular leadless pacemaker implantation with short-term anticoagulation until endothelialization occurs, which may be considered in select cases and highly specialized centers.<sup>29,30,53,54</sup>

## 4.5. Coronary Artery Anomalies

### 4.5.1. Anomalous Aortic Origin of a Coronary Artery

**Recommendations for Anomalous Aortic Origin of a Coronary Artery**  
Referenced studies that support recommendations are summarized in the [Evidence Table](#).

COR	LOE	RECOMMENDATIONS
<b>Diagnostic</b>		
1	B-NR	1. In adults with suspected anomalous origin of a coronary artery (AAOCA), coronary CT angiography or MR angiography (if CT angiography is contraindicated) is recommended to confirm the anatomic diagnosis and guide management. <sup>1-3</sup>
1	B-NR	2. In adults with an AAOCA from the opposite sinus, risk stratification with evaluation for physiological and/or ischemic changes should be performed to guide management. <sup>4,5</sup>
<b>Therapeutic</b>		
1	B-NR	3. In adults with symptomatic AAOCA or diagnostic evidence consistent with myocardial ischemia attributable to the anomalous artery, surgery is recommended. <sup>6</sup>
2a	C-EO	4. In adults with asymptomatic anomalous origin of the left coronary artery, surgery is reasonable in the presence of high-risk anatomy.*
2b	B-NR	5. In asymptomatic adults with an AAOCA from the opposite sinus and without evidence of ischemia or evidence of compromised coronary perfusion, the benefit of surgery is not well established, and continued observation or surgery may be reasonable. <sup>6-8</sup>

\*High-risk findings such as ostial or proximal stenosis, slit-like orifice, acute angle of takeoff, or intramural course.

### Synopsis

Coronary abnormalities are common congenital cardiovascular anomalies that include AAOCA in up to 1% of the population<sup>9</sup> and coronary fistula. Many AAOCA abnormalities have a benign outcome (in contrast with the poor outcomes of untreated patients who have an anomalous coronary artery, especially an anomalous left coronary artery, from the PA).

Assessment of the risks for ischemia and SCD in patients with AAOCA is difficult because available data do

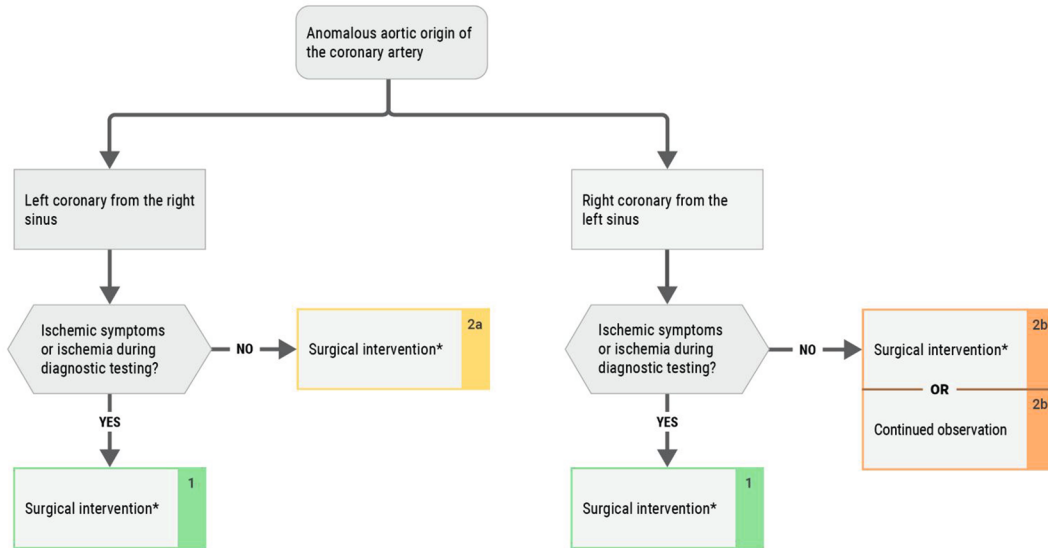
**FIGURE 7** Anomalous Aortic Origin of the Coronary Artery


## Anomalous Aortic Origin of the Coronary Artery

**LEGEND**

- COR 1
- COR 2a
- COR 2b
- COR 3-No Benefit
- COR 3-Harm

(Class of Recommendation)



 2025 Adults With Congenital Heart Disease  
 © 2025 by the American College of Cardiology Foundation and the American Heart Association, Inc.

\*Surgical approaches include coronary unroofing with or without osteoplasty, coronary reimplantation, and pulmonary translocation. Coronary artery bypass graft is reserved for patients with coexisting coronary artery disease. Modified with permission from Stout et al.<sup>22</sup> Copyright 2018 American Heart Association, Inc. and American College of Cardiology Foundation.

not adequately capture the complete clinical spectrum of those anomalies. Data from autopsy series have described anomalies in patients who experienced SCD, specifically those with an anomalous left coronary artery from the right sinus or an anomalous right coronary artery from the left sinus (interarterial course was the most common finding).<sup>10</sup>

The decisions to perform surgery, or if exercise restriction and medical therapy may be beneficial, are based on synthesizing limited data regarding patients with AAOCA (Figure 7). Risk stratification and shared decision-making are paramount in patients with AAOCA. Patients with AAOCA need ongoing cardiac follow-up. The need for serial imaging and stress testing is determined by clinical status (see Table 45).

### Recommendation-Specific Supportive Text

1. Coronary CT angiography, CMR angiography, and catheterization can delineate the proximal course of the coronary artery and its relationship to other structures. CT angiography is generally preferred<sup>11-13</sup> because of its superior spatial resolution, although CMR angiography may also adequately delineate the relationship of the coronary artery to the aorta, PA, and other structures, including whether the proximal course appears to be intramural. CMR also has the advantage of visualizing fibrosis. Invasive coronary angiography can be helpful when there is concern about coronary artery stenosis or when concomitant hemodynamic evaluation for shunt assessment or intravascular ultrasound/flow evaluation is needed. In

**TABLE 45** Anomalous Aortic Origin of a Coronary Artery: Routine Follow-Up and Testing Intervals

Type of Follow-Up or Testing	Physiological Stage A* (mo)	Physiological Stage B* (mo)	Physiological Stage C* (mo)	Physiological Stage D* (mo)
Outpatient ACHD cardiologist	24-36	12	12	12
Electrocardiogram	24-36	12	12	12
Transthoracic echocardiogram	24-36	24	12	12

For recommendations on routine CT and MR angiography, see supportive text for recommendations #1 and #2.

\*See Section 2.2 for details on the ACHD anatomic and physiological classification system.

ACHD indicates adult congenital heart disease; CT, computed tomography; and MR, magnetic resonance.

patients with anatomic or physiological high risk, intravascular ultrasound or fractional flow reserve may be diagnostically useful.<sup>11</sup>

- In patients with AAOCA, an anomalous left coronary artery from the right ostium is less common than an anomalous right coronary artery but is more likely to be associated with SCD.<sup>14</sup> When anomalous origin of a coronary artery from the opposite sinus is suspected, anatomic imaging and evaluation for physiological and ischemic changes should be performed to assist in risk stratification and guide management. Assessing the physiological impact, including evaluating the evidence of associated ischemic changes on stress testing, is necessary to identify potential risks and indications for surgery. Preferably, exercise testing or dobutamine stress testing reflects dynamic conditions better than vasodilator stress testing.<sup>15</sup> Therefore, exercise or dobutamine stress testing with echocardiographic, nuclear, or MR imaging is preferred over vasodilator stress testing to assess for ischemia and guide decision-making.<sup>15-17</sup> Dobutamine stress cardiac MR imaging is feasible to assess for inducible hypoperfusion and wall-motion abnormalities in patients with AAOCA.<sup>17</sup> Other risk-stratification options include assessment of reduced fractional flow reserve in patients with high-risk features, including hypoplasia of the proximal segment and longer intramural course.<sup>18</sup>
- In patients with symptoms related to AAOCA, repair of the coronary artery anomaly should alleviate the symptoms. In autopsy and surgical series, cardiac symptoms are more common in patients with a left coronary artery arising from the right coronary cusp. In autopsy studies of patients who died because of an anomalous coronary artery, fibrosis is a common finding, suggesting that ischemia preceded the terminal event.<sup>19</sup> However, some patients have had an SCD event despite a normal stress electrocardiogram; therefore, the absence of ischemia is not completely reassuring. In autopsy series, many patients whose death was attributed to anomalous coronary arteries

were young<sup>20</sup>; therefore, management should account for patient age in assessing SCD risk. Surgical approaches include coronary unroofing with or without osteoplasty, coronary reimplantation, and pulmonary translocation. Coronary artery bypass graft is reserved for patients with coexisting coronary artery disease.

- An anomalous left coronary artery from the right sinus is more commonly found in autopsy series of athletes and military recruits who had experienced a non-trauma-related death, suggesting a higher risk for SCD in this population, particularly at extremes of exertion, and in people younger than 35 years. Surgery is reasonable<sup>15</sup> in asymptomatic patients, who have high-risk findings such as ostial stenosis, slit-like orifice, acute angle of takeoff, or intramural course. In patients with ventricular arrhythmias presumed to be related to ischemia caused by anomalous origin of a coronary artery, repair is an option to alleviate the ischemia and presumably mitigate the recurrence of ventricular arrhythmias.
- Presentation bias makes it difficult to quantify the risk for SCD with AAOCA. In asymptomatic patients without evidence of compromised blood flow, no data specifically demonstrate that surgical interventions alter the risk for SCD<sup>13</sup> or long-term survival.<sup>21</sup> Thus, watchful waiting with shared decision-making may also be appropriate. In asymptomatic middle-aged patients without high-risk features, surgery has no documented benefit.

#### 4.5.2. Anomalous Coronary Artery Arising From the Pulmonary Artery

**Recommendations for Anomalous Coronary Artery Arising From the Pulmonary Artery**  
Referenced studies that support recommendations are summarized in the Evidence Table.

COR	LOE	RECOMMENDATIONS
1	B-NR	1. In adults with an anomalous left coronary artery arising from the PA, surgery is recommended to improve cardiac function and reduce the risk for myocardial ischemia. <sup>1</sup>
1	B-NR	2. In symptomatic adults with an anomalous right coronary artery arising from the PA and with evidence of ischemia, surgery is recommended to reduce ischemia, to reduce the risk for SCD, and to improve cardiac function. <sup>2</sup>

Continued on the next page

**Continued**

COR	LOE	RECOMMENDATIONS
2b	B-NR	3. In asymptomatic adults with an anomalous right coronary artery arising from the PA and without evidence of cardiac dysfunction or ischemia, surgery may be considered to avoid the development of cardiac dysfunction. <sup>2</sup>

**Synopsis**

An anomalous left coronary artery from the PA usually is identified during infancy; rarely, it is diagnosed in adulthood incidentally or when a patient presents with evidence of ischemia, mitral regurgitation, or heart failure. An anomalous right coronary artery from the PA is more likely to be identified in adulthood; it may manifest with angina and dyspnea or may be an incidental finding.

**Recommendation-Specific Supportive Text**

1. Although an anomalous left coronary artery arising from the PA is usually identified in infancy, it may be identified in adulthood upon an SCD event, if the patient presents with ischemic symptoms or heart failure, or it may be diagnosed incidentally.<sup>3</sup> Surgery can include reimplantation of the left coronary artery directly into the aorta with or without an interposition graft or by a Takeuchi repair.<sup>4</sup> Ligation or closure of the left coronary artery at the level of the PA with coronary artery bypass grafting can also be performed, usually with the left internal mammary artery anastomosed to the left anterior descending artery.
2. Surgery to alleviate ischemia or ventricular dysfunction is reasonable if the anomalous right coronary artery from the PA is thought to be the cause. Surgery can include reimplantation of the right coronary artery directly into the aorta with or without an interposition graft. Ligation or closure of the right coronary artery at the level of the PA with coronary artery bypass grafting can also be performed, usually with the right internal mammary artery anastomosed to the right coronary or posterior descending coronary artery.
3. In asymptomatic patients with an anomalous right coronary artery, the 2 goals of treatment are to reduce the risk for coronary steal associated with anomalous origin of the right coronary artery from the PA and to establish dual coronary circulation. In younger asymptomatic patients, elective surgery is frequently performed. In asymptomatic older patients, surgery

**TABLE 46 Anatomy of Vascular Rings**

**Complete ring**

- Right aortic arch with aberrant left subclavian artery and left ligamentum arteriosum
- Right aortic arch with mirror image branching and left ligamentum arteriosum extending from descending aorta to main pulmonary artery
- Left aortic arch with aberrant right subclavian artery and right ligamentum arteriosum
- Double aortic arch
- Circumflex aorta

**Incomplete ring**

- Left aortic arch with aberrant right subclavian artery
- Right aortic arch with aberrant left subclavian artery and right ligamentum arteriosum

**Other**

- Innominate artery compression syndrome
- Left pulmonary artery sling

Modified with permission from Porcaro et al<sup>3</sup> via a Creative Commons Attribution 4.0 International License (<http://creativecommons.org/licenses/by/4.0/>). Copyright 2023 Springer Nature.

may be considered on the basis of a functional evaluation, assessment of surgical risk, and any pertinent comorbidities. This is a clinical situation that requires ongoing clinical follow-up with shared decision-making.

**4.5.3. Coronary Artery Fistula**

**Synopsis**

Coronary artery fistula is an abnormal communication between a coronary artery and another cardiovascular structure, such as a cardiac chamber, coronary sinus, superior vena cava, or PA. The incidence of coronary artery fistula is 0.002% in the general population and 0.1% to 0.2% of all patients undergoing coronary angiography for clinical indications.<sup>1</sup>

Coronary fistulas may be congenital or acquired. Specific management strategies can include clinical follow-up, surgery, or catheter closure.<sup>2</sup> In a series of 46 surgically treated patients, predominant preoperative symptoms included angina and heart failure.<sup>3</sup> Notably, postoperative myocardial infarction occurred in 11% to 15%,<sup>4</sup> possibly because of thrombosis or low flow in the dilated coronary artery proximal to fistula closure. Late survival was also significantly reduced, compared with an age-matched population. The presence of coronary artery fistula requires review by a knowledgeable team that may include congenital or noncongenital cardiologists and surgeons, to determine the role of medical therapy and/or percutaneous or surgical closure.

#### 4.6. Vascular Rings and Pulmonary Artery Slings

**Recommendations for Vascular Rings and Pulmonary Artery Slings**  
Referenced studies that support recommendations are summarized in the [Evidence Table](#).

COR	LOE	RECOMMENDATIONS
<b>Diagnostic</b>		
1	B-NR	1. For adults with unexplained symptoms of airway or esophageal compression that raise concern for vascular ring or PA sling, anatomic assessment with cross-sectional imaging of the aortic arch and PAs is recommended. <sup>1</sup>
1	B-NR	2. For adults with persistent symptoms of airway or esophageal compression after repair of vascular ring or PA sling, cross-sectional advanced imaging is recommended to evaluate postoperative anatomy and indications for additional intervention. <sup>1-3</sup>
<b>Therapeutic</b>		
2a	B-NR	3. For adults with symptoms of airway or esophageal compression and a vascular ring or PA sling, surgical repair* is reasonable to improve symptoms. <sup>4-6</sup>
3: No Benefit	B-NR	4. For asymptomatic adults with a vascular ring or PA sling, surgical repair is not indicated. <sup>6-8</sup>

\*A cardiothoracic surgeon with expertise in ACHD should perform the repair.

#### Synopsis

Vascular rings are rare and are typically diagnosed in infancy or early childhood, but they may be first identified in adulthood.<sup>6</sup> Adult presentation is typically after years of unexplained respiratory and/or gastrointestinal symptoms, or the condition may be found incidentally in an asymptomatic adult. Symptoms can include dyspnea, wheezing, stridor, and dysphagia. Asymptomatic patients with a known vascular ring should receive education regarding symptoms necessitating return for evaluation, as up to 11% may eventually develop symptoms and may require intervention to relieve them.

Abnormalities that can cause a vascular ring and potential airway compression are listed in [Table 46](#). One-third to almost half of patients with a vascular ring have an additional congenital heart disease diagnosis, most commonly VSD.

#### Recommendation-Specific Supportive Text

1. In adults with unexplained symptoms that suggest airway or esophageal compression (stridor, wheezing, dyspnea, or dysphagia), vascular ring and PA sling should be considered. Workup may include pulmonary function and barium swallow testing. CMR or CT angiography is recommended to evaluate the aortic arch and PA anatomy and to exclude tracheal and esophageal compression. CT angiography may be preferred to evaluate the relationship of vascular structures to the trachea and tracheal compression.<sup>1-3</sup>
2. Once a vascular ring or PA sling is repaired, symptoms resolve in the majority of patients. With persistent or new symptoms (10% to 30% of patients), cross-sectional imaging may be helpful to define the post-operative anatomy and determine whether an anatomic abnormality remains for possible reoperation (rather than a functional abnormality). In patients with equivocal symptoms, follow-up pulmonary function and barium swallow testing may be helpful.
3. In a patient diagnosed with a symptomatic vascular ring or PA sling, surgical repair may be performed to relieve symptoms. Discussions about whether to proceed with surgical repair should include multidisciplinary subspecialties, including pulmonary medicine and gastroenterology. Surgical mortality rates are low, but when symptoms persist after repair, tracheomalacia is the most common explanation.<sup>2,6</sup>
4. Surgical repair is not indicated for asymptomatic vascular ring or PA sling. Asymptomatic patients may be followed and/or educated regarding symptoms to return for evaluation.

#### EVIDENCE GAPS AND FUTURE DIRECTIONS

Since the “2018 AHA/ACC Guideline for the Management of Adults With Congenital Heart Disease” was published, new research has further elucidated ACHD topics that include care for TOF, the nuances of the ACHD AP classification system, medical treatment for systemic right ventricles, and pacing and arrhythmia strategies. However, given the sheer breadth of ACHD diagnoses, therapies, late sequelae, and follow-up trajectories for individual patients, designing ACHD clinical trials and enrolling participants in them is a persistent challenge that leaves large evidence and knowledge gaps. In addition, consistent delivery of care is difficult, given inadequate numbers of ACHD physicians, geographic variation in patients’ access to them, and the lack of networks that integrate and coordinate with community care. Even with the progress that the 2025 ACHD guideline reflects, there remain many broad-impact and disease-specific questions for future research to investigate.

## Broad-Impact Research Questions

### General Considerations

- What are the optimal outpatient visit and testing frequencies for the various ACHD physiological stages and congenital heart conditions?
- Does the severity of a patient's anatomic-physiological class matter in deciding whether to deliver cardiology care at an ACHD or a non-ACHD center, to optimize outcomes?
- What is the ideal care delivery system for managing patients with ACHD, in light of geographic, financial, and insurance constraints?
- What are the best ways to develop and test successful methods of transition education and transfer of care?
- How does childhood radiation exposure affect the long-term health of patients with ACHD?
- What are the appropriate neurocognitive screening practices and evaluations for patients with ACHD?
- What type of mental health screening is best for ACHD clinics to conduct?
- Which patients with ACHD should be offered genetic screening?
- How is exercise testing best utilized for predicting clinical outcomes?
- Which ACHD populations will benefit from cardiac rehabilitation?
- Which patients with transcatheter or surgical prosthetic valves are at highest risk for endocarditis? Should prophylaxis and/or screening practices be changed?
- What is the most appropriate timing for pulmonary valve replacement in TOF, pulmonary stenosis with pulmonary regurgitation, and RV-to-PA conduit stenosis or regurgitation?
- What are the effects of menopause, hormone replacement therapy, and gender-affirming therapies in patients with ACHD?
- How do artificial intelligence strategies, such as AI-ECG, fit into ACHD care?

### Heart Failure and Transplantation Considerations

- Which biological mechanisms result in failing right or left ventricles?
- How does GDMT work in failing left ventricles in ACHD (which are likely to have different mechanisms of failure than in ischemia and cardiomyopathy)?
- How does GDMT therapy work in failing right ventricles (subpulmonary or systemic) in ACHD?
- Can principles of guideline-directed and other medical therapies be applied to failing single-ventricle physiology?
- What is the appropriate role of glucagon-like peptide-1 receptor agonists in managing patients with ACHD?

- Which biomarkers are most clinically useful in patients with ACHD?
- Which ACHD conditions can benefit from MCS, and how can it be used in patients with complex anatomy?
- How should criteria for transplantation in patients with Fontan circulation be refined?
- What are the relative benefits and risks of heart versus heart-liver transplantation in Fontan patients, with the aim of determining who should get which strategy?
- What are the best ways to characterize the risk for SCD in patients with ACHD and to identify who will benefit from a primary-prevention ICD?

## Disease-Specific Research Questions

### Shunt Lesions and PAH

- How can predictors of PAH in patients with ACHD be predicted more accurately? Should PAH treatment strategies differ from those for patients without congenital heart disease?
- After shunt repair, how is the type and duration of PAH therapy best determined?
- What are the long-term outcomes of shunt closure in the settings of mild, moderate, and severe PAH?

### COA

- Which measure of hypertension (resting, exercise, or ambulatory) best predicts outcomes in patients with COA?
- Does exercise-induced hypertension require treatment?
- Which criteria warrant reintervention in re-coarctation?
- Are long-term outcomes better with medical therapy or catheter intervention for less-than-severe re-coarctation?
- How often should patients with COA be screened for thoracic aneurysm and for intracranial aneurysm?

### Ebstein Anomaly

- What is the indication for surgery in patients with Ebstein anomaly who are asymptomatic?
- What is the best way to assess the need for a Glenn shunt (bidirectional cavopulmonary anastomosis) at the time of tricuspid valve surgery?

### TOF

- What is the optimal timing of pulmonary valve replacement in asymptomatic patients with TOF?
- Which patients with TOF need a primary-prevention ICD, and does this strategy reduce mortality?
- Can AI-ECG and other artificial intelligence strategies be incorporated into outcome prediction modeling?

- Why does LV dysfunction develop in patients with TOF?
- What clinical parameters can help predict morbidity and mortality in TOF?

#### Systemic Right Ventricle

- Which patients with a systemic right ventricle need a primary-prevention ICD, and does this strategy prevent mortality?
- Which imaging findings predict mortality and morbidity in this population?
- What is the appropriate timing of tricuspid valve replacement for a systemic right ventricle?
- What is the appropriate indication for, and method of, CRT in patients with a systemic right ventricle?
- In patients with CCTGA with VSD/pulmonary stenosis, does the double switch operation have better long-term outcomes than VSD closure and left-ventricle-to-pulmonary-artery conduit?

#### d-TGA With Arterial Switch Operation

- What are the long-term outcomes after the arterial switch operation?
- What is the most effective way to conduct the operation, and how often should the possibility of asymptomatic coronary disease (ostial compression) and ischemia be assessed?
- What are the parameters to intervene for aortic root dilation?

#### Single Ventricle/Fontan Circulation

- What are the risk-benefit calculations for antiplatelet versus anticoagulation strategies in the Fontan population?
- Which Fontan patients will benefit from pulmonary vasodilators?
- What is the appropriate screening strategy for FALD?
- What treatments are most beneficial for protein-losing enteropathy?
- Why do some Fontan patients develop lymphatic abnormalities?
- Do long-term outcomes of HLHS differ from those for other forms of single ventricle with Fontan circulation?

#### Other Conditions

- What level of obstruction merits intervention for double-chamber right ventricle?

- What degree of stenosis is most appropriate for intervention in subaortic obstruction?
- Is there a level of aortic dilation that requires intervention in congenital heart conditions such as TOF, d-TGA with arterial switch, single-ventricle Fontan circulation, and Ross procedure?
- Are patients with manipulated coronary arteries (eg, after arterial switch operation, Ross repair) at risk for premature coronary artery disease?

### PRESIDENTS AND STAFF

#### **American College of Cardiology**

Christopher M. Kramer, MD, FACC, President

Cathleen C. Gates, Chief Executive Officer

Richard J. Kovacs, MD, MACC, Chief Medical Officer

Justine Varieur Turco, MA, Divisional Vice President,  
Scientific Publications & Guidelines

Mindy Saraco, MHA, Director, Clinical Policy and  
Guidelines

Grace D. Ronan, Senior Production and Operations  
Manager, Clinical Policy Publications

Leah Patterson, Project Manager, Clinical Content

#### **American College of Cardiology/American Heart Association**

Thomas S. D. Getchius, National Senior Director,  
Guideline Strategy and Operations

Abdul R. Abdullah, MD, Director, Guideline Science and  
Methodology

Shae Martinez, MLS, Reference Consultant, Medical Librarian  
**American Heart Association**

Keith Churchwell, MD, FAHA, President

Nancy Brown, Chief Executive Officer

Mariell Jessup, MD, FAHA, Chief Science and Medicine  
Officer

Nicole Aiello Sapio, EdD, Executive Vice President,  
Office of Science Strategies and Operations

Radhika Rajgopal Singh, PhD, Senior Vice President,  
Office of Science and Medicine

Prashant Nedungadi, BPharm, PhD, Vice President,  
Science and Medicine, Clinical Guidelines

Barbara Entl, MD, Science and Medicine Advisor,  
Science and Medicine

Joseph W. Loftin III, National Director, Statements and  
Guidelines

Courtney Goodwin, MPH, Program Manager,  
Guidelines

## REFERENCES

### PREAMBLE

1. Committee on Standards for Developing Trustworthy Clinical Practice Guidelines, Institute of Medicine (US). *Clinical Practice Guidelines We Can Trust*. National Academies Press; 2011.
2. Committee on Standards for Systematic Reviews of Comparative Effectiveness Research, Institute of Medicine (US). *Finding What Works in Health Care: Standards for Systematic Reviews*. National Academies Press; 2011.
3. Anderson JL, Heidenreich PA, Barnett PG, et al. ACC/AHA statement on cost/value methodology in clinical practice guidelines and performance measures: a report of the American College of Cardiology/American Heart Association Task Force on Performance Measures and Task Force on Practice Guidelines. *J Am Coll Cardiol*. 2014;63:2304-2322.
4. ACCF/AHA Task Force on Practice Guidelines. Methodology manual and policies from the ACCF/AHA Task Force on Practice Guidelines. *American College of Cardiology and American Heart Association*. 2010. Accessed July 14, 2025. <https://www.acc.org/-/media/Non-Clinical/Files-PDFs-Excel-MS-Word-etc/Guidelines/About-Guidelines-and-Clinical-Documents/Methodology/2014/Methodology-Practice-Guidelines.pdf>
5. Halperin JL, Levine GN, Al-Khatib SM, et al. Further evolution of the ACC/AHA clinical practice guideline recommendation classification system: a report of the American College of Cardiology/American Heart Association Task Force on Clinical Practice Guidelines. *J Am Coll Cardiol*. 2016;67:1572-1574.
6. Arnett DK, Goodman RA, Halperin JL, et al. AHA/ACC/HHS strategies to enhance application of clinical practice guidelines in patients with cardiovascular disease and comorbid conditions: from the American Heart Association, American College of Cardiology, and US Department of Health and Human Services. *J Am Coll Cardiol*. 2014;64:1851-1856.
7. Levine GN, O'Gara PT, Beckman JA, et al. Recent innovations, modifications, and evolution of ACC/AHA clinical practice guidelines: an update for our constituencies: a report of the American College of Cardiology/American Heart Association Task Force on Clinical Practice Guidelines. *J Am Coll Cardiol*. 2019;73:1990-1998.
- 1.4. **Scope of the Guideline**
  1. Mylotte D, Pilote L, Ionescu-Iltu R, et al. Specialized adult congenital heart disease care: the impact of policy on mortality. *Circulation*. 2014;129:1804-1812.
  2. Otto CM, Nishimura RA, Bonow RO, et al. 2020 ACC/AHA guideline for the management of patients with valvular heart disease: a report of the American College of Cardiology/American Heart Association Joint Committee on Clinical Practice Guidelines. *J Am Coll Cardiol*. 2021;77:e25-e197.
  3. Gulati M, Levy PD, Mukherjee D, et al. 2021 AHA/ACC/ASE/CHEST/SAEM/SCCT/SCMR guideline for the evaluation and diagnosis of chest pain: a report of the American College of Cardiology/American Heart Association Joint Committee on Clinical Practice Guidelines. *J Am Coll Cardiol*. 2021;78:e187-e285.
  4. Lawton JS, Tamis-Holland JE, Bangalore S, et al. 2021 ACC/AHA/SCAI guideline for coronary artery revascularization: a report of the American College of Cardiology/American Heart Association Joint Committee on Clinical Practice Guidelines. *J Am Coll Cardiol*. 2022;79:e21-e129.
  5. Heidenreich PA, Bozkurt B, Aguilar D, et al. 2022 AHA/ACC/HFSA guideline for the management of heart failure. *J Am Coll Cardiol*. 2022;79:e263-e421.
  6. Isselbacher EM, Preventza O, Hamilton Black III J, et al. 2022 ACC/AHA guideline for the diagnosis and management of aortic disease: a report of the American Heart Association/American College of Cardiology Joint Committee on Clinical Practice Guidelines. *J Am Coll Cardiol*. 2022;80:e223-e393.
  7. Virani SS, Newby LK, Arnold SV, et al. 2023 AHA/ACC/ACCP/ASPC/NLA/PCNA Guideline for the management of patients with chronic coronary disease: a report of the American Heart Association/American College of Cardiology Joint Committee on Clinical Practice Guidelines. *J Am Coll Cardiol*. 2023;82:833-955.
  8. Joglar JA, Chung MK, Armbruster AL, et al. 2023 ACC/AHA/ACCP/HRS guideline for the diagnosis and management of atrial fibrillation: a report of the American College of Cardiology/American Heart Association Joint Committee on Clinical Practice Guidelines. *J Am Coll Cardiol*. 2024;83:109-279.
  9. Pierpont ME, Brueckner M, Chung WK, et al. Genetic basis for congenital heart disease: revisited: a scientific statement from the American Heart Association. *Circulation*. 2018;138:e653-e711.
  10. Sachdeva R, Valente AM, Armstrong AK, et al. ACC/AHA/ASE/HRS/ISACHD/SCAI/SCCT/SCMR/SOPE 2020 appropriate use criteria for multimodality imaging during the follow-up care of patients with congenital heart disease: a report of the American College of Cardiology Solution Set Oversight Committee and Appropriate Use Criteria Task Force, American Heart Association, American Society of Echocardiography, Heart Rhythm Society, International Society for Adult Congenital Heart Disease, Society for Cardiovascular Angiography and Interventions, Society of Cardiovascular Computed Tomography, Society for Cardiovascular Magnetic Resonance, and Society of Pediatric Echocardiography. *J Am Coll Cardiol*. 2020;75:657-703.
  11. John AS, Jackson JL, Moons P, et al. Advances in managing transition to adulthood for adolescents with congenital heart disease: a practical approach to transition program design: a scientific statement from the American Heart Association. *J Am Heart Assoc*. 2022;11:e025278.
  12. Krieger EV, Zeppenfeld K, DeWitt ES, et al. Arrhythmias in repaired tetralogy of Fallot: a scientific statement from the American Heart Association. *Circ Arrhythm Electrophysiol*. 2022;15:e000084.
  13. Kovacs AH, Brouillette J, Ibeziako P, et al. Psychological outcomes and interventions for individuals with congenital heart disease: a scientific statement from the American Heart Association. *Circ Cardiovasc Qual Outcomes*. 2022;15:e000110.
  14. Kittleson MM, Sharma K, Brennan DC, et al. Dual-organ transplantation: indications, evaluation, and outcomes for heart-kidney and heart-liver transplantation: a scientific statement from the American Heart Association. *Circulation*. 2023;148:622-636.
  15. Sood E, Newburger JW, Anixt JS, et al. Neurodevelopmental outcomes for individuals with congenital heart disease: updates in neuroprotection, risk-stratification, evaluation, and management: a scientific statement from the American Heart Association. *Circulation*. 2024;149:e997-e1022.
- 1.5. **Class of Recommendations and Level of Evidence**
  1. ACCF/AHA Task Force on Practice Guidelines. Methodology manual and policies from the ACCF/AHA Task Force on Practice Guidelines. *American College of Cardiology and American Heart Association*. 2010. Accessed July 14, 2025. <https://www.acc.org/-/media/Non-Clinical/Files-PDFs-Excel-MS-Word-etc/Guidelines/About-Guidelines-and-Clinical-Documents/Methodology/2014/Methodology-Practice-Guidelines.pdf>
  - 2.1.1. **Anatomic Terms**
    1. Giroud JM, Jacobs JP, Spicer D, et al. Report from the international society for nomenclature of paediatric and congenital heart disease: creation of a visual encyclopedia illustrating the terms and definitions of the international pediatric and congenital cardiac code. *World J Pediatr Congenit Heart Surg*. 2010;1:300-313.
    2. Bergersen L, Giroud JM, Jacobs JP, et al. Report from The International Society for Nomenclature of Paediatric and Congenital Heart Disease: cardiovascular catheterisation for congenital and paediatric cardiac disease (Part 2 - Nomenclature of complications associated with interventional cardiology). *Cardiol Young*. 2011;21:260-265.
    3. Bergersen L, Everett AD, Giroud JM, et al. Report from The International Society for Nomenclature of Paediatric and Congenital Heart Disease: cardiovascular catheterisation for congenital and paediatric cardiac disease (Part 1 - Procedural nomenclature). *Cardiol Young*. 2011;21:252-259.
    4. Franklin RC, Jacobs JP, Krogmann ON, et al. Nomenclature for congenital and paediatric cardiac disease: historical perspectives and The International Pediatric and Congenital Cardiac Code. *Cardiol Young*. 2008;18(Suppl 2):70-80.
    5. Franklin RC, Beland MJ, Krogmann ON, et al. Mapping and coding of nomenclatures for paediatric and congenital heart disease. *Cardiol Young*. 2006;16:105-106.
    6. International Society for Nomenclature of Paediatric and Congenital Heart Disease. International paediatric and congenital cardiac code. Accessed December 6, 2024. <http://ipccc.net/>
  - 2.2. **The ACHD Anatomic and Physiological Classification System**
    1. Ombelet F, Goossens E, Apers S, et al. Predicting 15-Year mortality in adults with congenital heart

disease using disease severity and functional indices. *Can J Cardiol.* 2019;35:907-913.

2. Lachtrupp CL, Valente AM, Gurvitz M, et al. Associations between clinical outcomes and a recently proposed adult congenital heart disease anatomic and physiological classification system. *J Am Heart Assoc.* 2021;10:e021345.

3. Geenen LW, Opotowsky AR, Lachtrupp C, et al. Tuning and external validation of an adult congenital heart disease risk prediction model. *Eur Heart J Qual Care Clin Outcomes.* 2022;8:70-78.

4. Egbe AC, Miranda WR, Jain CC, et al. Prognostic value of the anatomic-physiologic classification in adults with congenital heart disease. *Circ Heart Fail.* 2023;16:e010404.

5. Cho MY, Weidenbach M, Sinzobahamvya N, et al. Adult congenital open-heart surgery: emergence of a new mortality score. *Eur J Cardiothorac Surg.* 2020;58:171-176.

6. Homzova L, Photiadis J, Sinzobahamvya N, et al. Surgical management of Ebstein anomaly: impact of the adult congenital heart disease anatomical and physiological classifications. *Interact Cardiovasc Thorac Surg.* 2021;32:593-600.

7. Steiner JM, Lokken E, Bayley E, et al. Cardiac and pregnancy outcomes of pregnant patients with congenital heart disease according to risk classification system. *Am J Cardiol.* 2021;161:95-101.

8. Lachtrupp CL, Valente AM, Gurvitz M, et al. Inter-observer agreement of the anatomic and physiological classification system for adult congenital heart disease. *Am Heart J.* 2020;229:92-99.

9. Cohen S, Liu A, Wang F, et al. Risk prediction models for heart failure admissions in adults with congenital heart disease. *Int J Cardiol.* 2021;322:149-157.

10. Agasthi P, Van Houten HK, Yao X, et al. Mortality and morbidity of heart failure hospitalization in adult patients with congenital heart disease. *J Am Heart Assoc.* 2023;12:e030649.

11. Ntiloudi D, Koutsakis A, Zegkos T, et al. History of heart failure hospitalisation predicts mortality in adult congenital heart disease morbidity and mortality in ACHD. *Int J Cardiol Congenit Heart Dis.* 2021;4:100191.

12. Van Bulck L, Goossens E, Morin L, et al. Last year of life of adults with congenital heart diseases: causes of death and patterns of care. *Eur Heart J.* 2022;43:4483-4492.

13. Popelova JR, Kotaska K, Tomkova M, Tomek J. Usefulness of N-Terminal Pro-Brain natriuretic peptide to predict mortality in adults with congenital heart disease. *Am J Cardiol.* 2015;116:1425-1430.

14. Baggen VJ, van den Bosch AE, Eindhoven JA, et al. Prognostic value of N-Terminal Pro-B-Type natriuretic peptide, Troponin-T, and growth-differentiation factor 15 in adult congenital heart disease. *Circulation.* 2017;135:264-279.

15. Hendriks PM, van den Bosch AE, Geenen LW, et al. Blood biomarkers predict 10-year clinical outcomes in adult patients with congenital heart disease. *JACC Adv.* 2024;3:101130.

16. Burchill LJ, Gao L, Kovacs AH, et al. Hospitalization Trends and Health Resource Use for Adult Congenital Heart Disease-Related Heart Failure. *J Am Heart Assoc.* 2018;7:e008775.

17. Wang F, Liu A, Brophy JM, et al. Determinants of survival in older adults with congenital heart disease newly hospitalized for heart failure. *Circ Heart Fail.* 2020;13:e006490.

18. Tsang W, Silversides CK, Rashid M, et al. Outcomes and healthcare resource utilization in adult congenital heart disease patients with heart failure. *ESC Heart Fail.* 2021;8:4139-4151.

19. Kuijpers JM, Koolbergen DR, Groenink M, et al. Incidence, risk factors, and predictors of infective endocarditis in adult congenital heart disease: focus on the use of prosthetic material. *Eur Heart J.* 2017;38:2048-2056.

20. Tutarel O, Alonso-Gonzalez R, Montanaro C, et al. Infective endocarditis in adults with congenital heart disease remains a lethal disease. *Heart.* 2018;104:161-165.

21. van Melle JP, Roos-Hesselink JW, Bansal M, et al. Infective endocarditis in adult patients with congenital heart disease. *Int J Cardiol.* 2023;370:178-185.

22. Stout KK, Daniels CJ, Aboulhossn JA, et al. 2018 AHA/ACC guideline for the management of adults with congenital heart disease: a report of the American College of Cardiology/American Heart Association Task Force on Clinical Practice Guidelines. *J Am Coll Cardiol.* 2019;73:e81-e192.

23. Khairy P, Aboulhossn J, Gurvitz MZ, et al. Arrhythmia burden in adults with surgically repaired tetralogy of Fallot: a multi-institutional study. *Circulation.* 2010;122:868-875.

24. Verheugt CL, Uiterwaal CS, Velde van der ET, et al. Mortality in adult congenital heart disease. *Eur Heart J.* 2010;31:1220-1229.

25. Khairy P, Fernandes SM, Mayer JE Jr, et al. Long-term survival, modes of death, and predictors of mortality in patients with Fontan surgery. *Circulation.* 2008;117:85-92.

26. Khairy P, Harris L, Landzberg MJ, et al. Implantable cardioverter-defibrillators in tetralogy of Fallot. *Circulation.* 2008;117:363-370.

27. Otto CM, Nishimura RA, Bonow RO, et al. 2020 ACC/AHA guideline for the management of patients with valvular heart disease: a report of the American College of Cardiology/American Heart Association Joint Committee on Clinical Practice Guidelines. *J Am Coll Cardiol.* 2021;77:e25-e197.

28. Diller GP, Dimopoulos K, Okonko D, et al. Exercise intolerance in adult congenital heart disease: comparative severity, correlates, and prognostic implication. *Circulation.* 2005;112:828-835.

29. Buys R, Cornelissen V, Van De Bruaene A, et al. Measures of exercise capacity in adults with congenital heart disease. *Int J Cardiol.* 2011;153:26-30.

30. Gratz A, Hess J, Hager A. Self-estimated physical functioning poorly predicts actual exercise capacity in adolescents and adults with congenital heart disease. *Eur Heart J.* 2009;30:497-504.

31. Dimopoulos K, Okonko DO, Diller GP, et al. Abnormal ventilatory response to exercise in adults with congenital heart disease relates to cyanosis and predicts survival. *Circulation.* 2006;113:2796-2802.

32. Inuzuka R, Diller GP, Borgia F, et al. Comprehensive use of cardiopulmonary exercise testing identifies adults with congenital heart disease at increased mortality risk in the medium term. *Circulation.* 2012;125:250-259.

33. Muller J, Hager A, Diller GP, et al. Peak oxygen uptake, ventilatory efficiency and QRS-duration predict event free survival in patients late after surgical repair of tetralogy of Fallot. *Int J Cardiol.* 2015;196:158-164.

34. Cifra B, Cordina RL, Gauthier N, et al. Cardiopulmonary exercise test interpretation across the lifespan in congenital heart disease: a scientific statement from the American Heart Association. *J Am Heart Assoc.* 2025:e038200.

35. Kempny A, Dimopoulos K, Uebing A, et al. Reference values for exercise limitations among adults with congenital heart disease. Relation to activities of daily living: single centre experience and review of published data. *Eur Heart J.* 2012;33:1386-1396.

36. Dolgin M, ed. *Nomenclature and Criteria for Diagnosis of Diseases of the Heart and Great Vessels.* 9th ed. Little, Brown and Co; 1994.

37. Heidenreich PA, Bozkurt B, Aguilar D, et al. 2022 AHA/ACC/HFSA guideline for the management of heart failure. *J Am Coll Cardiol.* 2022;79:e263-e421.

38. Hoeper MM, Bogaard HJ, Condliffe R, et al. Definitions and diagnosis of pulmonary hypertension. *J Am Coll Cardiol.* 2013;62:D42-D50.

39. Humbert M, Kovacs G, Hoeper MM, et al. 2022 ESC/ERS guidelines for the diagnosis and treatment of pulmonary hypertension. *Eur Heart J.* 2022;43:3618-3731.

### 3.1. Care Access and Delivery in the

#### ACHD Population

1. McGrath L, Taunton M, Levy S, et al. Barriers to care in urban and rural dwelling adults with congenital heart disease. *Cardiol Young.* 2022;32:612-617.

2. Uzark K, Yu S, Lowery R, et al. Transition readiness in teens and young adults with congenital heart disease: can we make a difference? *J Pediatr.* 2020;221:201-206.e1.

3. Werner O, Abassi H, Lavastre K, et al. Factors influencing the participation of adolescents and young adults with a congenital heart disease in a transition education program: a prospective multicentre controlled study. *Patient Educ Couns.* 2019;102:2223-2230.

4. Marelli AJ, Ionescu-Ittu R, Mackie AS, et al. Lifetime prevalence of congenital heart disease in the general population from 2000 to 2010. *Circulation.* 2014;130:749-756.

5. Baumgartner H. Geriatric congenital heart disease: a new challenge in the care of adults with congenital heart disease? *Eur Heart J.* 2014;35:683-685.

6. Benziger CP, Stout K, Zaragoza-Macias E, et al. Projected growth of the adult congenital heart disease population in the United States to 2050: an integrative systems modeling approach. *Popul Health Metr.* 2015;13:29.

7. Liu A, Diller GP, Moons P, et al. Changing epidemiology of congenital heart disease: effect on outcomes and quality of care in adults. *Nat Rev Cardiol.* 2023;20:126-137.

8. Gurvitz M, Valente AM, Broberg C, et al. Prevalence and predictors of gaps in care among adult congenital heart disease patients: HEART-ACHD (the Health, Education, and Access Research Trial). *J Am Coll Cardiol.* 2013;61:2180-2184.

9. Mackie AS, Rempel GR, Rankin KN, et al. Risk factors for loss to follow-up among children and young adults with congenital heart disease. *Cardiol Young*. 2012;22:307-315.
10. Yeung E, Kay J, Roosevelt GE, et al. Lapse of care as a predictor for morbidity in adults with congenital heart disease. *Int J Cardiol*. 2008;125:62-65.
11. Jaiswal V, Deb N, Arora A, et al. Meta-analysis of racial disparity in clinical outcome among congenital heart disease patients postsurgery. *Curr Probl Cardiol*. 2024;49:102098.
12. Rosamilia MB, Williams J, Bair CA, et al. Risk Factors and outcomes associated with gaps in care in children with congenital heart disease. *Pediatr Cardiol*. 2024;45:976-985.
13. Khan AM, McGrath LB, Ramsey K, et al. Distance to care, rural dwelling status, and patterns of care utilization in adult congenital heart disease. *Pediatr Cardiol*. 2022;43:532-540.
14. Woo JL, Anderson BR, Gruenstein D, et al. Minimum travel distance among publicly insured infants with severe congenital heart disease: potential impact of in-state restrictions. *Pediatr Cardiol*. 2019;40:1599-1608.
15. Diller GP, Orwat S, Lammers AE, et al. Lack of specialist care is associated with increased morbidity and mortality in adult congenital heart disease: a population-based study. *Eur Heart J*. 2021;42:4241-4248.
16. Fernandes SM, Marelli A, Hile DM, Daniels CJ. Access and delivery of adult congenital heart disease care in the United States: quality-driven team-based care. *Cardiol Clin*. 2020;38:295-304.
17. Cabrera Fernandez DL, Lopez KN, Bravo-Jaimes K, Mackie AS. The impact of social determinants of health on transition from pediatric to adult cardiology care. *Can J Cardiol*. 2024;40:1043-1055.
18. Fernandes SM, Verstappen A, Clair M, et al. Knowledge of life-long cardiac care by adolescents and young adults with congenital heart disease. *Pediatr Cardiol*. 2019;40:1439-1444.
19. Ducas RA, Mao T, Beauchesne L, et al. Adult congenital heart disease care in Canada: has quality of care improved in the last decade? *Can J Cardiol*. 2024;40:138-147.
20. Borrelli N, Grimaldi N, Papaccioli G, et al. Telemedicine in adult congenital heart disease: usefulness of digital health technology in the assistance of critical patients. *Int J Environ Res Public Health*. 2023;20:5775.
21. Dodeja AK, Schreier M, Granger M, et al. Patient experience with telemedicine in adults with congenital heart disease. *Telemed J E Health*. 2023;29:1261-1265.
22. Zaidi AH, Saleeb SF, Gurvitz M, et al. Social Determinants of Health Including Child Opportunity Index Leading to Gaps in Care for Patients With Significant Congenital Heart Disease. *J Am Heart Assoc*. 2024;13:e028883.

### 3.1.1. Transition Education and Transfer of Care

1. Bratt EL, Mora MA, Sparud-Lundin C, et al. Effectiveness of the STEPSTONES transition program for adolescents with congenital heart disease—a randomized controlled trial. *J Adolesc Health*. 2023;73:655-663.

2. Bredy C, Werner O, Huguet H, et al. Efficacy of a Transition program in adolescents and young adults with congenital heart disease: the TRANSITION-CHD randomized controlled trial. *J Adolesc Health*. 2024;75:358-367.
3. Fernandes SM, Verstappen A, Clair M, et al. Knowledge of life-long cardiac care by adolescents and young adults with congenital heart disease. *Pediatr Cardiol*. 2019;40:1439-1444.
4. Uzark K, Yu S, Lowery R, et al. Transition readiness in teens and young adults with congenital heart disease: can we make a difference? *J Pediatr*. 2020;221:201-206.e1.
5. Werner O, Abassi H, Lavastre K, et al. Factors influencing the participation of adolescents and young adults with a congenital heart disease in a transition education program: a prospective multicentre controlled study. *Patient Educ Couns*. 2019;102:2223-2230.
6. Diller GP, Orwat S, Lammers AE, et al. Lack of specialist care is associated with increased morbidity and mortality in adult congenital heart disease: a population-based study. *Eur Heart J*. 2021;42:4241-4248.
7. Khan AM, McGrath LB, Ramsey K, et al. Distance to care, rural dwelling status, and patterns of care utilization in adult congenital heart disease. *Pediatr Cardiol*. 2022;43:532-540.
8. McGrath L, Taunton M, Levy S, et al. Barriers to care in urban and rural dwelling adults with congenital heart disease. *Cardiol Young*. 2022;32:612-617.
9. Woo JL, Anderson BR, Gruenstein D, et al. Minimum travel distance among publicly insured infants with severe congenital heart disease: potential impact of in-state restrictions. *Pediatr Cardiol*. 2019;40:1599-1608.
10. Yeung E, Kay J, Roosevelt GE, et al. Lapse of care as a predictor for morbidity in adults with congenital heart disease. *Int J Cardiol*. 2008;125:62-65.
11. Mackie AS, Islam S, Magill-Evans J, et al. Healthcare transition for youth with heart disease: a clinical trial. *Heart*. 2014;100:1113-1118.
12. Goossens E, Van Deyk K, Zupancic N, et al. Effectiveness of structured patient education on the knowledge level of adolescents and adults with congenital heart disease. *Eur J Cardiovasc Nurs*. 2014;13:63-70.
13. Mackie AS, Rempel GR, Rankin KN, et al. Risk factors for loss to follow-up among children and young adults with congenital heart disease. *Cardiol Young*. 2012;22:307-315.
14. Sable C, Foster E, Uzark K, et al. Best practices in managing transition to adulthood for adolescents with congenital heart disease: the transition process and medical and psychosocial issues: a scientific statement from the American Heart Association. *Circulation*. 2011;123:1454-1485.
15. Gurvitz M, Valente AM, Broberg C, et al. Prevalence and predictors of gaps in care among adult congenital heart disease patients: HEART-ACHD (the Health, Education, and Access Research Trial). *J Am Coll Cardiol*. 2013;61:2180-2184.
16. Cabrera Fernandez DL, Lopez KN, Bravo-Jaimes K, Mackie AS. The impact of social determinants of health on transition from pediatric to adult cardiology care. *Can J Cardiol*. 2024;40:1043-1055.

17. Swenski TN, Fox KR, Udaipuria S, et al. Age moderates change in disease-related stress among congenital heart disease survivors: a 6-year follow-up. *Eur J Cardiovasc Nurs*. 2024;23:62-68.
18. Helm PC, Kempert S, Körten MA, et al. Congenital heart disease patients' and parents' perception of disease-specific knowledge: health and impairments in everyday life. *Congenit Heart Dis*. 2018;13:377-383.
19. Ladouceur M, Calderon J, Traore M, et al. Educational needs of adolescents with congenital heart disease: impact of a transition intervention programme. *Arch Cardiovasc Dis*. 2017;110:317-324.
20. Rosamilia MB, Williams J, Bair CA, et al. Risk factors and outcomes associated with gaps in care in children with congenital heart disease. *Pediatr Cardiol*. 2024;45:976-985.

### 3.1.2. The ACHD Program and Cardiologists

1. Mylotte D, Pilote L, Ionescu-Ittu R, et al. Specialized adult congenital heart disease care: the impact of policy on mortality. *Circulation*. 2014;129:1804-1812.
2. Nguyen VP, Dolgner SJ, Dardas TF, et al. Improved outcomes of heart transplantation in adults with congenital heart disease receiving regionalized care. *J Am Coll Cardiol*. 2019;74:2908-2918.
3. Diller GP, Orwat S, Lammers AE, et al. Lack of specialist care is associated with increased morbidity and mortality in adult congenital heart disease: a population-based study. *Eur Heart J*. 2021;42:4241-4248.
4. Daniels CJ. The development of adult congenital heart disease care in the United States. *Curr Probl Adolesc Health Care*. 2023;53:101400.
5. Landzberg MJ, Murphy DJ Jr, Davidson WR Jr, et al. Task force 4: organization of delivery systems for adults with congenital heart disease. *J Am Coll Cardiol*. 2001;37:1187-1193.
6. Baumgartner H, Budts W, Chessa M, et al. Recommendations for organization of care for adults with congenital heart disease and for training in the subspecialty of 'Grown-up Congenital Heart Disease' in Europe: a position paper of the Working Group on Grown-up Congenital Heart Disease of the European Society of Cardiology. *Eur Heart J*. 2014;35:686-690.
7. Fernandes SM, Marelli A, Hile DM, Daniels CJ. Access and delivery of adult congenital heart disease care in the United States: quality-driven team-based care. *Cardiol Clin*. 2020;38:295-304.
8. Baumgartner H, de Backer J, Babu-Narayan SV, et al. 2020 ESC guidelines for the management of adult congenital heart disease. *Eur Heart J*. 2021;42:563-645.
9. Waldmann V, Amet D, Zhao A, et al. Catheter ablation in adults with congenital heart disease: a 15-year perspective from a tertiary centre. *Arch Cardiovasc Dis*. 2021;114:455-464.
10. Aboulhosn JA, Hijazi ZM, Kavinsky CJ, et al. SCAI position statement on adult congenital cardiac interventional training, competencies and organizational recommendations. *Catheter Cardiovasc Interv*. 2020;96:643-650.
11. Johnson AJ, McGrath LB, Khan AM, et al. Hospital care for adult patients with congenital heart diseases. *Heart Surg Forum*. 2023;26:e842-e854.
12. Stout KK, Daniels CJ, Aboulhosn JA, et al. 2018 AHA/ACC guideline for the management of adults

with congenital heart disease: a report of the American College of Cardiology/American Heart Association Task Force on Clinical Practice Guidelines. *J Am Coll Cardiol*. 2019;73:e81-e192.

### 3.2. Expertise for Noncardiac Surgery

1. Maxwell BG, Wong JK, Lobato RL. Perioperative morbidity and mortality after noncardiac surgery in young adults with congenital or early acquired heart disease: a retrospective cohort analysis of the National Surgical Quality Improvement Program database. *Am Surg*. 2014;80:321-326.
2. Maxwell BG, Posner KL, Wong JK, et al. Factors contributing to adverse perioperative events in adults with congenital heart disease: a structured analysis of cases from the closed claims project. *Congenit Heart Dis*. 2015;10:21-29.
3. Bianchi P, Constantine A, Costola G, et al. Ultra-fast-track extubation in adult congenital heart surgery. *J Am Heart Assoc*. 2021;10:e020201.
4. Maxwell BG, Wong JK, Kin C, Lobato RL. Perioperative outcomes of major noncardiac surgery in adults with congenital heart disease. *Anesthesiology*. 2013;119:762-769.
5. Rabbitts JA, Groenewald CB, Mauermann WJ, et al. Outcomes of general anesthesia for noncardiac surgery in a series of patients with Fontan palliation. *Paediatr Anaesth*. 2013;23:180-187.
6. Maxwell BG, Williams GD, Ramamoorthy C. Knowledge and attitudes of anesthesia providers about noncardiac surgery in adults with congenital heart disease. *Congenit Heart Dis*. 2014;9:45-53.
7. Nasr VG, Markham LW, Clay M, et al. Perioperative considerations for pediatric patients with congenital heart disease presenting for noncardiac procedures: a scientific statement from the American Heart Association. *Circ Cardiovasc Qual Outcomes*. 2023;16:e000113.
8. Fleisher LA, Fleischmann KE, Auerbach AD, et al. 2014 ACC/AHA guideline on perioperative cardiovascular evaluation and management of patients undergoing noncardiac surgery: a report of the American College of Cardiology/American Heart Association Task Force on practice guidelines. *J Am Coll Cardiol*. 2014;64:e77-e137.
9. Nasr VG, Staffa SJ, Faraoni D, DiNardo JA. Trends in mortality rate in patients with congenital heart disease undergoing noncardiac surgical procedures at children's hospitals. *Sci Rep*. 2021;11:1543.
10. Smilowitz NR, Subashchandra V, Berger JS. Atrial septal defect and the risk of ischemic stroke in the perioperative period of noncardiac surgery. *Am J Cardiol*. 2019;124:1120-1124.
11. Diller GP, Kempny A, Alonso-Gonzalez R, et al. Survival prospects and circumstances of death in contemporary adult congenital heart disease patients under follow-up at a large tertiary centre. *Circulation*. 2015;132:2118-2125.
12. Warner MA, Lunn RJ, O'Leary PW, Schroeder DR. Outcomes of noncardiac surgical procedures in children and adults with congenital heart disease. Mayo Perioperative Outcomes Group. *Mayo Clin Proc*. 1998;73:728-734.
13. Ammash NM, Connolly HM, Abel MD, Warnes CA. Noncardiac surgery in Eisenmenger syndrome. *J Am Coll Cardiol*. 1999;33:222-227.

14. Lipczynska M, Derejska M, Swierczynski R, et al. Noncardiac surgery in Eisenmenger syndrome. *Pol Arch Intern Med*. 2024;134:16652.
  15. Eagle SS, Daves SM. The adult with Fontan physiology: systematic approach to perioperative management for noncardiac surgery. *J Cardiothorac Vasc Anesth*. 2011;25:320-334.
  16. McNamara JR, McMahon A, Griffin M. Perioperative management of the Fontan patient for cardiac and noncardiac surgery. *J Cardiothorac Vasc Anesth*. 2022;36:275-285.
  17. Neethling E, Heggie JE. Considerations in critical-care and anesthetic management of adult patients living with Fontan circulation. *Can J Cardiol*. 2022;38:1100-1110.
  18. Maxwell BG, Maxwell TG, Wong JK. Decentralization of care for adults with congenital heart disease in the United States: a geographic analysis of outpatient surgery. *PLoS One*. 2014;9:e106730.
  19. Mott AR, Fraser CD Jr, McKenzie ED, et al. Perioperative care of the adult with congenital heart disease in a free-standing tertiary pediatric facility. *Pediatr Cardiol*. 2002;23:624-630.
  20. *ACGME Program Requirements for Graduate Medical Education in Anesthesia*. 2023. Published online June 12, 2022. Accessed June 25, 2024. [https://prod.acgme.org/globalassets/pfassets/programrequirements/040\\_anesthesiology\\_2023.pdf](https://prod.acgme.org/globalassets/pfassets/programrequirements/040_anesthesiology_2023.pdf)
  21. Andrews JS, Hashmi NK. Anesthetic management in adults with congenital heart disease. *Curr Cardiol Rep*. 2022;24:235-246.
  22. Baehner T, Ellerkmann RK. Anesthesia in adults with congenital heart disease. *Curr Opin Anaesthesiol*. 2017;30:418-425.
  23. Cheema A, Ibeke S, Nyhan D, Steppan J. When your 35-year-old patient has a sternotomy scar: anesthesia for adult patients with congenital heart disease presenting for noncardiac surgery. *Int Anesthesiol Clin*. 2018;56:3-20.
  24. Goodmanson MM, Latham GJ, Landsem LM, Ross FJ. The year in review: anesthesia for congenital heart disease 2022. *Semin Cardiothorac Vasc Anesth*. 2023;27:114-122.
  25. King M, Belani K. Managing the adult patient with congenital heart disease. *Anesthesiol Clin*. 2020;38:643-662.
  26. Daelman B, Van Bulck L, Luyckx K, et al. Frailty and cognitive function in middle-aged and older adults with congenital heart disease. *J Am Coll Cardiol*. 2024;83:1149-1159.
  27. Stout KK, Daniels CJ, Aboulhosn JA, et al. 2018 AHA/ACC guideline for the management of adults with congenital heart disease: a report of the American College of Cardiology/American Heart Association Task Force on Clinical Practice Guidelines. *J Am Coll Cardiol*. 2019;73:e81-e192.
- ### 3.3. Mental Health and Neurocognitive Assessment
1. Westhoff-Bleck M, Briest J, Fraccarollo D, et al. Mental disorders in adults with congenital heart disease: unmet needs and impact on quality of life. *J Affect Disord*. 2016;204:180-186.
  2. Cook SC, Saidi A, Singh HS, et al. Preprocedural anxiety in adults with congenital heart disease. *JACC Adv*. 2023;2:100589.

3. Kovacs AH, Luyckx K, Thomet C, et al. Anxiety and depression in adults with congenital heart disease. *J Am Coll Cardiol*. 2024;83:430-441.
4. Ferguson M, Kovacs AH. An integrated adult congenital heart disease psychology service. *Congenit Heart Dis*. 2016;11:444-451.
5. Kovacs AH, Grace SL, Kentner AC, et al. Feasibility and outcomes in a pilot randomized controlled trial of a psychosocial intervention for adults with congenital heart disease. *Can J Cardiol*. 2018;34:766-773.
6. Gotink RA, Young JO, Wery MF, et al. Online mindfulness as a promising method to improve exercise capacity in heart disease: 12-month follow-up of a randomized controlled trial. *PLoS One*. 2017;12:e0175923.
7. Daelman B, Van Bulck L, Luyckx K, et al. Frailty and cognitive function in middle-aged and older adults with congenital heart disease. *J Am Coll Cardiol*. 2024;83:1149-1159.
8. Montero-Odasso M, Zou G, Speechley M, et al. Effects of exercise alone or combined with cognitive training and vitamin D supplementation to improve cognition in adults with mild cognitive impairment: a randomized clinical trial. *JAMA Netw Open*. 2023;6:e2324465.
9. Carazo MR, Kolodziej MS, DeWitt ES, et al. Prevalence and prognostic association of a clinical diagnosis of depression in adult congenital heart disease: results of the Boston Adult Congenital Heart Disease Biobank. *J Am Heart Assoc*. 2020;9:e014820.
10. Benderly M, Kalter-Leibovici O, Weitzman D, et al. Depression and anxiety are associated with high health care utilization and mortality among adults with congenital heart disease. *Int J Cardiol*. 2019;276:81-86.
11. Moreland P, Santacroce SJ. Illness uncertainty and posttraumatic stress in young adults with congenital heart disease. *J Cardiovasc Nurs*. 2018;33:356-362.
12. Harrison DJ, Kay J, Jacobsen RM, et al. The burden of psychological trauma and post-traumatic stress disorder among adults with congenital heart disease: PTSD in ACHD. *Am J Cardiol*. 2024;219:9-16.
13. Kroenke K, Spitzer RL, Williams JB, Lowe B. An ultra-brief screening scale for anxiety and depression: the PHQ-4. *Psychosomatics*. 2009;50:613-621.
14. Jackson JL, Saidi A. Mental health screening in congenital heart disease: a call for inclusion as standard of care. Accessed February 2, 2025. <https://www.acc.org/latest-in-cardiology/articles/2024/02/27/16/54/mental-health-screening-in-congenital-heart-disease>
15. Van Bulck L, Goossens E, Luyckx K, et al. Illness identity: a novel predictor for healthcare use in adults with congenital heart disease. *J Am Heart Assoc*. 2018;7:e008723.
16. Verrall CE, Yang JYM, Chen J, et al. Neurocognitive dysfunction and smaller brain volumes in adolescents and adults with a Fontan circulation. *Circulation*. 2021;143:878-891.
17. Cohen S, Earing MG. Neurocognitive impairment and its long-term impact on adults with congenital heart disease. *Prog Cardiovasc Dis*. 2018;61:287-293.
18. Girouard HS, Kovacs AH. Congenital heart disease: education and employment considerations and outcomes. *Int J Cardiol Congenit Heart Dis*. 2020;1:100005.
19. Madsen NL, Marino BS, Woo JG, Olsen M. Comparison of economic self-sufficiency and educational attainment in adults with congenital heart disease

versus siblings without heart disease and to general population. *Am J Cardiol.* 2020;135:135-142.

**20.** Sood E, Newburger JW, Anixt JS, et al. Neurodevelopmental outcomes for individuals with congenital heart disease: updates in neuroprotection, risk-stratification, evaluation, and management: a scientific statement from the American Heart Association. *Circulation.* 2024;149:e997-e1022.

**21.** Jackson JL, Gerardo GM, Monti JD, et al. Executive function and internalizing symptoms in adolescents and young adults with congenital heart disease: the role of coping. *J Pediatr Psychol.* 2018;43:906-915.

**22.** Perrotta ML, Saha P, Zawadzki R, et al. Adults with mild-to-moderate congenital heart disease demonstrate measurable neurocognitive deficits. *J Am Heart Assoc.* 2020;9:e015379.

**23.** Ware J, Butcher JL, Latal B, et al. Neurodevelopmental evaluation strategies for children with congenital heart disease aged birth through 5 years: recommendations from the cardiac neurodevelopmental outcome collaborative. *Cardiol Young.* 2020;30:1609-1622.

**24.** Bagge CN, Henderson VW, Laursen HB, et al. Risk of dementia in adults with congenital heart disease: population-based cohort study. *Circulation.* 2018;137:1912-1920.

### 3.4. Expertise for Cardiac Surgery and Invasive Cardiac Procedures

**1.** Cordina R, Nasir Ahmad S, Kotchetkova I, et al. Management errors in adults with congenital heart disease: prevalence, sources, and consequences. *Eur Heart J.* 2017;39:982-989.

**2.** Maxwell BG, Williams GD, Ramamoorthy C. Knowledge and attitudes of anesthesia providers about noncardiac surgery in adults with congenital heart disease. *Congenit Heart Dis.* 2014;9:45-53.

**3.** Maxwell BG, Posner KL, Wong JK, et al. Factors contributing to adverse perioperative events in adults with congenital heart disease: a structured analysis of cases from the closed claims project. *Congenit Heart Dis.* 2015;10:21-29.

**4.** Karamlou T, Diggs BS, Person T, et al. National practice patterns for management of adult congenital heart disease: operation by pediatric heart surgeons decreases in-hospital death. *Circulation.* 2008;118:2345-2352.

**5.** Brida M, Diller GP, Nashat H, et al. Cardiac catheter intervention complexity and safety outcomes in adult congenital heart disease. *Heart.* 2020;106:1432-1437.

**6.** Ginde S, Bartz PJ, Hill GD, et al. Restrictive lung disease is an independent predictor of exercise intolerance in the adult with congenital heart disease. *Congenit Heart Dis.* 2013;8:246-254.

**7.** Alonso-Gonzalez R, Borgia F, Diller G-P, et al. Abnormal lung function in adults with congenital heart disease: prevalence, relation to cardiac anatomy, and association with survival. *Circulation.* 2013;127:882-890.

**8.** Moon MR, Henn MC, Maniar HS, et al. Impact of surgical experience on operative mortality after reoperative cardiac surgery. *Ann Thorac Surg.* 2020;110:1909-1916.

**9.** Badheka AO, Patel NJ, Grover P, et al. Impact of annual operator and institutional volume on percutaneous coronary intervention outcomes: a 5-year

United States experience (2005-2009). *Circulation.* 2014;130:1392-1406.

**10.** Burt BM, ElBardissi AW, Huckman RS, et al. Influence of experience and the surgical learning curve on long-term patient outcomes in cardiac surgery. *J Thorac Cardiovasc Surg.* 2015;150:1061-1068. e10683.

**11.** Fuller SM, He X, Jacobs JP, et al. Estimating mortality risk for adult congenital heart surgery: an analysis of the Society of Thoracic Surgeons congenital heart surgery database. *Ann Thorac Surg.* 2015;100:1728-1735. discussion 1735-1736.

**12.** Geoffrion T, Fuller S. Surgery for adult congenital heart disease. *Cardiol Clin.* 2020;38:435-443.

**13.** Constantine A, Costola G, Bianchi P, et al. Enhanced assessment of perioperative mortality risk in adults with congenital heart disease. *Journal of the American College of Cardiology.* 2021;78:234-242.

### 3.5. Management of Cyanosis

**1.** Tay EL, Peset A, Papaphylactou M, et al. Replacement therapy for iron deficiency improves exercise capacity and quality of life in patients with cyanotic congenital heart disease and/or the Eisenmenger syndrome. *Int J Cardiol.* 2011;151:307-312.

**2.** Ammash N, Warnes CA. Cerebrovascular events in adult patients with cyanotic congenital heart disease. *J Am Coll Cardiol.* 1996;28:768-772.

**3.** Kagawa M, Takeshita M, Yato S, Kitamura K. Brain abscess in congenital cyanotic heart disease. *J Neurosurg.* 1983;58:913-917.

**4.** Perloff JK, Marelli AJ, Miner PD. Risk of stroke in adults with cyanotic congenital heart disease. *Circulation.* 1993;87:1954-1959.

**5.** Ladouceur M, Benoit L, Basquin A, et al. How pregnancy impacts adult cyanotic congenital heart disease: a multicenter observational study. *Circulation.* 2017;135:2444-2447.

**6.** Opatowsky AR, Moko LE, Ginns J, et al. Pheochromocytoma and paraganglioma in cyanotic congenital heart disease. *J Clin Endocrinol Metab.* 2015;100:1325-1334.

**7.** Jensterle M, Podbregar A, Janez A, et al. Comparison of plasma metanephrines in patients with cyanotic and acyanotic congenital heart disease. *Endocrine.* 2022;78:580-586.

**8.** Rodriguez-Hernandez JL, Rodriguez-Gonzalez F, Riano-Ruiz M, Martinez-Quintana E. Risk factors for hyperuricemia in congenital heart disease patients and its relation to cardiovascular death. *Congenit Heart Dis.* 2018;13:655-662.

**9.** Oya H, Nagaya N, Satoh T, et al. Haemodynamic correlates and prognostic significance of serum uric acid in adult patients with Eisenmenger syndrome. *Heart.* 2000;84:53-58.

**10.** Saxer S, Calendo LR, Lichtblau M, et al. Effect of oxygen therapy on exercise performance in patients with cyanotic congenital heart disease: randomized-controlled trial. *Int J Cardiol.* 2022;348:65-72.

**11.** Poterucha JT, Anavekar NS, Egbe AC, et al. Survival and outcomes of patients with unoperated single ventricle. *Heart.* 2016;102:216-222.

**12.** Martin L, Khalil H. How much reduced hemoglobin is necessary to generate central cyanosis? *Chest.* 1990;97:182-185.

**13.** Broberg CS, Jayaweera AR, Diller GP, et al. Seeking optimal relation between oxygen saturation and hemoglobin concentration in adults with cyanosis from congenital heart disease. *Am J Cardiol.* 2011;107:595-599.

**14.** Broberg CS, Bax BE, Okonko DO, et al. Blood viscosity and its relationship to iron deficiency, symptoms, and exercise capacity in adults with cyanotic congenital heart disease. *J Am Coll Cardiol.* 2006;48:356-365.

**15.** Kaemmerer H, Fratz S, Braun SL, et al. Erythrocyte indexes, iron metabolism, and hyperhomocysteinemia in adults with cyanotic congenital cardiac disease. *Am J Cardiol.* 2004;94:825-828.

**16.** Jensen AS, Johansson PI, Idorn L, et al. The haematocrit an important factor causing impaired haemostasis in patients with cyanotic congenital heart disease. *Int J Cardiol.* 2013;167:1317-1321.

**17.** Kajimoto H, Nakazawa M, Murasaki K, et al. Increased thrombogenicity in patients with cyanotic congenital heart disease. *Circ J.* 2007;71:948-953.

**18.** Broberg C, Ujita M, Babu-Narayan S, et al. Massive pulmonary artery thrombosis with haemoptysis in adults with Eisenmenger's syndrome: a clinical dilemma. *Heart.* 2004;90:e63.

**19.** Horigome H, Hiramatsu Y, Shigeta O, et al. Overproduction of platelet microparticles in cyanotic congenital heart disease with polycythemia. *J Am Coll Cardiol.* 2002;39:1072-1077.

**20.** Sandoval J, Santos LE, Cordova J, et al. Does anticoagulation in Eisenmenger syndrome impact long-term survival? *Congenit Heart Dis.* 2012;7:268-276.

**21.** Oechslin E. Hematological management of the cyanotic adult with congenital heart disease. *Int J Cardiol.* 2004;97(Suppl 1):109-115.

**22.** Broberg CS, Van Woerkom RC, Swallow E, et al. Lung function and gas exchange in Eisenmenger syndrome and their impact on exercise capacity and survival. *Int J Cardiol.* 2014;171:73-77.

**23.** Silversides CK, Grewal J, Mason J, et al. Pregnancy outcomes in women with heart disease: the CARPREG II study. *J Am Coll Cardiol.* 2018;71:2419-2430.

**24.** Drenthen W, Boersma E, Balci A, et al. Predictors of pregnancy complications in women with congenital heart disease. *Eur Heart J.* 2010;31:2124-2132.

**25.** Thorne S, Nelson-Piercy C, MacGregor A, et al. Pregnancy and contraception in heart disease and pulmonary arterial hypertension. *J Fam Plann Reprod Health Care.* 2006;32:75-81.

**26.** Lidegaard O, Lokkegaard E, Svendsen AL, Agger C. Hormonal contraception and risk of venous thromboembolism: national follow-up study. *BMJ.* 2009;339:b2890.

**27.** Lidegaard O, Lokkegaard E, Jensen A, et al. Thrombotic stroke and myocardial infarction with hormonal contraception. *N Engl J Med.* 2012;366:2257-2266.

### 3.6.1. Heart Failure

**1.** Ramdat Misier NL, Moore JP, Nguyen HH, et al. Long-term outcomes of cardiac resynchronization therapy in patients with repaired tetralogy of fallot: a multicenter study. *Circ Arrhythm Electrophysiol.* 2024;17:e012363.

2. Egbe AC, Miranda WR, Pellikka PA, et al. Prevalence and prognostic implications of left ventricular systolic dysfunction in adults with congenital heart disease. *J Am Coll Cardiol.* 2022;79:1356-1365.
  3. Chubb H, Rosenthal DN, Almond CS, et al. Impact of cardiac resynchronization therapy on heart transplant-free survival in pediatric and congenital heart disease patients. *Circ Arrhythm Electrophysiol.* 2020;13:e007925.
  4. Chubb H, Mah DY, Shah M, et al. Multicenter study of survival benefit of cardiac resynchronization therapy in pediatric and congenital heart disease. *JACC Clin Electrophysiol.* 2024;10:539-550.
  5. Neijenhuis RML, MacDonald ST, Zemrak F, et al. Effect of sodium-glucose cotransporter 2 inhibitors in adults with congenital heart disease. *J Am Coll Cardiol.* 2024;83:1403-1414.
  6. Andi K, Abozied O, Miranda WR, et al. Clinical benefits of angiotensin receptor-nepilysin inhibitor in adults with congenital heart disease. *Int J Cardiol.* 2023;387:131152.
  7. Saef J, Sundaravel S, Ortega-Legaspi J, Vaikunth S. Safety and treatment experience with sodium/glucose cotransporter-2 inhibitors in adult patients with congenital heart disease. *J Card Fail.* 2023;29:974-975.
  8. Brouillard AM, Al-Hammadi N, Hunt C, et al. Ten-year outcomes in adult patients with congenital heart disease and implantable cardioverter-defibrillators. *Int J Cardiol.* 2020;313:39-45.
  9. Vehmeijer JT, Brouwer TF, Limpens J, et al. Implantable cardioverter-defibrillators in adults with congenital heart disease: a systematic review and meta-analysis. *Eur Heart J.* 2016;37:1439-1448.
  10. Bozkurt B, Coats AJS, Tsutsui H, et al. Universal definition and classification of heart failure: a report of the Heart Failure Society of America, Heart Failure Association of the European Society of Cardiology, Japanese Heart Failure Society and Writing Committee of the Universal Definition of Heart Failure. *J Card Fail.* 2021;S1071-9164(1021):00050-00056.
  11. Koyak Z, Harris L, de Groot JR, et al. Sudden cardiac death in adult congenital heart disease. *Circulation.* 2012;126:1944-1954.
  12. Heidenreich PA, Bozkurt B, Aguilar D, et al. 2022 AHA/ACC/HFSA guideline for the management of heart failure. *J Am Coll Cardiol.* 2022;79:e263-e421.
  13. Bristow MR, Saxon LA, Boehmer J, et al. Cardiac-resynchronization therapy with or without an implantable defibrillator in advanced chronic heart failure. *N Engl J Med.* 2004;350:2140-2150.
  14. Cleland JG, Daubert JC, Erdmann E, et al. The effect of cardiac resynchronization on morbidity and mortality in heart failure. *N Engl J Med.* 2005;352:1539-1549.
  15. Burstein DS, Rossano JW, Griffis H, et al. Greater admissions, mortality and cost of heart failure in adults with congenital heart disease. *Heart.* 2021;107:807-813.
  16. Dubin AM, Janousek J, Rhee E, et al. Resynchronization therapy in pediatric and congenital heart disease patients: an international multicenter study. *J Am Coll Cardiol.* 2005;46:2277-2283.
  17. Cecchin F, Frangini PA, Brown DW, et al. Cardiac resynchronization therapy (and multisite pacing) in pediatrics and congenital heart disease: five years experience in a single institution. *J Cardiovasc Electrophysiol.* 2009;20:58-65.
  18. Janousek J, Gebauer RA, Abdul-Khalik H, et al. Cardiac resynchronization therapy in paediatric and congenital heart disease: differential effects in various anatomical and functional substrates. *Heart.* 2009;95:1165-1171.
  19. Koyak Z, de Groot JR, Krimly A, et al. Cardiac resynchronization therapy in adults with congenital heart disease. *Europace.* 2018;20:315-322.
  20. Moore JP, de Groot NMS, O'Connor M, et al. Conduction system pacing versus conventional cardiac resynchronization therapy in congenital heart disease. *JACC Clin Electrophysiol.* 2023;9:385-393.
  21. Flügge AK, Wasmer K, Orwat S, et al. Cardiac resynchronization therapy in congenital heart disease: Results from the German National Register for Congenital Heart Defects. *Int J Cardiol.* 2018;273:108-111.
  22. Leyva F, Zegard A, Qiu T, et al. Long-term outcomes of cardiac resynchronization therapy in adult congenital heart disease. *Pacing Clin Electrophysiol.* 2019;42:573-580.
  23. Maurer SJ, Pujol Salvador C, Schiele S, et al. Sacubitril/valsartan for heart failure in adults with complex congenital heart disease. *Int J Cardiol.* 2020;300:137-140.
  24. Lluri G, Lin J, Reardon L, et al. Early experience with sacubitril/valsartan in adult patients with congenital heart disease. *World J Pediatr Congenit Heart Surg.* 2019;10:292-295.
  25. Khairy P, Silka MJ, Moore JP, et al. Sudden cardiac death in congenital heart disease. *Eur Heart J.* 2022;43:2103-2115.
  26. Engelings CC, Helm PC, Abdul-Khalik H, et al. Cause of death in adults with congenital heart disease - an analysis of the German National Register for Congenital Heart Defects. *Int J Cardiol.* 2016;211:31-36.
  27. Silka MJ, Hardy BG, Menashe VD, Morris CD. A population-based prospective evaluation of risk of sudden cardiac death after operation for common congenital heart defects. *J Am Coll Cardiol.* 1998;32:245-251.
  28. Vehmeijer JT, Koyak Z, Leerink JM, et al. Identification of patients at risk of sudden cardiac death in congenital heart disease: the PROspEctive study on implanTable cardIOverter defibrillator therapy and sudden cardiac death in Adults with Congenital Heart Disease (PREVENTION-ACHD). *Heart Rhythm.* 2021;18:785-792.
  29. Attenhofer Jost CH, Tan NY, Hassan A, et al. Sudden death in patients with Ebstein anomaly. *Eur Heart J.* 2018;39:1970-1977a.
  30. Khairy P, Fernandes SM, Mayer JE Jr, et al. Long-term survival, modes of death, and predictors of mortality in patients with Fontan surgery. *Circulation.* 2008;117:85-92.
  31. Pundi KN, Pundi KN, Johnson JN, et al. Sudden cardiac death and late arrhythmias after the Fontan operation. *Congenit Heart Dis.* 2017;12:17-23.
  32. Montanaro C, Arvanitaki A, Kerrigan W, et al. The Fontan Adult Brompton clinical score and mortality risk. *Eur Heart J.* 2025;46:1933-1945.
  33. Schwerzmann M, Salehian O, Harris L, et al. Ventricular arrhythmias and sudden death in adults after a Mustard operation for transposition of the great arteries. *Eur Heart J.* 2009;30:1873-1879.
  34. Ladouceur M, Van De Bruene A, Kauling R, et al. A new score for life-threatening ventricular arrhythmias and sudden cardiac death in adults with transposition of the great arteries and a systemic right ventricle. *Eur Heart J.* 2022;43:2685-2694.
  35. Khairy P, Harris L, Landzberg MJ, et al. Implantable cardioverter-defibrillators in tetralogy of Fallot. *Circulation.* 2008;117:363-370.
  36. ILG, Rosenbaum MS, Lewis M, et al. Inappropriate implantable cardioverter-defibrillator shocks in repaired tetralogy of fallot patients: prevalence and electrophysiological mechanisms. *Int J Cardiol Heart Vasc.* 2020;28:100543.
- ### 3.6.2. Heart Transplantation and MCS
1. Nguyen VP, Dolgner SJ, Dardas TF, et al. Improved outcomes of heart transplantation in adults with congenital heart disease receiving regionalized care. *J Am Coll Cardiol.* 2019;74:2908-2918.
  2. Menachem JN, Lindenfeld J, Schlendorf K, et al. Center volume and post-transplant survival among adults with congenital heart disease. *J Heart Lung Transplant.* 2018;37:1351-1360.
  3. Dimopoulos K, Muthiah K, Alonso-Gonzalez R, et al. Heart or heart-lung transplantation for patients with congenital heart disease in England. *Heart.* 2019;105:596-602.
  4. Wong K, Tecson K, Cedars A. Outcomes of multi-organ transplant in adult patients with congenital heart disease. *J Am Heart Assoc.* 2019;8:e014088.
  5. Vaikunth SS, Ortega-Legaspi JM, Conrad DR, et al. Mortality and morbidity after combined heart and liver transplantation in the failing Fontan: an updated dual center retrospective study. *Clin Transplant.* 2024;38:e15302.
  6. Lewis MJ, Reardon LC, Aboulhosn J, et al. Morbidity and mortality in adult Fontan patients after heart or combined heart-liver transplantation. *J Am Coll Cardiol.* 2023;81:2161-2171.
  7. Zhou AL, Menachem JN, Danford DA, et al. UNOS listing status-related changes in mechanical circulatory support utilization and outcomes in adult congenital heart disease patients. *J Heart Lung Transplant.* 2022;41:889-895.
  8. Das BB, Kogon B, Deshpande SR, et al. Contemporary outcomes of durable ventricular assist devices in adults with congenital heart disease as a bridge to heart transplantation. *Artif Organs.* 2022;46:697-704.
  9. Cedars A, Tecson KM, Zaidi AN, et al. Impact of durable ventricular assist device support on outcomes of patients with congenital heart disease waiting for heart transplant. *Asaio J.* 2020;66:513-519.
  10. Cedars A, Vanderpluym C, Koehl D, et al. An Interagency Registry for Mechanically Assisted Circulatory Support (INTERMACS) analysis of hospitalization, functional status, and mortality after mechanical circulatory support in adults with congenital heart disease. *J Heart Lung Transplant.* 2018;37:619-630.
  11. Diller G-P, Kempny A, Alonso-Gonzalez R, et al. Survival prospects and circumstances of death in

contemporary adult congenital heart disease patients under follow-up at a large tertiary centre. *Circulation*. 2015;132:2118-2125.

12. Zomer AC, Vaartjes I, Uiterwaal CS, et al. Circumstances of death in adult congenital heart disease. *Int J Cardiol*. 2012;154:168-172.

13. Engelings CC, Helm PC, Abdul-Khaliq H, et al. Cause of death in adults with congenital heart disease - an analysis of the German National Register for Congenital Heart Defects. *Int J Cardiol*. 2016;211:31-36.

14. Verheugt CL, Uiterwaal CS, Velde van der ET, et al. Mortality in adult congenital heart disease. *Eur Heart J*. 2010;31:1220-1229.

15. Lewis M, Rosenbaum M. When should adult congenital heart disease patients be considered for transplant and deciding which organs to transplant. *Prog Cardiovasc Dis*. 2018;61:377-381.

16. Stout KK, Broberg CS, Book WM, et al. Chronic heart failure in congenital heart disease: a scientific statement from the American Heart Association. *Circulation*. 2016;133:770-801.

17. Donovan DJ, Richmond ME, Bacha EA, et al. Association between homograft tissue exposure and allosensitization prior to heart transplant in patients with congenital heart disease. *Pediatr Transplant*. 2022;26:e14201.

18. O'Connor MJ, Lind C, Tang X, et al. Persistence of anti-human leukocyte antibodies in congenital heart disease late after surgery using allografts and whole blood. *J Heart Lung Transplant*. 2013;32:390-397.

19. Shaddy RE, Hunter DD, Osborn KA, et al. Prospective analysis of HLA immunogenicity of cryopreserved valved allografts used in pediatric heart surgery. *Circulation*. 1996;94:1063-1067.

20. Rali AS, Ranka S, Mazurek JA, et al. Exception-status listing: a critical pathway to heart transplantation for adults with congenital heart diseases. *J Card Fail*. 2022;28:415-421.

21. Kainuma A, Ning Y, Kurlansky PA, et al. Changes in waitlist and posttransplant outcomes in patients with adult congenital heart disease after the new heart transplant allocation system. *Clin Transplant*. 2021;35:e14458.

22. Dib N, Iserin L, Varnous S, et al. Long-term outcomes after heart transplantation in adult patients with univentricular versus biventricular congenital heart disease. *Eur J Cardiothorac Surg*. 2024;65:ezad410.

23. Alsoufi B, Kozik D, Perrotta M, et al. Trends and outcomes of heart transplantation in adults with congenital heart disease. *Eur J Cardiothorac Surg*. 2024;65:ezae086.

24. Kainuma A, Sanchez J, Ning Y, et al. Outcomes of heart transplantation in adult congenital heart disease with prior intracardiac repair. *Ann Thorac Surg*. 2021;112:846-853.

25. Kainuma A, Ning Y, Kurlansky PA, et al. Cardiac transplantation in adult congenital heart disease with prior sternotomy. *Clin Transplant*. 2021;35:e14229.

26. de la Rosa AL, Singer-Englar T, Tompkins RO, et al. Advanced heart failure and heart transplantation

in adult congenital heart disease in the current era. *Clin Transplant*. 2021;35:e14451.

27. Broda CR, Frankel WC, Nair AP, et al. Continuous-flow ventricular assist device support in adult congenital heart disease: a 15-, multicenter experience of temporary and durable support. *Asaio J*. 2023;69:429-437.

28. Cedars A, Burchill L, Roche SL, et al. Impact of durable ventricular assist devices on post-transplant outcomes in adults with congenital heart disease. *Congenit Heart Dis*. 2019;14:958-962.

29. Heidenreich PA, Bozkurt B, Aguilar D, et al. 2022 AHA/ACC/HFSA guideline for the management of heart failure. *J Am Coll Cardiol*. 2022;79:e263-e421.

30. Maessen L, De Meester P, Troost E, et al. Short-term prognostic value of heart failure diagnosis in a contemporary cohort of patients with adult congenital heart disease. *Can J Cardiol*. 2023;39:292-301.

31. Agasthi P, Van Houten HK, Yao X, et al. Mortality and morbidity of heart failure hospitalization in adult patients with congenital heart disease. *J Am Heart Assoc*. 2023;12:e030649.

32. Egbe AC, Miranda WR, Jain CC, et al. Incidence and outcomes of advanced heart failure in adults with congenital heart disease. *Circ Heart Fail*. 2022;15:e009675.

33. Arnaert S, De Meester P, Troost E, et al. Heart failure related to adult congenital heart disease: prevalence, outcome and risk factors. *ESC Heart Fail*. 2021;8:2940-2950.

34. Burstein DS, Rossano JW, Griffis H, et al. Greater admissions, mortality and cost of heart failure in adults with congenital heart disease. *Heart*. 2021;107:807-813.

35. Wang F, Liu A, Brophy JM, et al. Determinants of survival in older adults with congenital heart disease newly hospitalized for heart failure. *Circ Heart Fail*. 2020;13:e006490.

36. Egbe AC, Miranda WR, Pellikka PA, et al. Prevalence and prognostic implications of left ventricular systolic dysfunction in adults with congenital heart disease. *J Am Coll Cardiol*. 2022;79:1356-1365.

37. Merás P, Riesgo-Gil F, Rybicka J, et al. Heart transplantation at a single tertiary adult congenital heart disease centre: too little, too late? *Int J Cardiol*. 2021;322:107-113.

38. Becher PM, Schrage B, Weimann J, et al. Clinical characteristics and outcomes of patients with adult congenital heart disease listed for heart and heart-lung transplantation in the Eurotransplant region. *J Heart Lung Transplant*. 2020;39:1238-1249.

39. Cunningham JW, Nathan AS, Rhodes J, et al. Decline in peak oxygen consumption over time predicts death or transplantation in adults with a Fontan circulation. *Am Heart J*. 2017;189:184-192.

40. Cristel SH, Thomas G, Göran D, et al. Outcome after heart-lung or lung transplantation in patients with Eisenmenger syndrome. *Heart*. 2020;106:127.

41. Sertic F, Han J, Diagne D, et al. Not all septal defects are equal: outcomes of bilateral lung transplant with cardiac defect repair vs combined heart-lung transplant in patients with Eisenmenger

syndrome in the United States. *Chest*. 2020;158:2097-2106.

42. Hernandez GA, Lemor A, Clark D, et al. Heart transplantation and in-hospital outcomes in adult congenital heart disease patients with Fontan: a decade nationwide analysis from 2004 to 2014. *J Card Surg*. 2020;35:603-608.

43. Wu WK, Siegrist KK, Ziogas IA, et al. Perioperative characteristics and outcomes of fontan versus non-fontan patients undergoing combined heart-liver transplantation: a retrospective cohort study. *J Cardiothorac Vasc Anesth*. 2024;38:745-754.

44. Bakhtiyar SS, Sakowitz S, Ali K, et al. Combined heart-liver vs isolated heart transplantation in adults with congenital heart disease. *Ann Thorac Surg*. 2023;116:1260-1267.

45. Cotter TG, Wang J, Peeraphatdit T, et al. Simultaneous heart-liver transplantation for congenital heart disease in the United States: rapidly increasing with acceptable outcomes. *Hepatology*. 2021;73:1464-1477.

46. Egbe AC, Miranda WR, Jain CC, et al. Improvement in hepatic and renal function following isolated heart transplant in adults with congenital heart disease. *Int J Cardiol*. 2022;364:44-49.

47. Broda CR, Alonso-Gonzalez R, Ghanekar A, et al. Fate of the liver in the survivors of adult heart transplant for a failing Fontan circulation. *J Heart Lung Transplant*. 2022;41:283-286.

48. VanderPluym CJ, Cedars A, Eghtesady P, et al. Outcomes following implantation of mechanical circulatory support in adults with congenital heart disease: an analysis of the Interagency Registry for Mechanically Assisted Circulatory Support (INTERMACS). *J Heart Lung Transplant*. 2018;37:89-99.

### 3.7. Genetic Syndromes Screening

1. van Engelen K, Topf A, Keavney BD, et al. 22q11.2 Deletion Syndrome is under-recognised in adult patients with tetralogy of Fallot and pulmonary atresia. *Heart*. 2010;96:621-624.

2. Palmer LD, McManus Z, Heung T, et al. Reproductive outcomes in adults with 22q11.2 Deletion Syndrome. *Genes (Basel)*. 2022;13:2126.

3. Cowan JR, Ware SM. Genetics and genetic testing in congenital heart disease. *Clin Perinatol*. 2015;42:373-393.

4. Hartman RJ, Rasmussen SA, Botto LD, et al. The contribution of chromosomal abnormalities to congenital heart defects: a population-based study. *Pediatr Cardiol*. 2011;32:1147-1157.

5. Carey AS, Liang L, Edwards J, et al. Effect of copy number variants on outcomes for infants with single ventricle heart defects. *Circ Cardiovasc Genet*. 2013;6:444-451.

6. Kim DS, Kim JH, Burt AA, et al. Burden of potentially pathologic copy number variants is higher in children with isolated congenital heart disease and significantly impairs covariate-adjusted transplant-free survival. *J Thorac Cardiovasc Surg*. 2016;151:1147-1151.e4.

7. Glessner JT, Bick AG, Ito K, et al. Increased frequency of de novo copy number variants in congenital heart disease by integrative analysis of single

nucleotide polymorphism array and exome sequence data. *Circ Res*. 2014;115:884-896.

8. Zaidi S, Choi M, Wakimoto H, et al. De novo mutations in histone-modifying genes in congenital heart disease. *Nature*. 2013;498:220-223.

9. van der Bom T, Zomer AC, Zwinderman AH, et al. The changing epidemiology of congenital heart disease. *Nat Rev Cardiol*. 2011;8:50-60.

10. Homsy J, Zaidi S, Shen Y, et al. De novo mutations in congenital heart disease with neurodevelopmental and other congenital anomalies. *Science*. 2015;350:1262-1266.

11. Broda CR, Salciccioli KB, Lopez KN, et al. Outcomes in adults with congenital heart disease and heterotaxy syndrome: a single-center experience. *Congenit Heart Dis*. 2019;14:885-894.

12. Lin AE, Krikov S, Riehle-Colarusso T, et al. Laterality defects in the national birth defects prevention study (1998-2007): birth prevalence and descriptive epidemiology. *Am J Med Genet A*. 2014;164A:2581-2591.

13. Harden B, Tian X, Giese R, et al. Increased post-operative respiratory complications in heterotaxy congenital heart disease patients with respiratory ciliary dysfunction. *J Thorac Cardiovasc Surg*. 2014;147:1291-1298.e2.

14. Nakhleh N, Francis R, Giese RA, et al. High prevalence of respiratory ciliary dysfunction in congenital heart disease patients with heterotaxy. *Circulation*. 2012;125:2232-2242.

15. Swisher M, Jonas R, Tian X, et al. Increased post-operative and respiratory complications in patients with congenital heart disease associated with heterotaxy. *J Thorac Cardiovasc Surg*. 2011;141:637-644, 644.e1-3.

16. Anaclerio S, Di Ciommo V, Michielon G, et al. Conotruncal heart defects: impact of genetic syndromes on immediate operative mortality. *Ital Heart J*. 2004;5:624-628.

17. Mahle WT, Crisalli J, Coleman K, et al. Deletion of chromosome 22q11.2 and outcome in patients with pulmonary atresia and ventricular septal defect. *Ann Thorac Surg*. 2003;76:567-571.

18. Peyvandi S, Lupo PJ, Garbarini J, et al. 22q11.2 deletions in patients with conotruncal defects: data from 1,610 consecutive cases. *Pediatr Cardiol*. 2013;34:1687-1694.

19. De Backer J, Bondue A, Budts W, et al. Genetic counselling and testing in adults with congenital heart disease: a consensus document of the ESC Working Group of Grown-Up Congenital Heart Disease, the ESC Working Group on Aorta and Peripheral Vascular Disease and the European Society of Human Genetics. *Eur J Prev Cardiol*. 2020;27:1423-1435.

20. Pierpont ME, Brueckner M, Chung WK, et al. Genetic basis for congenital heart disease: revisited: a scientific statement from the American Heart Association. *Circulation*. 2018;138:e653-e711.

21. Musunuru K, Hershberger RE, Day SM, et al. Genetic testing for inherited cardiovascular diseases: a scientific statement from the American Heart Association. *Circ Genom Precis Med*. 2020;13:e000067.

22. van Engelen K, Baars MJ, Felix JP, et al. The value of the clinical geneticist caring for adults with congenital heart disease: diagnostic yield and

patients' perspective. *Am J Med Genet A*. 2013;161A:1628-1637.

23. Nugent DJ, Romano AA, Sabharwal S, Cooper DL. Evaluation of bleeding disorders in patients with Noonan syndrome: a systematic review. *J Blood Med*. 2018;9:185-192.

24. Wessel A, Gravenhorst V, Buchhorn R, et al. Risk of sudden death in the Williams-Beuren syndrome. *Am J Med Genet A*. 2004;127A:234-237.

25. Collins RT 2nd, Aziz PF, Gleason MM, et al. Abnormalities of cardiac repolarization in Williams syndrome. *Am J Cardiol*. 2010;106:1029-1033.

26. Bull MJ. Down Syndrome. *N Engl J Med*. 2020;382:2344-2352.

27. Dimopoulos K, Constantine A, Clift P, et al. Cardiovascular complications of Down syndrome: scoping review and expert consensus. *Circulation*. 2023;147:425-441.

28. Basson CT, Cowley GS, Solomon SD, et al. The clinical and genetic spectrum of the Holt-Oram syndrome (heart-hand syndrome). *N Engl J Med*. 1994;330:885-891.

29. McDermott DA, Bressan MC, He J, et al. TBX5 genetic testing validates strict clinical criteria for Holt-Oram syndrome. *Pediatr Res*. 2005;58:981-986.

30. Sesti F, Pofi R, Pozza C, et al. Cardiovascular complications in patients with Klinefelter's syndrome. *Curr Pharm Des*. 2020;26:5556-5563.

31. Tartaglia M, Mehler EL, Goldberg R, et al. Mutations in PTPN11, encoding the protein tyrosine phosphatase SHP-2, cause Noonan syndrome. *Nat Genet*. 2001;29:465-468.

32. Roberts AE, Allanson JE, Tartaglia M, Gelb BD. Noonan syndrome. *Lancet*. 2013;381:333-342.

33. Gravholt CH, Andersen NH, Conway GS, et al. Clinical practice guidelines for the care of girls and women with Turner syndrome: proceedings from the 2016 Cincinnati International Turner Syndrome Meeting. *Eur J Endocrinol*. 2017;177:G1-G70.

34. Levitsky LL, Luria AH, Hayes FJ, Lin AE. Turner syndrome: update on biology and management across the life span. *Curr Opin Endocrinol Diabetes Obes*. 2015;22:65-72.

35. Sybert VP, McCauley E. Turner's syndrome. *N Engl J Med*. 2004;351:1227-1238.

36. Brink BD, Feinn R, Kozel BA, et al. Frequency of QTc interval prolongation in children and adults with Williams Syndrome. *Pediatr Cardiol*. 2022;43:1559-1567.

37. Ewart AK, Morris CA, Atkinson D, et al. Hemizygosity at the elastin locus in a developmental disorder, Williams syndrome. *Nat Genet*. 1993;5:11-16.

38. Emerick KM, Rand EB, Goldmuntz E, et al. Features of Alagille syndrome in 92 patients: frequency and relation to prognosis. *Hepatology*. 1999;29:822-829.

39. Kamath BM, Bason L, Piccoli DA, et al. Consequences of JAG1 mutations. *J Med Genet*. 2003;40:891-895.

40. Stout KK, Daniels CJ, Aboulhosn JA, et al. 2018 AHA/ACC guideline for the management of adults with congenital heart disease: a report of the American College of Cardiology/American Heart Association Task Force on Clinical Practice Guidelines. *J Am Coll Cardiol*. 2019;73:e81-e192.

### 3.8. Reproductive Health, Pregnancy, and Contraception

1. Silversides CK, Grewal J, Mason J, et al. Pregnancy outcomes in women with heart disease: the CARPREG II study. *J Am Coll Cardiol*. 2018;71:2419-2430.

2. Herrick N, Al-Rousan T, Rodriguez C, et al. Priorities and understanding of pregnancy among women with congenital heart disease: a mixed-methods study. *JACC Adv*. 2022;1:100112.

3. Miner PD, Canobbio MM, Pearson DD, et al. Contraceptive practices of women with complex congenital heart disease. *Am J Cardiol*. 2017;119:911-915.

4. Baro-Marine F, Pijuan-Domenech A, Goya MDM, et al. Progestogen only contraception in women with congenital heart disease. *J Obstet Gynaecol*. 2024;44:2320296.

5. van Hagen IM, Boersma E, Johnson MR, et al. Global cardiac risk assessment in the registry of pregnancy and cardiac disease: results of a registry from the European Society of Cardiology. *Eur J Heart Fail*. 2016;18:523-533.

6. Oyen N, Poulsen G, Boyd HA, et al. Recurrence of congenital heart defects in families. *Circulation*. 2009;120:295-301.

7. Fesslova V, Brankovic J, Lalatta F, et al. Recurrence of congenital heart disease in cases with familial risk screened prenatally by echocardiography. *J Pregnancy*. 2011;2011:368067.

8. Mayer F, Bick D, Taylor C. Multidisciplinary care for pregnant women with cardiac disease: a mixed methods evaluation. *Int J Nurs Stud*. 2018;85:96-105.

9. McCoy JA, Kim YY, Nyman A, Levine LD. Pregnancy-related cardiac outcomes among patients with congenital heart disease after formalization of a cardio-obstetrics program. *Am J Obstet Gynecol MFM*. 2024;6:101335.

10. Panah LG, Menachem JN, Boos EW, Lindley KJ. Pregnancy and adult congenital heart disease in a post-Roe world. *J Card Fail*. 2023;29:1556-1560.

11. Sarma AA, Lau ES, Sharma G, et al. Maternal cardiovascular health post-Dobbs. *NEJM Evid*. 2024;3: EVIDra2300273.

12. Schott JJ, Benson DW, Basson CT, et al. Congenital heart disease caused by mutations in the transcription factor NKX2-5. *Science*. 1998;281:108-111.

13. Ferencz C, Neill CA, Boughman JA, et al. Congenital cardiovascular malformations associated with chromosome abnormalities: an epidemiologic study. *J Pediatr*. 1989;114:79-86.

14. Easter SR, Rouse CE, Duarte V, et al. Planned vaginal delivery and cardiovascular morbidity in pregnant women with heart disease. *Am J Obstet Gynecol*. 2020;222(77):e71-77.e11.

15. Lalude OO. Risk of cardiovascular events with hormonal contraception: insights from the Danish cohort study. *Curr Cardiol Rep*. 2013;15:374.

16. Kovacs AH, Harrison JL, Colman JM, et al. Pregnancy and contraception in congenital heart disease: what women are not told. *J Am Coll Cardiol*. 2008;52:577-578.

17. Sliwa K, van der Meer P, Petrie MC, et al. Risk stratification and management of women with cardiomyopathy/heart failure planning pregnancy or presenting during/after pregnancy: a position

statement from the Heart Failure Association of the European Society of Cardiology Study Group on Peripartum Cardiomyopathy. *Eur J Heart Fail.* 2021;23:527-540.

18. Hayes SN, Kim ESH, Saw J, et al. Spontaneous coronary artery dissection: current state of the science: a scientific statement from the American Heart Association. *Circulation.* 2018;137:e523-e557.

19. Otto CM, Nishimura RA, Bonow RO, et al. 2020 ACC/AHA guideline for the management of patients with valvular heart disease: a report of the American College of Cardiology/American Heart Association Joint Committee on Clinical Practice Guidelines. *J Am Coll Cardiol.* 2021;77:e25-e197.

20. Pfaller B, Sathananthan G, Grewal J, et al. Preventing complications in pregnant women with cardiac disease. *J Am Coll Cardiol.* 2020;75:1443-1452.

21. Halpern DG, Penfield CA, Feinberg JL, Small AJ. Reproductive health in congenital heart disease: preconception, pregnancy, and postpartum. *J Cardiovasc Dev Dis.* 2023;10:186.

22. Trinh A, Vyas A, Roselle A, et al. Contraception and cardiovascular effects: what should the cardiologist know? *Curr Cardiol Rep.* 2023;25:1489-1498.

23. Teal S, Edelman A. Contraception selection, effectiveness, and adverse effects: a review. *JAMA.* 2021;326:2507-2518.

24. Feyissa TR, Akter S, Harris ML. Contraceptive counselling and uptake of contraception among women with cardiovascular diseases: a systematic review and meta-analysis. *Clin Res Cardiol.* 2024;113:1151-1170.

25. Nana M, Stannard MT, Nelson-Piercy C, Williamson C. The impact of preconception counselling on maternal and fetal outcomes in women with chronic medical conditions: a systematic review. *Eur J Intern Med.* 2023;108:52-59.

26. Kloster S, Tolstrup JS, Nielsen DG, et al. Long-term cardiovascular health after pregnancy in Danish women with congenital heart disease. A register-based cohort study between 1993 and 2016. *J Am Heart Assoc.* 2022;11:e023588.

27. Halpern DG, Weinberg CR, Pinnelas R, et al. Use of medication for cardiovascular disease during pregnancy: JACC state-of-the-art review. *J Am Coll Cardiol.* 2019;73:457-476.

28. Brodwall K, Greve G, Leirgul E, et al. Recurrence of congenital heart defects among siblings—a nationwide study. *Am J Med Genet A.* 2017;173:1575-1585.

29. Moon-Grady AJ, Donofrio MT, Gelehrter S, et al. Guidelines and recommendations for performance of the fetal echocardiogram: an update from the American Society of Echocardiography. *J Am Soc Echocardiogr.* 2023;36:679-723.

30. Easter SR, Valente AM, Economy KE. Creating a multidisciplinary pregnancy heart team. *Curr Treat Options Cardiovasc Med.* 2020;22:3.

31. Batchelor WB, Anwaruddin S, Wang DD, et al. The multidisciplinary heart team in cardiovascular medicine: current role and future challenges. *JACC Adv.* 2023;2:100160.

32. Mecdi Kaydirak M, Aslan E. Efficacy of nursing support in the pre- and postmedical termination of pregnancy phases: a randomized study. *Omega (Westport).* 2021;84:51-68.

33. Lu CW, Wu MH, Wang JK, et al. Preconception counseling for women with congenital heart disease. *Acta Cardiol Sin.* 2015;31:500-506.

34. Morales A, Allain DC, Arcsott P, et al. At the heart of the pregnancy: what prenatal and cardiovascular genetic counselors need to know about maternal heart disease. *J Genet Couns.* 2017;26:669-688.

35. van der Zande JA, Wander G, Ramlakhan KP, et al. Reproductive health in adults with congenital heart disease: a review on fertility, sexual health, assisted reproductive technology and contraception. *Expert Rev Cardiovasc Ther.* 2023;21:519-529.

36. Umazume T, Yamada T, Furuta I, et al. Morphofunctional cardiac changes in singleton and twin pregnancies: a longitudinal cohort study. *BMC Pregnancy Childbirth.* 2020;20:750.

37. Angeli L, Fieni S, Dall'Asta A, et al. Mode of delivery and peripartum outcome in women with heart disease according to the ESC guidelines: an Italian multicenter study. *J Matern Fetal Neonatal Med.* 2023;36:2184221.

38. McCoy JA, Kim YY, Nyman A, Levine LD. Prolonged labor and adverse cardiac outcomes in pregnant patients with congenital heart disease. *Am J Obstet Gynecol.* 2023;228:728.e1-728.e8.

39. Regitz-Zagrosek V, Roos-Hesselink JW, Bauersachs J, et al. 2018 ESC guidelines for the management of cardiovascular diseases during pregnancy. *Eur Heart J.* 2018;39:3165-3241.

### 3.9. Ionizing Radiation Exposure

1. Cohen S, Liu A, Survitz M, et al. Exposure to low-dose ionizing radiation from cardiac procedures and malignancy risk in adults with congenital heart disease. *Circulation.* 2018;137:1334-1345.

2. Johnson JN, Hornik CP, Li JS, et al. Cumulative radiation exposure and cancer risk estimation in children with heart disease. *Circulation.* 2014;130:161-167.

3. Andreassi MG, Ait-Ali L, Botto N, et al. Cardiac catheterization and long-term chromosomal damage in children with congenital heart disease. *Eur Heart J.* 2006;27:2703-2708.

4. Glatz AC, Purrington KS, Klinger A, et al. Cumulative exposure to medical radiation for children requiring surgery for congenital heart disease. *J Pediatr.* 2014;164:789-794.e10.

5. Campolo J, Annoni G, Vignati G, et al. The burden of radiation exposure in congenital heart disease: the Italian cohort profile and bioresource collection in HARMONIC project. *Ital J Pediatr.* 2024;50:100.

6. Quinn BP, Cevallos P, Armstrong A, et al. Longitudinal improvements in radiation exposure in cardiac catheterization for congenital heart disease: a prospective multicenter C3PO-QI study. *Circ Cardiovasc Interv.* 2020;13:e008172.

#### 3.10.1. Exercise Testing

1. Wadey CA, Weston ME, Dorobantu DM, et al. The role of cardiopulmonary exercise testing in predicting mortality and morbidity in people with congenital heart disease: a systematic review and meta-analysis. *Eur J Prev Cardiol.* 2022;29:513-533.

2. Udholm S, Aldweib N, Hjortdal VE, Veldtman GR. Prognostic power of cardiopulmonary exercise testing

in Fontan patients: a systematic review. *Open Heart.* 2018;5:e000812.

3. Müller J, Amberger T, Berg A, et al. Physical activity assessment in patients with congenital heart disease and associations to exercise capacity and health related quality of life. *Cardiol Young.* 2017;27:53.

4. De Santis J, Constantine A, Ministeri M, et al. Strong association between cardio-pulmonary exercise parameters and mortality in adults with transposition of the great arteries and a systemic right ventricle. *Eur Heart J.* 2020;41:2219.

5. Nashat H, Kempny A, Harries C, et al. A single-centre, placebo-controlled, double-blind randomised cross-over study of nebulised iloprost in patients with Eisenmenger syndrome: a pilot study. *Int J Cardiol.* 2019;299:131-135.

6. Mendel B, Christianto Setiawan M, et al. Pharmacology management in improving exercise capacity of patients with Fontan circulation: a systematic review and meta-analysis. *Curr Cardiol Rev.* 2022;18:34-49.

7. Wikner A, Sandstrom A, Rinnstrom D, et al. Impaired exercise capacity and mortality risk in adults with congenital heart disease. *JACC Adv.* 2023;2:100422.

8. Bredy C, Ministeri M, Kempny A, et al. New York Heart Association (NYHA) classification in adults with congenital heart disease: relation to objective measures of exercise and outcome. *Eur Heart J Qual Care Clin Outcomes.* 2018;4:51-58.

9. Diller GP, Dimopoulos K, Okonko D, et al. Exercise intolerance in adult congenital heart disease: comparative severity, correlates, and prognostic implication. *Circulation.* 2005;112:828-835.

10. Eshuis G, Hock J, Hillege JL, et al. Longitudinal analysis of exercise performance in patients after tetralogy of Fallot repair. *Cardiol Young.* 2019;29:530.

11. Miranda WR, Jain CC, Borlaug BA, et al. Exercise capacity, NT-proBNP, and exercise hemodynamics in adults post-fontan. *J Am Coll Cardiol.* 2023;81:1590-1600.

12. Jones J, Khan S, Taufik A, et al. Serial cardiopulmonary exercise testing in adult congenital heart disease patients. The rise and fall of peak predicted VO2 max. *Cardiol Young.* 2022;32:594-595.

13. Das BB, Young ML, Niu J, et al. Relation between New York Heart Association functional class and objective measures of cardiopulmonary exercise in adults with congenital heart disease. *Am J Cardiol.* 2019;123:1868-1873.

14. Babu-Narayan SV, Diller GP, Gheta RR, et al. Clinical outcomes of surgical pulmonary valve replacement after repair of tetralogy of Fallot and potential prognostic value of preoperative cardiopulmonary exercise testing. *Circulation.* 2014;129:18-27.

15. Dallaire F, Wald RM, Marelli A. The role of cardiopulmonary exercise testing for decision making in patients with repaired tetralogy of Fallot. *Pediatr Cardiol.* 2017;38:1097-1105.

16. Cifra B, Cordina RL, Gauthier N, et al. Cardiopulmonary exercise test interpretation across the lifespan in congenital heart disease: a scientific statement from the American Heart Association. *J Am Heart Assoc.* 2025:e038200.

17. Marko Novakovic M, Prokselj K, Fras Z, Jug B. Impaired exercise capacity is associated with impaired cardiac and vascular function, and increased

levels of disease-specific biomarkers in adults with repaired tetralogy of Fallot. *Eur J Prev Cardiol.* 2018;25:5133.

18. Sato M, Inai K, Mori H, et al. Bioelectrical impedance parameters are determinants for exercise capacity in the patients with adult congenital heart disease. *Eur Heart J.* 2018;39:243.

19. Aguiar Rosa S, Agapito A, Soares RM, et al. Congenital heart disease in adults: assessment of functional capacity using cardiopulmonary exercise testing. *Rev Port Cardiol (Engl Ed).* 2018;37:399-405.

20. Radke RM, Bietenbeck M, Meier C, et al. Exercise testing and multi-parametric CMR assessment in patients with Ebstein anomaly. *Eur Heart J.* 2019;40:219.

21. Warmerdam EG, Magni F, Leiner T, et al. Imaging parameters predictive for exercise capacity in patients after the arterial switch operation. *Cardiol Young.* 2019;29:S127.

22. Autoren Soto Hurtado E, Lobera E, Rodríguez Gallego Y. Congenital heart disease and utility of cardiopulmonary exercise testing. *Pneumologie.* 2023;77:514.

23. Birkey T, Dixon J, Jacobsen R, et al. Cardiopulmonary exercise testing for surgical risk stratification in adults with congenital heart disease. *Pediatr Cardiol.* 2018;39:1468-1475.

24. Shafer KM, Opatowsky AR, Rhodes J. Exercise testing and spirometry as predictors of mortality in congenital heart disease: contrasting Fontan physiology with repaired tetralogy of Fallot. *Congenit Heart Dis.* 2018;13:903-910.

25. Zhang H, He Y, Wang L, et al. Prognostic implications of cardiopulmonary exercise testing in congenital heart disease associated with pulmonary arterial hypertension. *Am J Respir Crit Care Med.* 2018;197:A7676.

26. Gonçalves AAV, Mano T, Agapito A, et al. Prognostic power of cardiopulmonary exercise test to predict heart failure events in patients with transposition of the great arteries. *J Am Coll Cardiol.* 2019;73:621.

27. Buys R, Van De Bruaene A, Muller J, et al. Usefulness of cardiopulmonary exercise testing to predict the development of arterial hypertension in adult patients with repaired isolated coarctation of the aorta. *Int J Cardiol.* 2013;168:2037-2041.

28. Kempny A, Dimopoulos K, Alonso-Gonzalez R, et al. Six-minute walk test distance and resting oxygen saturations but not functional class predict outcome in adult patients with Eisenmenger syndrome. *Int J Cardiol.* 2013;168:4784-4789.

29. van Dissel AC, D'Alto M, Farro A, et al. Improved risk prediction using a refined European guidelines instrument in pulmonary arterial hypertension related to congenital heart disease. *Am J Cardiol.* 2024;223:28-34.

30. Borg E, Borg G, Larsson K, et al. An index for breathlessness and leg fatigue. *Scand J Med Sci Sports.* 2010;20:644-650.

31. Niedeggen A, Skobel E, Haager P, et al. Comparison of the 6-minute walk test with established parameters for assessment of cardiopulmonary capacity in adults with complex congenital cardiac disease. *Cardiol Young.* 2005;15:385-390.

### 3.10.2. Physical Activity, Exercise, and Sports Participation

1. Li X, Chen N, Zhou X, et al. Exercise training in adults with congenital heart disease: a systematic review and meta analysis. *J Cardiopulm Rehabil Prev.* 2019;39:299-307.

2. Meyer M, Brudy L, García-Cuenllas L, et al. Current state of home-based exercise interventions in patients with congenital heart disease: a systematic review. *Heart.* 2020;106:333-341.

3. Schuermans A, Boerma M, Sansoni GA, et al. Exercise in patients with repaired tetralogy of Fallot: a systematic review and meta-analysis. *Heart.* 2023;109:984-991.

4. van Dissel AC, Blok IM, Hooglugt JQ, et al. Safety and effectiveness of home-based, self-selected exercise training in symptomatic adults with congenital heart disease: a prospective, randomised, controlled trial. *Int J Cardiol.* 2019;278:59-64.

5. Bhasipol A, Sanjaroensuttikul N, Pornsuriyasak P, et al. Efficiency of the home cardiac rehabilitation program for adults with complex congenital heart disease. *Congenit Heart Dis.* 2018;13:952-958.

6. Turquetto ALR, Dos Santos MR, Agostinho DR, et al. Aerobic exercise and inspiratory muscle training increase functional capacity in patients with univentricular physiology after Fontan operation: a randomized controlled trial. *Int J Cardiol.* 2021;330:50-58.

7. Sandberg C, Hedström M, Wadell K, et al. Home-based interval training increases endurance capacity in adults with complex congenital heart disease. *Congenit Heart Dis.* 2018;13:254-262.

8. Opatowsky AR, Rhodes J, Landzberg MJ, et al. A randomized trial comparing cardiac rehabilitation to standard of care for adults with congenital heart disease. *World J Pediatr Congenit Heart Surg.* 2018;9:185-193.

9. Novaković M, Prokšelj K, Rajković U, et al. Exercise training in adults with repaired tetralogy of Fallot: a randomized controlled pilot study of continuous versus interval training. *Int J Cardiol.* 2018;255:37-44.

10. Stout KK, Daniels CJ, Aboulhosn JA, et al. 2018 AHA/ACC guideline for the management of adults with congenital heart disease: executive summary: a report of the American College of Cardiology/American Heart Association Task Force on Clinical Practice Guidelines. *J Am Coll Cardiol.* 2019;73:1494-1563.

11. Chaix MA, Marcotte F, Dore A, et al. Risks and benefits of exercise training in adults with congenital heart disease. *Can J Cardiol.* 2016;32:459-466.

12. Barry OM, Gauvreau K, Rhodes J, et al. Incidence and predictors of clinically important and dangerous arrhythmias during exercise tests in pediatric and congenital heart disease patients. *JACC Clin Electro-physiol.* 2018;4:1319-1327.

13. Hooglugt JQ, van Dissel AC, De Haan FH, et al. Efficacy and compliance of long-term, individualised exercise training in adults with congenital heart disease and heart failure symptoms: a randomized controlled trial. *Eur Heart J.* 2018;39:245.

14. Dwiputra B, Ambari AM, Santoso AS, et al. Improvement of 6-minute walking distance after phase II cardiac rehabilitation program in

postoperative grown-up congenital heart (GUCH) disease patients: a 10-year experience. *Eur J Prev Cardiol.* 2019;26:532.

15. Fritz C, Müller J, Oberhoffer R, et al. Inspiratory muscle training did not improve exercise capacity and lung function in adult patients with Fontan circulation: a randomized controlled trial. *Int J Cardiol.* 2020;319:69-70.

16. Radi B, Intan R, Susilowati E, et al. Effect and determinant of early phase II cardiac rehabilitation program on functional capacity in grown up congenital heart disease (GUCH) patients underwent cardiac surgery. *Eur J Prev Cardiol.* 2020;27:593.

17. Sarno LA, Misra A, Siddeek H, et al. Cardiac rehabilitation for adults and adolescents with congenital heart disease: extending beyond the typical patient population. *J Cardiopulm Rehabil Prev.* 2020;40:e1-e4.

18. Knecht SK, Mays WA, Goessling JE, et al. Changes in cardiopulmonary fitness with facility and virtual cardiac rehabilitation in individuals with congenital heart disease. *J Cardiopulm Rehabil Prev.* 2023;43:e10.

19. Rice M, Mays WA, Knecht SK, et al. Estimated versus perceived estimates of metabolic equivalents in adult congenital heart disease patients before and after cardiac rehabilitation. *J Cardiopulm Rehabil Prev.* 2023;43:e14.

20. Amédéo P, Gavotto A, Huguet H, et al. Impact of a centre and home-based cardiac rehabilitation program on the quality of life of teenagers and young adults with congenital heart disease: The QUALIREHAB randomized controlled trial. *Arch Cardiovasc Dis.* 2024;117:S112.

21. Hooglugt J-LQ, van Dissel AC, Blok IM, et al. The effect of exercise training in symptomatic patients with grown-up congenital heart disease: a review. *Expert Rev Cardiovasc Ther.* 2018;16:379-386.

22. Kim JH, Baggish AL, Levine BD, et al. Clinical considerations for competitive sports participation for athletes with cardiovascular abnormalities: a scientific statement from the American Heart Association and American College of Cardiology. *J Am Coll Cardiol.* 2025;85(10):1059-1108.

23. Eser P, Gruber T, Marcin T, et al. Effect of exercise-based cardiac rehabilitation on cardiorespiratory fitness in adults with congenital heart disease. *Congenit Heart Dis.* 2021;16:73-84.

24. Budts W, Pieleas GE, Roos-Hesselink JW, et al. Recommendations for participation in competitive sport in adolescent and adult athletes with Congenital Heart Disease (CHD): position statement of the Sports Cardiology & Exercise Section of the European Association of Preventive Cardiology (EAPC), the European Society of Cardiology (ESC) Working Group on Adult Congenital Heart Disease and the Sports Cardiology, Physical Activity and Prevention Working Group of the Association for European Paediatric and Congenital Cardiology (AEPC). *Eur Heart J.* 2020;41:4191-4199.

#### 4.1. Shunt Lesions

1. Humbert M, Kovacs G, Hoepfer MM, et al. 2022 ESC/ERS guidelines for the diagnosis and treatment of pulmonary hypertension. *Eur Heart J.* 2022;43:3618-3731.

2. Pi H, Kosanovich CM, Handen A, et al. Outcomes of pulmonary arterial hypertension are improved in a specialty care center. *Chest*. 2020;158:330-340.
  3. Bradley EA, Ammash N, Martinez SC, et al. Treat-to-close: non-repairable ASD-PAH in the adult: results from the North American ASD-PAH (NAAP) multicenter registry. *Int J Cardiol*. 2019;291:127-133.
  4. Cool CJ, Kamarullah W, Pranata R, et al. A meta-analysis of atrial septal defect closure in patients with severe pulmonary hypertension: is there a room for poking holes amid debate? *Curr Probl Cardiol*. 2024;49:102121.
  5. He Y, Li Q, Zhang C, Gu H. 2. "Treat-close-treat" strategy in adult congenital heart disease related pulmonary arterial hypertension (ACHD-PAH). *Int J Cardiol Congenit Heart Dis*. 2021;2:100030.
  6. Takaya Y, Akagi T, Sakamoto I, et al. Efficacy of treat-and-repair strategy for atrial septal defect with pulmonary arterial hypertension. *Heart*. 2022;108:382-387.
  7. Kempny A, Hjortshøj CS, Gu H, et al. Predictors of death in contemporary adult patients with Eisenmenger Syndrome: a multicenter study. *Circulation*. 2017;135:1432-1440.
  8. Diller GP, Alonso-Gonzalez R, Kempny A, et al. B-type natriuretic peptide concentrations in contemporary Eisenmenger syndrome patients: predictive value and response to disease targeting therapy. *Heart*. 2012;98:736-742.
  9. Scognamiglio G, Kempny A, Price LC, et al. C-reactive protein in adults with pulmonary arterial hypertension associated with congenital heart disease and its prognostic value. *Heart*. 2014;100:1335-1341.
  10. Kempny A, Dimopoulos K, Alonso-Gonzalez R, et al. Six-minute walk test distance and resting oxygen saturations but not functional class predict outcome in adult patients with Eisenmenger syndrome. *Int J Cardiol*. 2013;168:4784-4789.
  11. Mocerri P, Dimopoulos K, Liodakis E, et al. Echocardiographic predictors of outcome in Eisenmenger syndrome. *Circulation*. 2012;126:1461-1468.
  12. Daliento L, Somerville J, Presbitero P, et al. Eisenmenger syndrome. Factors relating to deterioration and death. *Eur Heart J*. 1998;19:1845-1855.
  13. Dimopoulos K, Diller GP, Koltsida E, et al. Prevalence, predictors, and prognostic value of renal dysfunction in adults with congenital heart disease. *Circulation*. 2008;117:2320-2328.
  14. van Dissel AC, D'Alto M, Farro A, et al. Improved risk prediction using a refined European guidelines instrument in pulmonary arterial hypertension related to congenital heart disease. *Am J Cardiol*. 2024;223:28-34.
  15. Galie N, Beghetti M, Gatzoulis MA, et al. Bosentan therapy in patients with Eisenmenger syndrome: a multicenter, double-blind, randomized, placebo-controlled study. *Circulation*. 2006;114:48-54.
  16. Gatzoulis MA, Beghetti M, Galie N, et al. Long-term bosentan therapy improves functional capacity in Eisenmenger syndrome: results of the BREATHE-5 open-label extension study. *Int J Cardiol*. 2008;127:27-32.
  17. Gatzoulis MA, Landzberg M, Beghetti M, et al. Evaluation of macitentan in patients with Eisenmenger Syndrome. *Circulation*. 2019;139:51-63.
  18. Mukhopadhyay S, Nathani S, Yusuf J, et al. Clinical efficacy of phosphodiesterase-5 inhibitor tadalafil in Eisenmenger syndrome randomized, placebo-controlled, double-blind crossover study. *Congenit Heart Dis*. 2011;6:424-431.
  19. Cha KS, Cho KI, Seo JS, et al. Effects of inhaled iloprost on exercise capacity, quality of life, and cardiac function in patients with pulmonary arterial hypertension secondary to congenital heart disease (the Eisenmenger syndrome) (from the EIGER Study). *Am J Cardiol*. 2013;112:1834-1839.
  20. Nashat H, Kempny A, Harries C, et al. A single-centre, placebo-controlled, double-blind randomised cross-over study of nebulised iloprost in patients with Eisenmenger syndrome: a pilot study. *Int J Cardiol*. 2019;299:131-135.
  21. Chon MK, Cho KI, Cha KS, et al. Effects of long-term iloprost treatment on right ventricular function in patients with Eisenmenger syndrome. *J Cardiol*. 2017;69:741-746.
  22. Fernandes SM, Newburger JW, Lang P, et al. Usefulness of epoprostenol therapy in the severely ill adolescent/adult with Eisenmenger physiology. *Am J Cardiol*. 2003;91:632-635.
  23. D'Alto M, Constantine A, Balint OH, et al. The effects of parenteral prostacyclin therapy as add-on treatment to oral compounds in Eisenmenger syndrome. *Eur Respir J*. 2019;54:1901401.
  24. Galie N, Ghofrani HA, Torbicki A, et al. Sildenafil citrate therapy for pulmonary arterial hypertension. *N Engl J Med*. 2005;353:2148-2157.
  25. Galie N, Rubin L, Hoepfer M, et al. Treatment of patients with mildly symptomatic pulmonary arterial hypertension with bosentan (EARLY study): a double-blind, randomised controlled trial. *Lancet*. 2008;371:2093-2100.
  26. Simonneau G, Galie N, Jansa P, et al. Long-term results from the EARLY study of bosentan in WHO functional class II pulmonary arterial hypertension patients. *Int J Cardiol*. 2014;172:332-339.
  27. Pulido T, Adzerikho I, Channick RN, et al. Macitentan and morbidity and mortality in pulmonary arterial hypertension. *N Engl J Med*. 2013;369:809-818.
  28. Beghetti M, Channick RN, Chin KM, et al. Selexipag treatment for pulmonary arterial hypertension associated with congenital heart disease after defect correction: insights from the randomised controlled GRIPHON study. *Eur J Heart Fail*. 2019;21:352-359.
  29. Hoepfer MM, Badesch DB, Ghofrani HA, et al. Phase 3 trial of sotatercept for treatment of pulmonary arterial hypertension. *N Engl J Med*. 2023;388:1478-1490.
- #### 4.1.1. Atrial Septal Defect
1. Nordmeyer S, Berger F, Kuehne T, Riesenkampff E. Flow-sensitive four-dimensional magnetic resonance imaging facilitates and improves the accurate diagnosis of partial anomalous pulmonary venous drainage. *Cardiol Young*. 2011;21:528-535.
  2. Haramati LB, Moche IE, Rivera VT, et al. Computed tomography of partial anomalous pulmonary venous connection in adults. *J Comput Assist Tomogr*. 2003;27:743-749.
  3. Ammash NM, Seward JB, Warnes CA, et al. Partial anomalous pulmonary venous connection: diagnosis by transesophageal echocardiography. *J Am Coll Cardiol*. 1997;29:1351-1358.
  4. Pi H, Kosanovich CM, Handen A, et al. Outcomes of pulmonary arterial hypertension are improved in a specialty care center. *Chest*. 2020;158:330-340.
  5. Nakagawa K, Akagi T, Takaya Y, et al. Temporary balloon occlusion test can overestimate the risk of acute pulmonary edema after transcatheter atrial septal defect closure. *Catheter Cardiovasc Interv*. 2023;101:390-395.
  6. Miranda WR, Hagler DJ, Reeder GS, et al. Temporary balloon occlusion of atrial septal defects in suspected or documented left ventricular diastolic dysfunction: hemodynamic and clinical findings. *Catheter Cardiovasc Interv*. 2019;93:1069-1075.
  7. Attie F, Rosas M, Granados N, et al. Surgical treatment for secundum atrial septal defects in patients >40 years old. A randomized clinical trial. *J Am Coll Cardiol*. 2001;38:2035-2042.
  8. Baroutidou A, Arvanitaki A, Farmakis IT, et al. Transcatheter closure of atrial septal defect in the elderly: a systematic review and meta-analysis. *Heart*. 2023;109:1741-1750.
  9. Oster M, Ami BA, Zaragoza-Macias E, et al. Interventional therapy versus medical therapy for secundum atrial septal defect: a systematic review (Part 2) for the 2018 AHA/ACC guideline for the management of adults with congenital heart disease: a report of the American College of Cardiology/American Heart Association Task Force on Clinical Practice Guidelines. *Circulation*. 2019;139:e814-e830.
  10. Villablanca PA, Briston DA, Rodes-Cabau J, et al. Treatment options for the closure of secundum atrial septal defects: a systematic review and meta-analysis. *Int J Cardiol*. 2017;241:149-155.
  11. Bradley EA, Ammash N, Martinez SC, et al. "Treat-to-close": non-repairable ASD-PAH in the adult: results from the North American ASD-PAH (NAAP) multicenter registry. *Int J Cardiol*. 2019;291:127-133.
  12. Cool CJ, Kamarullah W, Pranata R, et al. A meta-analysis of atrial septal defect closure in patients with severe pulmonary hypertension: is there a room for poking holes amid debate? *Curr Probl Cardiol*. 2024;49:102121.
  13. Takaya Y, Akagi T, Sakamoto I, et al. Efficacy of treat-and-repair strategy for atrial septal defect with pulmonary arterial hypertension. *Heart*. 2022;108:382-387.
  14. Yan C, Pan X, Wan L, et al. Combination of F-ASO and targeted medical therapy in patients with secundum ASD and severe PAH. *JACC Cardiovasc Interv*. 2020;13:2024-2034.
  15. Cho YH, Jun T-G, Yang J-H, et al. Surgical strategy in patients with atrial septal defect and severe pulmonary hypertension. 2012:e111-e115.
  16. Sagar P, Sivakumar K, Thejaswi P, Rajendran M. Transcatheter covered stent exclusion of superior sinus venosus defects. *J Am Coll Cardiol*. 2024;83:2179-2192.
  17. Hansen JH, Duong P, Jivanji SGM, et al. Transcatheter correction of superior sinus venosus atrial septal defects as an alternative to surgical treatment. *J Am Coll Cardiol*. 2020;75:1266-1278.
  18. Rosenthal E, Qureshi SA, Sivakumar K, et al. Covered stent correction for sinus venosus atrial septal defects, an emerging alternative to surgical

repair: results of an international registry. *Circulation*. 2025;151:744-756.

19. El-Andari R, Moolla M, John K, et al. Outcomes following surgical repair of sinus venosus atrial septal defects: a systematic review and meta-analysis. *J Am Heart Assoc*. 2024;13:e033686.

20. Shohtsu A, Takeuchi S, Inoue T. Surgical indications and results for congenital cardiac anomalies associated with left to right shunt and severe pulmonary hypertension. *Jpn Circ J*. 1976;40:629-632.

21. Blackstone EH, Kirklin JW, Bradley EL, et al. Optimal age and results in repair of large ventricular septal defects. *J Thorac Cardiovasc Surg*. 1976;72:661-679.

22. Humbert M, Kovacs G, Hoepfer MM, et al. 2022 ESC/ERS guidelines for the diagnosis and treatment of pulmonary hypertension. *Eur Heart J*. 2022;43:3618-3731.

23. Klinger JR, Elliott CG, Levine DJ, et al. Therapy for pulmonary arterial hypertension in adults: update of the CHEST guideline and expert panel report. *Chest*. 2019;155:565-586.

24. Martin-Garcia AC, Dimopoulos K, Boutsikou M, et al. Tricuspid regurgitation severity after atrial septal defect closure or pulmonic valve replacement. *Heart*. 2020;106:455-461.

25. Rhoades R, Tzeng D, Ruggiero N. Secondary stroke prevention in patients with patent foramen ovale. *Curr Opin Hematol*. 2021;28:292-300.

26. He Y, Li Q, Zhang C, Gu H. 2. "Treat-close-treat" strategy in adult congenital heart disease related pulmonary arterial hypertension (ACHD-PAH). *Int J Cardiol Congenit Heart Dis*. 2021;2:100030.

27. Mahendran A, Alnuaimat H, Ataya A, et al. Hemodynamic and structural changes with late repair of atrial septal defects with pulmonary hypertension: case series on the "treat-to-close" strategy. *J Am Coll Cardiol*. 2021;77:2747.

28. Sivakumar K, Qureshi S, Pavithran S, et al. Simple diagnostic tools may guide transcatheter closure of superior sinus venosus defects without advanced imaging techniques. *Circ Cardiovasc Interv*. 2020;13:e009833.

29. Moolla M, El-Andari R, John K, et al. Outcomes of surgical repair for sinus venosus atrial septal defect. Conference abstract presented at: American Heart Association's 2023 Scientific Sessions and the American Heart Association's 2023 Resuscitation Science Symposium; 2023; Philadelphia, PA. <https://www.embase.com/search/results?subaction=viewrecord&id=L642976939&from=export>; [https://doi.org/10.1161/circ.148.suppl\\_1.13138](https://doi.org/10.1161/circ.148.suppl_1.13138)

30. Stout KK, Daniels CJ, Aboulhosn JA, et al. 2018 AHA/ACC guideline for the management of adults with congenital heart disease: a report of the American College of Cardiology/American Heart Association Task Force on Clinical Practice Guidelines. *J Am Coll Cardiol*. 2019;73:e81-e192.

#### 4.1.2. Ventricular Septal Defect

1. Dimopoulos K, Condliffe R, Tulloh RMR, et al. Echocardiographic screening for pulmonary hypertension in congenital heart disease: JACC review topic of the week. *J Am Coll Cardiol*. 2018;72:2778-2788.

2. D'Alto M, Romeo E, Argiento P, et al. Hemodynamics of patients developing pulmonary arterial

hypertension after shunt closure. *Int J Cardiol*. 2013;168:3797-3801.

3. Eckerström F, Nyboe C, Redington A, Hjortdal VE. Lifetime burden of morbidity in patients with isolated congenital ventricular septal defect. *J Am Heart Assoc*. 2023;12:e027477.

4. Kahr PC, Alonso-Gonzalez R, Kempny A, et al. Long-term natural history and postoperative outcome of double-chambered right ventricle-experience from two tertiary adult congenital heart centres and review of the literature. *Int J Cardiol*. 2014;174:662-668.

5. Miranda WR, Egbe AC, Hagler DJ, Connolly HM. Double-chambered right ventricle in adults: invasive and noninvasive hemodynamic considerations. *Int J Cardiol Congenit Heart Dis*. 2021;3:100115.

6. Karonis T, Scognamiglio G, Babu-Narayan SV, et al. Clinical course and potential complications of small ventricular septal defects in adulthood: late development of left ventricular dysfunction justifies lifelong care. *Int J Cardiol*. 2016;208:102-106.

7. Pi H, Kosanovich CM, Handen A, et al. Outcomes of pulmonary arterial hypertension are improved in a specialty care center. *Chest*. 2020;158:330-340.

8. Bambul Heck P, Eicken A, Kasnar-Samprec J, et al. Early pulmonary arterial hypertension immediately after closure of a ventricular or complete atrioventricular septal defect beyond 6 months of age. *Int J Cardiol*. 2017;228:313-318.

9. Lee SY, Kim SJ, Son JS, et al. Stepwise approach using combined management in patients with congenital heart disease and borderline pulmonary vascular disease. *Korean Circ J*. 2015;45:408-415.

10. Lowe BS, Therrien J, Ionescu-Iltu R, et al. Diagnosis of pulmonary hypertension in the congenital heart disease adult population impact on outcomes. *J Am Coll Cardiol*. 2011;58:538-546.

11. Alonso-Gonzalez R, Lopez-Guarch CJ, Subirana-Domenech MT, et al. Pulmonary hypertension and congenital heart disease: an insight from the REHAP national registry. *Int J Cardiol*. 2015;184:717-723.

12. Menting ME, Cuypers JA, Opic P, et al. The unnatural history of the ventricular septal defect: outcome up to 40 years after surgical closure. *J Am Coll Cardiol*. 2015;65:1941-1951.

13. Balzer DT, Kort HW, Day RW, et al. Inhaled Nitric Oxide as a Preoperative Test (INOP Test I): the INOP Test Study Group. *Circulation*. 2002;106(12 Suppl 1):I76-I81.

14. Hosseinpour AR, Perez MH, Longchamp D, et al. Age is not a good predictor of irreversibility of pulmonary hypertension in congenital cardiac malformations with left-to-right shunt. *Congenit Heart Dis*. 2018;13:210-216.

15. Cho MS, Jang SJ, Sun BJ, et al. Prognostic implications of initial echocardiographic findings in adolescents and adults with supracardiac ventricular septal defects. *J Am Soc Echocardiogr*. 2014;27:965-971.

16. Lim JH, Cho S, Lee CH, et al. Long-term outcomes of surgical repair for ventricular septal defect in adults. *Pediatr Cardiol*. 2022;43:1277-1285.

17. Jung H, Cho JY, Lee Y. Progression of aortic regurgitation after subarterial ventricular septal defect repair: optimal timing of the operation. *Pediatr Cardiol*. 2019;40:1696-1702.

18. Butter A, Duncan W, Weatherdon D, et al. Aortic cusp prolapse in ventricular septal defect and its

association with aortic regurgitation-appropriate timing of surgical repair and outcomes. *Can J Cardiol*. 1998;14:833-840.

19. Berglund E, Johansson B, Dellborg M, et al. High incidence of infective endocarditis in adults with congenital ventricular septal defect. *Heart*. 2016;102:1835-1839.

20. Mongeon FP, Burkhart HM, Ammass NM, et al. Indications and outcomes of surgical closure of ventricular septal defect in adults. *JACC Cardiovasc Interv*. 2010;3:290-297.

21. Talwar S, Keshri VK, Choudhary SK, et al. Unidirectional valved patch closure of ventricular septal defects with severe pulmonary arterial hypertension: hemodynamic outcomes. *J Thorac Cardiovasc Surg*. 2014;148:2570-2575.

22. Akagi S, Kasahara S, Sarashina T, et al. Treat-and-repair strategy is a feasible therapeutic choice in adult patients with severe pulmonary arterial hypertension associated with a ventricular septal defect: case series. *Eur Heart J Case Rep*. 2018;2: yty033.

23. Akagi S, Kasahara S, Akagi T, et al. Feasibility of treat and repair strategy in congenital heart defects with pulmonary arterial hypertension. *JACC Adv*. 2024;3:100887.

24. Eckerström F, Nyboe C, Maagaard M, et al. Survival of patients with congenital ventricular septal defect. *Eur Heart J*. 2023;44:54-61.

25. Manes A, Palazzini M, Leci E, et al. Current era survival of patients with pulmonary arterial hypertension associated with congenital heart disease: a comparison between clinical subgroups. *Eur Heart J*. 2014;35:716-724.

26. Frescura C, Thiene G, Giulia Gagliardi M, et al. Is lung biopsy useful for surgical decision making in congenital heart disease? *Eur J Cardiothorac Surg*. 1991;5:118-122. discussion 122-123.

27. Moller JH, Patton C, Varco RL, Lillehei CW. Late results (30 to 35 years) after operative closure of isolated ventricular septal defect from 1954 to 1960. *Am J Cardiol*. 1991;68:1491-1497.

28. Meijboom F, Szatmari A, Utens E, et al. Long-term follow-up after surgical closure of ventricular septal defect in infancy and childhood. *J Am Coll Cardiol*. 1994;24:1358-1364.

29. Kidd L, Driscoll DJ, Gersony WM, et al. Second natural history study of congenital heart defects. Results of treatment of patients with ventricular septal defects. *Circulation*. 1993;87:138-151.

30. Saurav A, Kaushik M, Mahesh Alla V, et al. Comparison of percutaneous device closure versus surgical closure of peri-membranous ventricular septal defects: a systematic review and meta-analysis. *Catheter Cardiovasc Interv*. 2015;86:1048-1056.

31. Chen Q, Hong ZN, Zhang GC, et al. Intraoperative device closure of isolated ventricular septal defects: experience on 1,090 Cases. *Ann Thorac Surg*. 2018;105:1797-1802.

32. Mattila S, Kostianen S, Kyllonen KE, Tala P. Repair of ventricular septal defect in adults. *Scand J Thorac Cardiovasc Surg*. 1985;19:29-31.

33. Santhanam H, Yang L, Chen Z, et al. A meta-analysis of transcatheter device closure of perimembranous ventricular septal defect. *Int J Cardiol*. 2018;254:75-83.

34. Beghetti M, Channick RN, Chin KM, et al. Selexipag treatment for pulmonary arterial hypertension associated with congenital heart disease after defect correction: insights from the randomised controlled GRIPHON study. *Eur J Heart Fail*. 2019;21:352-359.
35. Pulido T, Azderkhu I, Channick RN, et al. Macitentan and morbidity and mortality in pulmonary arterial hypertension. *N Engl J Med*. 2013;369:809-818.
36. Lee PT, Uy FM, Foo JS, Tan JL. Increased incidence of infective endocarditis in patients with ventricular septal defect. *Congenit Heart Dis*. 2018;13:1005-1011.
37. Baddour LM, Wilson WR, Bayer AS, et al. Infective endocarditis in adults: diagnosis, antimicrobial therapy, and management of complications: a scientific statement for healthcare professionals from the American Heart Association. *Circulation*. 2015;132:1435-1486.
38. Wilson W, Taubert KA, Gewitz M, et al. Prevention of infective endocarditis: guidelines from the American Heart Association: a Guideline from the American Heart Association Rheumatic Fever, Endocarditis, and Kawasaki Disease Committee, Council on Cardiovascular Disease in the Young, and the Council on Clinical Cardiology, Council on Cardiovascular Surgery and Anesthesia, and the Quality of Care and Outcomes Research Interdisciplinary Working Group. *Circulation*. 2007;116:1736-1754.
39. Habib G, Lancellotti P, Antunes MJ, et al. 2015 ESC guidelines for the management of infective endocarditis: the Task Force for the Management of Infective Endocarditis of the European Society of Cardiology (ESC). *Eur Heart J*. 2015;36:3075-3128.
40. Wang Z, Li X, Li M, et al. The efficacy of the treat-repair-treat strategy for severe pulmonary arterial hypertension associated with congenital heart disease: a meta-analysis. *BMC Cardiovasc Disord*. 2023;23:569.
41. Hu Z, Xie B, Zhai X, et al. Midterm results of "treat and repair" for adults with non-restrictive ventricular septal defect and severe pulmonary hypertension. *J Thorac Dis*. 2015;7:1165-1173.
42. Li Q, Zhang C, Wang R, et al. Pulmonary hypertensive crisis in children with pulmonary arterial hypertension undergoing cardiac catheterization. *Pulm Circ*. 2022;12:e12067.
43. Golovenko O, Lazorhshynets V, Prokopovych L, et al. Early and long-term results of ventricular septal defect repair in children with severe pulmonary hypertension and elevated pulmonary vascular resistance by the double or traditional patch technique. *Eur J Cardiothorac Surg*. 2022;62:eza347.
44. Afrasiabirad A, Samadi M, Vatani P, Faridvand Y. Valve patch technique for repair of ventricular septal defect: long-term results. *Asian Cardiovasc Thorac Ann*. 2021;29:161-164.
45. Patel R, Thingnam SKS, Mishra AK, et al. Benefits of perioperative sildenafil therapy in children with a ventricular septal defect with pulmonary artery hypertension on early surgical outcomes. *J Card Surg*. 2020;35:3302-3309.
46. Sharma VK, Joshi S, Joshi A, et al. Does intravenous sildenafil clinically ameliorate pulmonary hypertension during perioperative management of congenital heart diseases in children?—a prospective randomized study. *Ann Card Anaesth*. 2015;18:510-516.
47. Price LC, Martinez G, Brame A, et al. Perioperative management of patients with pulmonary hypertension undergoing non-cardiothoracic, non-obstetric surgery: a systematic review and expert consensus statement. *Br J Anaesth*. 2021;126:774-790.
48. Stout KK, Daniels CJ, Aboulhosn JA, et al. 2018 AHA/ACC guideline for the management of adults with congenital heart disease: a report of the American College of Cardiology/American Heart Association Task Force on Clinical Practice Guidelines. *J Am Coll Cardiol*. 2019;73:e81-e192.
- #### 4.1.3. Atrioventricular Septal Defect
1. Bambul Heck P, Eicken A, Kasnar-Samprec J, et al. Early pulmonary arterial hypertension immediately after closure of a ventricular or complete atrioventricular septal defect beyond 6 months of age. *Int J Cardiol*. 2017;228:313-318.
2. Lowe BS, Therrien J, Ionescu-Iltu R, et al. Diagnosis of pulmonary hypertension in the congenital heart disease adult population impact on outcomes. *J Am Coll Cardiol*. 2011;58:538-546.
3. Pi H, Kosanovich CM, Handen A, et al. Outcomes of pulmonary arterial hypertension are improved in a specialty care center. *Chest*. 2020;158:330-340.
4. Fong LS, Betts K, Bell D, et al. Complete atrioventricular septal defect repair in Australia: results over 25 years. *J Thorac Cardiovasc Surg*. 2020;159:1014-1025.e8.
5. Ivanov Y, Buratto E, Naimo P, et al. Incidence and management of the left ventricular outflow obstruction in patients with atrioventricular septal defects. *Interact Cardiovasc Thorac Surg*. 2022;34:604-610.
6. Mery CM, Zea-Vera R, Chacon-Portillo MA, et al. Contemporary results after repair of partial and transitional atrioventricular septal defects. *J Thorac Cardiovasc Surg*. 2019;157:1117-1127.e4.
7. Karamlou T, Diggs BS, Person T, et al. National practice patterns for management of adult congenital heart disease: operation by pediatric heart surgeons decreases in-hospital death. *Circulation*. 2008;118:2345-2352.
8. Buratto E, McCrossan B, Galati JC, et al. Repair of partial atrioventricular septal defect: a 37-year experience. *Eur J Cardiothorac Surg*. 2015;47:796-802.
9. Stulak JM, Burkhart HM, Dearani JA, et al. Reoperations after repair of partial atrioventricular septal defect: a 45-year single-center experience. *Ann Thorac Surg*. 2010;89:1352-1359.
10. Moller JH, Patton C, Varco RL, Lillehei CW. Late results (30 to 35 years) after operative closure of isolated ventricular septal defect from 1954 to 1960. *Am J Cardiol*. 1991;68:1491-1497.
11. Balzer DT, Kort HW, Day RW, et al. Inhaled Nitric Oxide as a Preoperative Test (INOP Test I): the INOP Test Study Group. *Circulation*. 2002;106(12 Suppl 1):I76-I81.
12. Ho DY, Katcoff H, Griffis HM, et al. Left valvar morphology is associated with late regurgitation in atrioventricular canal defect. *Ann Thorac Surg*. 2020;110:969-978.
13. Piccoli GP, Ho SY, Wilkinson JL, et al. Left-sided obstructive lesions in atrioventricular septal defects: an anatomic study. *J Thorac Cardiovasc Surg*. 1982;83:453-460.
14. Borkon AM, Pieroni DR, Varghese PJ, et al. The superior QRS axis in ostium primum ASD: a proposed mechanism. *Am Heart J*. 1975;90:215-221.
15. Liberman L, Pass RH, Hordof AJ, Spotnitz HM. Late onset of heart block after open heart surgery for congenital heart disease. *Pediatr Cardiol*. 2008;29:56-59.
16. Dimopoulos K, Condliffe R, Tulloh RMR, et al. Echocardiographic screening for pulmonary hypertension in congenital heart disease: JACC review topic of the week. *J Am Coll Cardiol*. 2018;72:2778-2788.
17. Humbert M, Kovacs G, Hoeper MM, et al. 2022 ESC/ERS guidelines for the diagnosis and treatment of pulmonary hypertension. *Eur Heart J*. 2022;43:3618-3731.
18. Otto CM, Nishimura RA, Bonow RO, et al. 2020 ACC/AHA guideline for the management of patients with valvular heart disease: a report of the American College of Cardiology/American Heart Association Joint Committee on Clinical Practice Guidelines. *J Am Coll Cardiol*. 2021;77:e25-e197.
19. Nathan M, Levine JC, Van Rompay MI, et al. Impact of major residual lesions on outcomes after surgery for congenital heart disease. *J Am Coll Cardiol*. 2021;77:2382-2394.
20. Jone PN, Ivy DD, Hauck A, et al. Pulmonary hypertension in congenital heart disease: a scientific statement from the American Heart Association. *Circ Heart Fail*. 2023;16:e00080.
21. Stout KK, Daniels CJ, Aboulhosn JA, et al. 2018 AHA/ACC guideline for the management of adults with congenital heart disease: a report of the American College of Cardiology/American Heart Association Task Force on Clinical Practice Guidelines. *J Am Coll Cardiol*. 2019;73:e81-e192.
- #### 4.1.4. Anomalous Pulmonary Venous Connections
1. Festa P, Ait-Ali L, Cerillo AG, et al. Magnetic resonance imaging is the diagnostic tool of choice in the preoperative evaluation of patients with partial anomalous pulmonary venous return. *Int J Cardiovasc Imaging*. 2006;22:685-693.
2. Nordmeyer S, Berger F, Kuehne T, Riesenkaempff E. Flow-sensitive four-dimensional magnetic resonance imaging facilitates and improves the accurate diagnosis of partial anomalous pulmonary venous drainage. *Cardiol Young*. 2011;21:528-535.
3. Dyme JL, Prakash A, Printz BF, et al. Physiology of isolated anomalous pulmonary venous connection of a single pulmonary vein as determined by cardiac magnetic resonance imaging. *Am J Cardiol*. 2006;98:107-110.
4. Hatipoglu S, Almogheer B, Mahon C, et al. Clinical significance of partial anomalous pulmonary venous connections (isolated and atrial septal defect associated) determined by cardiovascular magnetic resonance. *Circ Cardiovasc Imaging*. 2021;14:e012371.
5. Sachweh JS, Daebritz SH, Hermanns B, et al. Hypertensive pulmonary vascular disease in adults with secundum or sinus venosus atrial septal defect. *Ann Thorac Surg*. 2006;81:207-213.
6. Majdalany DS, Phillips SD, Dearani JA, et al. Isolated partial anomalous pulmonary venous

connections in adults: twenty-year experience. *Congenit Heart Dis*. 2010;5:537-545.

7. Shah AH, Oechslin E, Benson L, et al. Long-term outcomes of unrepaired isolated partial anomalous pulmonary venous connection with an intact atrial septum. *Am J Cardiol*. 2023;201:232-238.

8. Lewis RA, Billings CG, Bolger A, et al. Partial anomalous pulmonary venous drainage in patients presenting with suspected pulmonary hypertension: a series of 90 patients from the ASPIRE registry. *Respiology*. 2020;25:1066-1072.

9. Zubritskiy A, Naberukhin Y, Arkhipov A, et al. Outcomes of double-patch and warden techniques in patients with supracardiac partial anomalous pulmonary venous connection. *Heart Lung Circ*. 2020;29:156-161.

10. Dusenbery SM, Geva T, Seale A, et al. Outcome predictors and implications for management of scimitar syndrome. *Am Heart J*. 2013;165:770-777.

11. Brink J, Yong MS, d'Udekem Y, et al. Surgery for scimitar syndrome: the Melbourne experience. *Interact Cardiovasc Thorac Surg*. 2015;20:31-34.

12. Alsoufi B, Cai S, Van Arsdell GS, et al. Outcomes after surgical treatment of children with partial anomalous pulmonary venous connection. *Ann Thorac Surg*. 2007;84:2020-2026. discussion 2020-2026.

13. Warden HE, Gustafson RA, Tarnay TJ, Neal WA. An alternative method for repair of partial anomalous pulmonary venous connection to the superior vena cava. *Ann Thorac Surg*. 1984;38:601-605.

#### 4.1.5. Patent Ductus Arteriosus

1. Pi H, Kosanovich CM, Handen A, et al. Outcomes of pulmonary arterial hypertension are improved in a specialty care center. *Chest*. 2020;158:330-340.

2. Zhang DZ, Zhu XY, Lv B, et al. Trial occlusion to assess the risk of persistent pulmonary arterial hypertension after closure of a large patent ductus arteriosus in adolescents and adults with elevated pulmonary artery pressure. *Circ Cardiovasc Interv*. 2014;7:473-481.

3. Jeong YH, Yun TJ, Song JM, et al. Left ventricular remodeling and change of systolic function after closure of patent ductus arteriosus in adults: device and surgical closure. *Am Heart J*. 2007;154:436-440.

4. Khajali Z, Firouzi A, Shakerian F, et al. Cardiac reverse remodeling after transcatheter patent ductus arteriosus closure in adults. *Curr Probl Cardiol*. 2022;47(10):100938.

5. Wilson WM, Shah A, Osten MD, et al. Clinical outcomes after percutaneous patent ductus arteriosus closure in adults. *Can J Cardiol*. 2020;36:837-843.

6. Yan C, Zhao S, Jiang S, et al. Transcatheter closure of patent ductus arteriosus with severe pulmonary arterial hypertension in adults. *Heart*. 2007;93:514-518.

7. Zabal-Cerdeira C. [Transcatheter versus surgical closure of atrial septal defect and patent ductus arteriosus in adults]. *Rev Esp Cardiol*. 2009;62(Suppl 2):23-28.

8. Sadiq M, Rehman AU, Hyder N, et al. Intermediate- and long-term follow-up of device closure of patent arterial duct with severe pulmonary hypertension: factors predicting outcome. *Cardiol Young*. 2017;27:26-36.

9. Dimopoulos K, Peset A, Gatzoulis MA. Evaluating operability in adults with congenital heart disease and the role of pretreatment with targeted pulmonary arterial hypertension therapy. *J*. 2008;129:163-171.

10. Schneider DJ, Moore JW. Patent ductus arteriosus. *Circulation*. 2006;114:1873-1882.

11. Yamaki S, Mohri H, Haneda K, et al. Indications for surgery based on lung biopsy in cases of ventricular septal defect and/or patent ductus arteriosus with severe pulmonary hypertension. *Chest*. 1989;96:31-39.

12. Pushparajah K, Tzifa A, Bell A, et al. Cardiovascular magnetic resonance catheterization derived pulmonary vascular resistance and medium-term outcomes in congenital heart disease. *J Cardiovasc Magn Reson*. 2015;17:28.

13. Chen PY, Luo DL, Li HZ, et al. Prediction value of pulmonary hypertension in newly identified left ventricular dysfunction among adult patients after patent ductus arteriosus closure. *Pulm Circ*. 2019;9:2045894019888428.

14. Kuntz MT, Staffa SJ, Graham D, et al. Trend and outcomes for surgical versus transcatheter patent ductus arteriosus closure in neonates and infants at US children's hospitals. *J Am Heart Assoc*. 2022;11:1-10.

15. Stout KK, Daniels CJ, Aboulhosn JA, et al. 2018 ACC/AHA guideline for the management of adults with congenital heart disease: a report of the American College of Cardiology/American Heart Association Task Force on Clinical Practice Guidelines. *J Am Coll Cardiol*. 2019;73:e81-e192.

#### 4.2.1. Cor Triatriatum Sinister

1. Fuchs MM, Connolly HM, Said SM, Egbe AC. Outcomes in patients with cor triatriatum sinister. *Congenit Heart Dis*. 2018;13:628-632.

2. Saxena P, Burkhart HM, Schaff HV, et al. Surgical repair of cor triatriatum sinister: the Mayo Clinic 50-year experience. *Ann Thorac Surg*. 2014;97:1659-1663.

3. Yaroglu Kazanci S, Emami S, McElhinney DB. Outcome after repair of cor triatriatum. *Am J Cardiol*. 2012;109:412-416.

4. Ozyuksel A, Yildirim O, Avsar M, et al. Surgical correction of cor triatriatum sinister in the paediatric population: mid-term results in 15 cases. *Eur J Cardiothorac Surg*. 2015;47:e25-e28.

5. Sankhyan LK, Anderson RH, Chowdhury UK, et al. Surgical management of divided atrial chambers. *J Card Surg*. 2021;36:4267-4279.

6. Amara RS, Lalla R, Jeudy J, Hong SN. Cardioembolic stroke in a young male with cor triatriatum sinister: a case report. *Eur Heart J Case Rep*. 2020;4:1-6.

7. Arzhangzade A, Zamirian M, Nozhat S, et al. Clinical case of cor triatriatum sinister, a dilemma of anticoagulation: a case report and literature review. *Clin Case Rep*. 2024;12:e8908.

8. Rudienė V, Hjortshøj CMS, Glavekaitė S, et al. Cor triatriatum sinistrum diagnosed in the adulthood: a systematic review. *Heart*. 2019;105:1197-1202.

9. Talner CN. Report of the New England Regional Infant Cardiac Program, by Donald C. Fyler, MD, pediatric, 1980;65(suppl):375-461. *Pediatrics*. 1998;102:258-259.

10. Modi KA, Annamali S, Ernest K, Pratej CR. Diagnosis and surgical correction of cor triatriatum in an adult: combined use of transesophageal and contrast echocardiography, and a review of literature. *Echocardiography*. 2006;23:506-509.

11. Humpl T, Reineker K, Manlhiot C, et al. Cor triatriatum sinistrum in childhood. A single institution's experience. *Can J Cardiol*. 2010;26:371-376.

12. Goel A, Viswamitra S, Reddy BN, Gaduputi J. Computed tomography features of cor triatriatum: an institutional review. *Br J Radiol*. 2021;94:20201252.

13. Nakajima H, Kobayashi J, Kurita T, Kitamura S. Maze procedure and cor triatriatum repair. *Ann Thorac Surg*. 2002;74:251-253.

14. Knox A, Gimpel D, Joseph M, Crouch G. 3D echocardiographic guided surgical repair for very late presentation of cor triatriatum. *ANZ J Surg*. 2023;93:2537-2538.

15. Beller B, Childers R, Eckner F, et al. Cor triatriatum in the adult. Complicated by mitral insufficiency and aortic dissection. *Am J Cardiol*. 1967;19:749-754.

16. Kumar V, Singh RS, Mishra AK, Thingnam SKS. Surgical experience with cor triatriatum repair beyond infancy. *J Card Surg*. 2019;34:1445-1451.

17. Siniorakis E, Arvanitakis S, Pantelis N, et al. Left atrium in cor triatriatum: arrhythmogenesis and thrombogenesis leading to stroke. *Int J Cardiol*. 2013;168:4503-4504.

18. Otto CM, Nishimura RA, Bonow RO, et al. 2020 ACC/AHA guideline for the management of patients with valvular heart disease: a report of the American College of Cardiology/American Heart Association Joint Committee on Clinical Practice Guidelines. *J Am Coll Cardiol*. 2021;77:e25-e197.

19. Slight RD, Nzewi OC, Buell R, Mankad PS. Cor triatriatum sinister presenting in the adult as mitral stenosis: an analysis of factors which may be relevant in late presentation. *Heart Lung Circ*. 2005;14:8-12.

20. Connolly SJ, Karthikeyan G, Ntsckhe M, et al. Rivaroxaban in rheumatic heart disease-associated atrial fibrillation. *N Engl J Med*. 2022;387:978-988.

21. Vick GW 3rd, Murphy DJ Jr, Ludomirsky A, et al. Pulmonary venous and systemic ventricular inflow obstruction in patients with congenital heart disease: detection by combined two-dimensional and Doppler echocardiography. *J Am Coll Cardiol*. 1987;9:580-587.

22. Feld H, Shani J, Rudansky HW, et al. Initial presentation of cor triatriatum in a 55-year-old woman. *Am Heart J*. 1992;124:788-791.

23. Griffiths JR, Nussinovitch U, Liang JJ, et al. Catheter ablation for atrial fibrillation in adult congenital heart disease: an international multicenter registry study. *Circ Arrhythm Electrophysiol*. 2022;15:e010954.

24. Kerkar P, Vora A, Kulkarni H, et al. Percutaneous balloon dilatation of cor triatriatum sinister. *Am Heart J*. 1996;132:888-891.

25. Huang TC, Lee CL, Lin CC, et al. Use of Inoue balloon dilatation method for treatment of cor triatriatum stenosis in a child. *Catheter Cardiovasc Interv*. 2002;57:252-256.

26. Sivakumar K, Satish R, Tailor K, Coelho R. Transcatheter management of subtotal cor triatriatum sinister: a rare anomaly. *Pediatr Cardiol*. 2008;29:812-815.

27. Schiller O, Burns KM, Sinha P, Cummings SD. Cor triatriatum with partial anomalous pulmonary venous return: a rare case of parallel obstruction and successful staged treatment. *Pediatr Cardiol.* 2012;33:363-365.

28. Mendez AB, Colchero T, Garcia-Picart J, et al. Unusual case of new-onset heart failure due to cor triatriatum sinister. *Eur J Heart Fail.* 2013;15:237-239.

29. Patel MB, Samuel BP, Berjaoui WK, et al. Transcatheter intervention in cor triatriatum sinister. *Can J Cardiol.* 2015;31:819.e3-819.e4.

30. Khoury M, Sandoval JP, Grosse-Wortmann L, et al. Catheter-based palliation in an infant with obstructed cor triatriatum. *Can J Cardiol.* 2016;32:1575.

31. Blais BA, Aboulhosn JA, Salem MM, Levi DS. Successful radiofrequency perforation and balloon decompression of cor triatriatum sinister using novel technique, a case series. *Catheter Cardiovasc Interv.* 2021;98:810-814.

32. Tuan SH, Chen GB, Chen CH, et al. Serial cardiopulmonary exercise testing in an asymptomatic young female receiving percutaneous balloon dilatation for cor triatriatum sinistrum at an early age. *J Formos Med Assoc.* 2021;120:1143-1147.

33. Thorin D, Aebischer N, Landolt J, et al. Acute pulmonary edema in the post partum and cor triatriatum sinistrum. *Int J Obstet Anesth.* 1995;4:113-116.

34. LeClair SJ, Funk KJ, Goff DR. Cor triatriatum presenting as postcesarean section pulmonary edema. *J Cardiothorac Vasc Anesth.* 1996;10:638-639.

35. Sentilhes L, Verspyck E, Bauer F, Marpeau L. Management of maternal cor triatriatum during pregnancy. *Obstet Gynecol.* 2004;104:1212-1215.

36. Davlouros PA, Koutsogiannis N, Karatza A, Alexopoulos D. An unusual case of cor triatriatum sinister presenting as pulmonary oedema during labor. *Int J Cardiol.* 2011;150:e92-e93.

37. Bai W, Kaushal S, Malviya S, et al. Anesthetic management for resection of cor triatriatum during the second trimester of pregnancy. *Int J Obstet Anesth.* 2010;19:103-106.

38. Pomini F, Mercogliano D, Cavalletti C, et al. Cardiopulmonary bypass in pregnancy. *Ann Thorac Surg.* 1996;61:259-268.

#### 4.2.2. Congenital Mitral Stenosis, Including Shone Complex

1. Schaverien MV, Freedom RM, McCrindle BW. Independent factors associated with outcomes of parachute mitral valve in 84 patients. *Circulation.* 2004;109:2309-2313.

2. Marino BS, Kruge LE, Cho CJ, et al. Parachute mitral valve: morphologic descriptors, associated lesions, and outcomes after biventricular repair. *J Thorac Cardiovasc Surg.* 2009;137:385-393.e4.

3. Jain CC, Warnes CA, Egbe AC, et al. Hemodynamics in adults with the Shone Complex. *Am J Cardiol.* 2020;130:137-142.

4. Tucker DL, Gupta S, Pande A, et al. Mitral valve intervention, pulmonary hypertension, and survival in 219 Shone's syndrome patients. *Ann Thorac Surg.* 2024;118:189-198.

5. Otto CM, Nishimura RA, Bonow RO, et al. 2020 ACC/AHA guideline for the management of patients with valvular heart disease: a report of the American

College of Cardiology/American Heart Association Joint Committee on Clinical Practice Guidelines. *J Am Coll Cardiol.* 2021;77:e25-e197.

6. Stout KK, Daniels CJ, Aboulhosn JA, et al. 2018 AHA/ACC guideline for the management of adults with congenital heart disease: a report of the American College of Cardiology/American Heart Association Task Force on Clinical Practice Guidelines. *J Am Coll Cardiol.* 2019;73:e81-e192.

#### 4.2.3. Subaortic Stenosis

1. van der Linde D, Takkenberg JJ, Rizopoulos D, et al. Natural history of discrete subaortic stenosis in adults: a multicentre study. *Eur Heart J.* 2013;34:1548-1556.

2. van der Linde D, Roos-Hesselink JW, Rizopoulos D, et al. Surgical outcome of discrete subaortic stenosis in adults: a multicenter study. *Circulation.* 2013;127:1184-1191.

3. Writing Committee M, Ommen SR, Ho CY, et al. 2024 AHA/ACC/AMSSM/HRS/PACES/SCMR guideline for the management of hypertrophic cardiomyopathy: a report of the American Heart Association/American College of Cardiology Joint Committee on Clinical Practice Guidelines. *J Am Coll Cardiol.* 2024;83:2324-2405.

4. Pickard SS, Geva A, Gauvreau K, et al. Long-term outcomes and risk factors for aortic regurgitation after discrete subvalvular aortic stenosis resection in children. *Heart.* 2015;101:1547-1553.

5. Karamlou T, Gurofsky R, Bojcevski A, et al. Prevalence and associated risk factors for intervention in 313 children with subaortic stenosis. *Ann Thorac Surg.* 2007;84:900-906. discussion 906.

6. McMahon CJ, Gauvreau K, Edwards JC, Geva T. Risk factors for aortic valve dysfunction in children with discrete subvalvar aortic stenosis. *Am J Cardiol.* 2004;94:459-464.

7. Brauner R, Laks H, Drinkwater DC Jr, et al. Benefits of early surgical repair in fixed subaortic stenosis. *J Am Coll Cardiol.* 1997;30:1835-1842.

8. Otto CM, Nishimura RA, Bonow RO, et al. 2020 ACC/AHA guideline for the management of patients with valvular heart disease: a report of the American College of Cardiology/American Heart Association Joint Committee on Clinical Practice Guidelines. *J Am Coll Cardiol.* 2021;77:e25-e197.

9. Das P, Rimington H, Chambers J. Exercise testing to stratify risk in aortic stenosis. *Eur Heart J.* 2005;26:1309-1313.

10. Stout KK, Daniels CJ, Aboulhosn JA, et al. 2018 AHA/ACC guideline for the management of adults with congenital heart disease: a report of the American College of Cardiology/American Heart Association Task Force on Clinical Practice Guidelines. *J Am Coll Cardiol.* 2019;73:e81-e192.

#### 4.2.4. Congenital Diseases of the Aortic Valve

1. Szöcs K, Toprak B, Schön G, et al. Concomitant cardiovascular malformations in isolated bicuspid aortic valve disease: a retrospective cross-sectional study and meta-analysis. *Cardiovasc Diagn Ther.* 2022;12:400-414.

2. Masri A, Kalahasti V, Alkharabsheh S, et al. Characteristics and long-term outcomes of contemporary

patients with bicuspid aortic valves. *J Thorac Cardiovasc Surg.* 2016;151:1650-1659.e1.

3. Kong WK, Regeer MV, Ng AC, et al. Sex differences in phenotypes of bicuspid aortic valve and aortopathy: insights from a large multicenter, international registry. *Circ Cardiovasc Imaging.* 2017;10:e005155.

4. Davies RR, Kaple RK, Mandapati D, et al. Natural history of ascending aortic aneurysms in the setting of an unreplaced bicuspid aortic valve. *Ann Thorac Surg.* 2007;83:1338-1344.

5. McKellar SH, Michelena HI, Li Z, et al. Long-term risk of aortic events following aortic valve replacement in patients with bicuspid aortic valves. *Am J Cardiol.* 2010;106:1626-1633.

6. Girdauskas E, Disha K, Borger MA, Kuntze T. Long-term prognosis of ascending aortic aneurysm after aortic valve replacement for bicuspid versus tricuspid aortic valve stenosis. *J Thorac Cardiovasc Surg.* 2014;147:276-282.

7. Cheng C, Bohbot Y, Michelena HI, et al. Clinical outcomes of adults with bicuspid aortic valve: a European perspective. *Mayo Clin Proc.* 2021;96:648-657.

8. Bray JJH, Freer R, Pitcher A, Kharbanda R. Family screening for bicuspid aortic valve and aortic dilatation: a meta-analysis. *Eur Heart J.* 2023;44:3152-3164.

9. Glotzbach JP, Hanson HA, Tonna JE, et al. Familial associations of prevalence and cause-specific mortality for thoracic aortic disease and bicuspid aortic valve in a large-population database. *Circulation.* 2023;148:637-647.

10. Albornoz G, Coady MA, Roberts M, et al. Familial thoracic aortic aneurysms and dissections: incidence, modes of inheritance, and phenotypic patterns. *Ann Thorac Surg.* 2006;82:1400-1405.

11. Etnel JRG, Helbing WA, Roos-Hesselink JW, et al. Patient and physician view on patient information and decision-making in congenital aortic and pulmonary valve surgery. *Open Heart.* 2018;5:e000872.

12. Korteland NM, Ahmed Y, Koolbergen DR, et al. Does the use of a decision aid improve decision making in prosthetic heart valve selection? A multicenter randomized trial. *Circ Cardiovasc Qual Outcomes.* 2017;10:e003178.

13. Coylewright M, Palmer R, O'Neill ES, et al. Patient-defined goals for the treatment of severe aortic stenosis: a qualitative analysis. *Health Expect.* 2016;19:1036-1043.

14. Rosenfeld HM, Landzberg MJ, Perry SB, et al. Balloon aortic valvuloplasty in the young adult with congenital aortic stenosis. *Am J Cardiol.* 1994;73:1112-1117.

15. Ananthkrishna Pillai A, Rangaswamy Balasubramanian V, Kanshilal Sharma D. Immediate and long-term follow up results of balloon aortic valvuloplasty in congenital bicuspid aortic valve stenosis among young patients. *J Heart Valve Dis.* 2018;27:17-23.

16. Boe BA, Zampi JD, Kennedy KF, et al. Acute success of balloon aortic valvuloplasty in the current era: a National Cardiovascular Data Registry study. *JACC Cardiovasc Interv.* 2017;10:1717-1726.

17. Martin PS, Kloesel B, Norris RA, et al. Embryonic development of the bicuspid aortic valve. *J Cardiovasc Dev Dis.* 2015;2:248-272.

18. Bons LR, Geenen LW, van den Hoven AT, et al. Blood biomarkers in patients with bicuspid aortic valve disease. *J Cardiol*. 2020;76:287-294.
19. Wedin JO, Vedin O, Rodin S, et al. Patients with bicuspid aortic stenosis demonstrate adverse left ventricular remodeling and impaired cardiac function before surgery with increased risk of postoperative heart failure. *Circulation*. 2022;146:1310-1322.
20. Otto CM, Nishimura RA, Bonow RO, et al. 2020 ACC/AHA guideline for the management of patients with valvular heart disease: a report of the American College of Cardiology/American Heart Association Joint Committee on Clinical Practice Guidelines. *J Am Coll Cardiol*. 2021;77(4):e25-e197.
21. Isselbacher EM, Preventza O, Hamilton Black J, et al. 2022 ACC/AHA guideline for the diagnosis and management of aortic disease: a report of the American Heart Association/American College of Cardiology Joint Committee on Clinical Practice Guidelines. *J Am Coll Cardiol*. 2022;80:e223-e393.
22. Sharew B, Bakhtadze B, Das T, et al. Transcatheter aortic valve replacement in congenital heart disease. *JACC Case Rep*. 2024;29:102199.
23. Chan JSK, Singh S, Eriksen P, et al. Transcatheter aortic valve implantation in bicuspid aortic valve with aortic stenosis: a meta-analysis and trial sequential analysis. *Braz J Cardiovasc Surg*. 2022;37:88-98.
24. Saeed Al-Asad K, Martinez Salazar A, Radwan Y, et al. Transcatheter aortic valve replacement in bicuspid versus tricuspid aortic valve stenosis: meta-analysis and systematic review. *Am J Cardiol*. 2023;203:105-112.
25. Yasuhara J, Schultz K, Bigelow AM, Garg V. Congenital aortic valve stenosis: from pathophysiology to molecular genetics and the need for novel therapeutics. *Front Cardiovasc Med*. 2023;10:1142707.
26. Saeed S, Skaar E, Romarheim A, et al. Shared decision-making and patient-reported outcome measures in valvular heart disease. *Front Cardiovasc Med*. 2022;9:863040.
27. Otto CM, Nishimura RA, Bonow RO, et al. 2020 ACC/AHA guideline for the management of patients with valvular heart disease: a report of the American College of Cardiology/American Heart Association Joint Committee on Clinical Practice Guidelines. *J Am Coll Cardiol*. 2021;77:e25-e197.

#### 4.2.5. Supravalvular Aortic Stenosis

1. Tani LY, Minich LL, Pagotto LT, Shaddy RE. Usefulness of doppler echocardiography to determine the timing of surgery for supravalvular aortic stenosis. *Am J Cardiol*. 2000;86:114-116.
2. Hills JA, Zarate YA, Danylchuk NR, et al. Advanced cardiovascular imaging in Williams syndrome: abnormalities, usefulness, and strategy for use. *Am J Med Genet A*. 2017;173:1194-1199.
3. Sinha M, Parashar N, Pandey NN, et al. Supravalvular aortic stenosis: imaging characteristics and associations on multidetector computed tomography angiography. *J Card Surg*. 2021;36:1389-1400.
4. Yilmaz AT, Arslan M, Ozal E, et al. Coronary artery aneurysm associated with adult supravalvular aortic stenosis. *Ann Thorac Surg*. 1996;62:1205-1207.

5. Greutmann M, Tobler D, Sharma NC, et al. Cardiac outcomes in adults with supravalvular aortic stenosis. *Eur Heart J*. 2012;33:2442-2450.
6. Meccanici F, Notenboom ML, Meijssen J, et al. Long-term surgical outcomes of congenital supravalvular aortic stenosis: a systematic review, meta-analysis and microsimulation study. *Eur J Cardiothorac Surg*. 2024;65:ezad360.
7. Mainwaring RD, Collins RT, Patrick WL, et al. Surgical repair of coronary artery ostial stenosis in patients with Williams and elastin arteriopathy syndromes. *J Thorac Cardiovasc Surg*. 2021;162:212-219.
8. Pansegrau DG, Kioshos JM, Durnin RE, Kroetz FW. Supravalvular aortic stenosis in adults. *Am J Cardiol*. 1973;31:635-641.
9. Vaideeswar P, Shankar V, Deshpande JR, et al. Pathology of the diffuse variant of supravalvular aortic stenosis. *Cardiovasc Pathol*. 2001;10:33-37.
10. Honjo RS, Montealeone VF, Aiello VD, et al. Cardiovascular findings in Williams-Beuren syndrome: experience of a single center with 127 cases. *Am J Med Genet A*. 2022;188:676-682.
11. Zhang R, Xie J, Zhou J, et al. Supravalvular aortic stenosis and the risk of premature death among patients with homozygous familial hypercholesterolemia. *Am J Cardiol*. 2021;145:58-63.
12. Merla G, Brunetti-Pierrri N, Piccolo P, et al. Supravalvular aortic stenosis: elastin arteriopathy. *Circ Cardiovasc Genet*. 2012;5:692-696.
13. Zucker EJ. Syndromes with aortic involvement: pictorial review. *Cardiovasc Diagn Ther*. 2018;8:571-581.
14. Collins R. Cardiovascular disease in Williams syndrome. *Circulation*. 2013;127:2125-2134.
15. Wessel A, Gravenhorst V, Buchhorn R, et al. Risk of sudden death in the Williams-Beuren syndrome. *Am J Med Genet A*. 2004;127A:234-237.
16. Collins RT, Collins MG, Schmitz ML, Hamrick JT. Peri-procedural risk stratification and management of patients with Williams syndrome. *Congenit Heart Dis*. 2017;12:133-142.
17. Algae C, Chubb H, Deitch AM, Collins T. Electrocardiograms do not detect myocardial ischemia in patients with Williams syndrome and nonsyndromic elastin arteriopathy with coronary artery stenosis. *Am J Cardiol*. 2024;215:50-55.
18. Taniguchi T, Morimoto T, Shiomi H, et al. Prognostic impact of left ventricular ejection fraction in patients with severe aortic stenosis. *JACC Cardiovasc Interv*. 2018;11:145-157.
19. Tan AYJ, Quait D, Ghelani SJ, Yuki K. Left ventricular outflow tract gradient is associated with coronary artery obstruction in children with Williams-Beuren syndrome. *J Cardiothorac Vasc Anesth*. 2021;35:3677-3680.
20. Zinyandu T, Montero AJ, Thomas AS, et al. Thirty-year survival after cardiac surgery in children with Williams-Beuren syndrome (from the Pediatric Cardiac Care Consortium study). *Am J Cardiol*. 2023;187:48-53.
21. Martin MM, Lemmer JH Jr, Shaffer E, et al. Obstruction to left coronary artery blood flow secondary to obliteration of the coronary ostium in

supravalvular aortic stenosis. *Ann Thorac Surg*. 1988;45:16-20.

22. Mainwaring RD, Collins RT, Ma M, et al. Surgical repair of supravalvular aortic stenosis in association with transverse and proximal descending aortic abnormalities. *World J Pediatr Congenit Heart Surg*. 2022;13:353-360.
23. Baumgartner H, de Backer J, Babu-Narayan SV, et al. 2020 ESC guidelines for the management of adult congenital heart disease. *Eur Heart J*. 2021;42:563-645.
24. Marelli A, Beauchesne L, Colman J, et al. Canadian Cardiovascular Society 2022 guidelines for cardiovascular interventions in adults with congenital heart disease. *Can J Cardiol*. 2022;38:862-896.
25. Gal DB, Lechich KM, Jensen HK, et al. The sinotubular junction-to-aortic annulus ratio as a determinant of supravalvular aortic stenosis severity. *Am J Cardiol*. 2022;164:118-122.
26. Stout KK, Daniels CJ, Aboulhosn JA, et al. 2018 AHA/ACC guideline for the management of adults with congenital heart disease: a report of the American College of Cardiology/American Heart Association Task Force on Clinical Practice Guidelines. *J Am Coll Cardiol*. 2019;73:e81-e192.

#### 4.2.6. Coarctation of the Aorta

1. Abjigitova D, Mokhles MM, Witsenburg M, et al. Surgical repair of aortic coarctation in adults: half a century of a single centre clinical experience. *Eur J Cardiothorac*. 2019;56:1178-1185.
2. Egbe AC, Miranda WR, Warnes CA, et al. Persistent hypertension and left ventricular hypertrophy after repair of native coarctation of aorta in adults. *Hypertension*. 2021;78(0194911X):672-680.
3. Alvarez-Fuente M, Ayala A, Garrido-Lestache E, et al. Long-term complications after aortic coarctation stenting. *J Am Coll Cardiol*. 2021;77:2448-2450.
4. Egbe AC, Miranda WR, Abozied O, et al. Coarctation of aorta with tricuspid aortic valve is not associated with ascending aortic aneurysm. *J Am Coll Cardiol*. 2024;83:1136-1146.
5. Hager A, Kanz S, Kaemmerer H, et al. Coarctation Long-term Assessment (COALA): significance of arterial hypertension in a cohort of 404 patients up to 27 years after surgical repair of isolated coarctation of the aorta, even in the absence of restenosis and prosthetic material. *J Thorac Cardiovasc Surg*. 2007;134:738-745.
6. de Divitiis M, Pilla C, Kattenhorn M, et al. Ambulatory blood pressure, left ventricular mass, and conduit artery function late after successful repair of coarctation of the aorta. *J Am Coll Cardiol*. 2003;41:2259-2265.
7. Di Salvo G, Castaldi B, Baldini L, et al. Masked hypertension in young patients after successful aortic coarctation repair: impact on left ventricular geometry and function. *J Hum Hypertens*. 2011;25:739-745.
8. Egbe AC, Miranda WR, Connolly HM, et al. Daytime versus nighttime ambulatory blood pressure monitoring in coarctation of aorta. *Hypertension*. 2023;80:e134-e136.
9. Egbe AC, Miranda WR, Bonnicksen CR, et al. Potential benefits of ambulatory blood pressure monitoring in coarctation of aorta. *J Am Coll Cardiol*. 2020;75:2089-2090.

10. Egbe AC, Miranda WR, Jain CC, et al. Prognostic implications of exercise-induced hypertension in adults with repaired coarctation of aorta. *Hypertension*. 2022;79:2796-2805.
  11. Krieger EV, Clair M, Opatowsky AR, et al. Correlation of exercise response in repaired coarctation of the aorta to left ventricular mass and geometry. *Am J Cardiol*. 2013;111:406-411.
  12. Pickard SS, Gauvreau K, Gurvitz M, et al. A national population-based study of adults with coronary artery disease and coarctation of the aorta. *Am J Cardiol*. 2018;122:2120-2124.
  13. Pickard SS, Prakash A, Newburger JW, et al. Screening for Intracranial Aneurysms in Coarctation of the aorta: a decision and cost-effectiveness analysis. *Circ Cardiovasc Qual Outcomes*. 2020;13:e006406.
  14. Eriksson P, Pihkala J, Jensen AS, et al. Transcatheter intervention for coarctation of the aorta: a Nordic population-based registry with long-term follow-up. *JACC*. 2023;16:444-453.
  15. Egbe AC, Warnes CA, Connolly HM. Critical appraisal of the indications for intervention in adults with coarctation of aorta. *J Am Coll Cardiol*. 2020;75:1089-1090.
  16. Egbe AC, Miranda WR, Connolly HM. On-treatment blood pressure and progressive cardiac remodeling in adults with repaired coarctation of aorta. *JACC Imaging*. 2022;15:2012-2014.
  17. Egbe AC, Miranda WR, Jain CC, Connolly HM. On-treatment blood pressure and cardiovascular mortality in adults with repaired coarctation of aorta. *Am Heart J*. 2023;255:22-30.
  18. Egbe AC, Miranda WR, Jain CC, Connolly HM. Right heart dysfunction in adults with coarctation of aorta: prevalence and prognostic implications. *Circ Cardiovasc Imaging*. 2021;14:1100-1108.
  19. Egbe AC, Miranda WR, Ahmed M, et al. Diagnostic and prognostic role of left ventricular strain imaging in adults with coarctation of aorta. *Am J Cardiol*. 2024;211:98-105.
  20. Faganello G, Collià D, Pagura L, et al. Impact of left ventricular hemodynamic forces in adult patients with treated aortic coarctation and preserved left ventricular systolic function. *Echocardiography*. 2024;41:1-9.
  21. Nozaki Y, Nakayama-Inaba K, Ishizu T, et al. Endothelial dysfunction of conduit arteries in patients with repaired coarctation of the aorta. *Int Heart J*. 2018;59:1340-1345.
  22. Quail MA, Short R, Pandya B, et al. Abnormal wave reflections and left ventricular hypertrophy late after coarctation of the aorta repair. *Hypertension*. 2017;69:501-509.
  23. Weismann CG, Maretic A, Grell BS, et al. Multimodal assessment of vascular and ventricular function in children and adults with repaired aortic coarctation. *Int J Cardiol*. 2021;323:47-53.
  24. Labombarda F, Bonopéra M, Maragnes P, et al. Impaired left atrial function in adults and adolescents with corrected aortic coarctation. *Pediatr Cardio*. 2021;42:199-209.
  25. Oliver JM, Gallego P, Gonzalez AE, et al. Pulmonary hypertension in young adults with repaired coarctation of the aorta: an unrecognized factor associated with premature mortality and heart failure. *Int J Cardiol*. 2014;174:324-329.
  26. Egbe AC, Reddy YNV, Ali AE, et al. Clinical features, haemodynamics, and outcomes of heart failure with preserved ejection fraction in coarctation of aorta. *Eur J Heart Fail*. 2024;26(12):2595-2603.
  27. Pickard SS, Gauvreau K, Gurvitz M, et al. Stroke in adults with coarctation of the aorta: a national population-based study. *J Am Heart Assoc*. 2018;7:e009072.
  28. Morgan GJ, Lee KJ, Chaturvedi R, et al. Systemic blood pressure after stent management for arch coarctation implications for clinical care. *JACC Cardiovasc Interv*. 2013;6:192-201.
  29. Cook SC, Ferketich AK, Raman SV. Myocardial ischemia in asymptomatic adults with repaired aortic coarctation. *Int J Cardiol*. 2009;133:95-101.
  30. Egbe AC, Miranda WR, Connolly HM, Borlaug BA. Coarctation of aorta is associated with left ventricular stiffness, left atrial dysfunction and pulmonary hypertension. *Am Heart J*. 2021;241:50-58.
  31. Roifman I, Therrien J, Ionescu-Iltu R, et al. Coarctation of the aorta and coronary artery disease: fact or fiction? *Circulation*. 2012;126:16-21.
  32. Cook SC, Hickey J, Maul TM, et al. Assessment of the cerebral circulation in adults with coarctation of the aorta. *Congenit Heart Dis*. 2013;8:289-295.
  33. Egbe AC, Miranda WR, Jain CC, et al. Low incidence of new intracranial aneurysms in adults with coarctation of aorta on serial brain imaging. *Am J Cardiol*. 2024;216:46-47.
  34. Andrade L, Hoskoppal A, Hunt Martin M, et al. Intracranial aneurysm and coarctation of the aorta: prevalence in the current era. *Cardiol Young*. 2021;31:229-232.
  35. Donti A, Spinardi L, Brighenti M, et al. Frequency of intracranial aneurysms determined by magnetic resonance angiography in children (mean age 16) having operative or endovascular treatment of coarctation of the aorta (mean age 3). *Am J Cardiol*. 2015;116:630-633.
  36. Meidell Blytø V, Rinnström D, Pennert J, et al. Interventions in adults with repaired coarctation of the aorta. *J Am Heart Assoc*. 2022;11:e023954.
  37. Chessa M, Carrozza M, Butera G, et al. Results and mid-long-term follow-up of stent implantation for native and recurrent coarctation of the aorta. *Eur Heart J*. 2005;26:2728-2732.
  38. Erben Y, Oderich GS, Verhagen HJM, et al. Multicenter experience with endovascular treatment of aortic coarctation in adults. *J Vasc Surg*. 2019;69:671-679.e1.
  39. Holzer RJ, Gauvreau K, McEnaney K, et al. Long-term outcomes of the coarctation of the aorta stent trials. *Circ Cardiovasc Interv*. 2021;14:e010308.
  40. Stefanescu Schmidt AC, Armstrong A, Kennedy KF, et al. Procedural characteristics and outcomes of transcatheter interventions for aortic coarctation: a report from the IMPACT Registry. *J Soc Cardiovasc Angiogr Interv*. 2022;1:100393.
  41. Egbe AC, Miranda WR, Connolly HM. Predictors of left ventricular reverse remodeling after coarctation of aorta intervention. *Eur Heart J Cardiovasc Imaging*. 2021;22:1168-1173.
  42. Egbe AC, Anderson JH, Ammash NM, Taggart NW. Left ventricular remodeling after transcatheter versus surgical therapy in adults with coarctation of aorta. *JACC Cardiovasc Imaging*. 2020;13:1863-1872.
  43. Lee MGY, Babu-Narayan SV, Kempny A, et al. Long-term mortality and cardiovascular burden for adult survivors of coarctation of the aorta. *Heart*. 2019;105:1190-1196.
  44. Stout KK, Daniels CJ, Aboulhosn JA, et al. 2018 AHA/ACC guideline for the management of adults with congenital heart disease: a report of the American College of Cardiology/American Heart Association Task Force on Clinical Practice Guidelines. *J Am Coll Cardiol*. 2019;73:e81-e192.
  45. Egbe AC, Anderson JH, Karnakoti S, et al. Assessment of coarctation of aorta gradient: echocardiogram-catheterization correlation. *Am J Cardiol*. 2023;205:420-421.
- #### 4.3.1. Ebstein Anomaly
1. El-Assaad I, DeWitt ES, Mah DY, et al. Accessory pathway ablation in Ebstein anomaly: a challenging substrate. *Heart Rhythm*. 2021;18:1844-1851.
  2. Wei W, Zhan X, Xue Y, et al. Features of accessory pathways in adult Ebstein's anomaly. *Europace*. 2014;16:1619-1625.
  3. Etheridge SP, Escudero CA, Blaufox AD, et al. Life-Threatening Event Risk in Children With Wolff-Parkinson-White Syndrome: A Multicenter International Study. *JACC Clin Electrophysiol*. 2018;4:433-444.
  4. Attenhofer Jost CH, Edmister WD, Julsrud PR, et al. Prospective comparison of echocardiography versus cardiac magnetic resonance imaging in patients with Ebstein's anomaly. *Int J Cardiovasc Imaging*. 2012;28:1147-1159.
  5. Beroukhim RS, Jing L, Harrild DM, et al. Impact of the cone operation on left ventricular size, function, and dyssynchrony in Ebstein anomaly: a cardiovascular magnetic resonance study. *J Cardiovasc Magn Reson*. 2018;20:32.
  6. Rydman R, Shiina Y, Diller GP, et al. Major adverse events and atrial tachycardia in Ebstein's anomaly predicted by cardiovascular magnetic resonance. *Heart*. 2018;104:37-44.
  7. Hughes ML, Bonello B, Choudhary P, et al. A simple measure of the extent of Ebstein valve rotation with cardiovascular magnetic resonance gives a practical guide to feasibility of surgical cone reconstruction. *J Cardiovasc Magn Reson*. 2019;21:34.
  8. Neijenhuis RML, Tsang VT, Marek J, et al. Cone reconstruction for Ebstein anomaly: Late biventricular function and possible remodeling. *J Thorac Cardiovasc Surg*. 2021;161:1097-1108.
  9. Moore JP, Shannon KM, Gallotti RG, et al. Catheter ablation of ventricular arrhythmia for Ebstein's anomaly in unoperated and post-surgical patients. *JACC Clin Electrophysiol*. 2018;4:1300-1307.
  10. Shivapour JK, Sherwin ED, Alexander ME, et al. Utility of preoperative electrophysiologic studies in patients with Ebstein's anomaly undergoing the Cone procedure. *Heart Rhythm*. 2014;11:182-186.
  11. Qureshi MY, Sommer RJ, Cabalka AK. Tricuspid valve imaging and intervention in pediatric and adult patients with congenital heart disease. *JACC Cardiovasc Imaging*. 2019;12:637-651.
  12. Raju V, Dearani JA, Burkhart HM, et al. Right ventricular unloading for heart failure related to

Ebstein malformation. *Ann Thorac Surg.* 2014;98:167-173. discussion 173-174.

13. Miranda WR, Dearani JA, Jain CC, et al. Cardiac catheterization in adults with Ebstein anomaly: pathophysiologic insights regarding surgical repair and prognosis. *Pediatr Cardiol.* 2024;45:591-599.

14. Malhotra A, Patel K, Pandya H, et al. Does addition of bi-directional cavo-pulmonary shunt to tricuspid repair in advanced cases of Ebstein anomaly result in better outcomes? *Gen Thorac Cardiovasc Surg.* 2020;68:1388-1396.

15. Badiu CC, Schreiber C, Horer J, et al. Early timing of surgical intervention in patients with Ebstein's anomaly predicts superior long-term outcome. *Eur J Cardiothorac Surg.* 2010;37:186-192.

16. Ávila-Vanzini N, Friche-Salazar JF, Herrera-Bello H, et al. Impact of surgery in Ebstein's anomaly using current surgical criteria. *Circ J.* 2017;81:1354-1359.

17. Holst KA, Dearani JA, Said S, et al. Improving results of surgery for Ebstein anomaly: where are we after 235 cone repairs? *Ann Thorac Surg.* 2018;105:160-168.

18. Egbe A, Miranda W, Connolly H, Dearani J. Haemodynamic determinants of improved aerobic capacity after tricuspid valve surgery in Ebstein anomaly. *Heart.* 2021;107:1138-1144.

19. Nartowicz SA, Cieplucha A, Wańiewski M, et al. A twenty-year follow-up of adults with Ebstein anomaly with special focus on supraventricular arrhythmias, supraventricular arrhythmias and effectiveness of catheter ablation in 20-year follow-up of adults with Ebstein anomaly. *J Clin Med.* 2024;13:2039.

20. Phillips KA, Dearani JA, Wackel PL, et al. Contemporary early postoperative cone repair outcomes for patients with Ebstein anomaly. *Mayo Clin Proc.* 2023;98:290-298.

21. Oka K, Seki M, Kataoka K, et al. Percutaneous atrial septal defect closure in adult ebstein's anomaly with exertional hypoxemia. *Int Heart J.* 2020;61:620-623.

22. Eckerstrom F, Dellborg M, Hjortdal VE, et al. Mortality in patients with Ebstein anomaly. *J Am Coll Cardiol.* 2023;81:2420-2430.

23. Egbe AC, Miranda WR, Dearani JA, Connolly HM. Hemodynamics and clinical implications of occult left ventricular dysfunction in adults undergoing Ebstein anomaly repair. *Circ Cardiovasc Imaging.* 2021;14:e011739.

24. Hassan A, Tan NY, Aung H, et al. Outcomes of atrial arrhythmia radiofrequency catheter ablation in patients with Ebstein's anomaly. *Europace.* 2018;20:535-540.

25. Martin de Miguel I, Madhavan M, Miranda WR, et al. Prognostic implications of atrial fibrillation in adults with Ebstein anomaly. *Heart.* 2023;109:442-448.

26. Martin de Miguel I, Miranda WR, Madhavan M, et al. Risk factors for atrial arrhythmias in adults with Ebstein anomaly. *JACC Adv.* 2022;1:100058.

27. Khairy P, Van Hare GF, Balaji S, et al. PACES/HRS expert consensus statement on the recognition and management of arrhythmias in adult congenital heart disease. *Heart Rhythm.* 2014;11:e102-e165.

28. Cifra B, Cordina RL, Gauthier N, et al. Cardiopulmonary exercise test interpretation across the lifespan in congenital heart disease: a scientific statement from the American Heart Association. *J Am Heart Assoc.* 2025:e038200.

29. Connolly HM, Dearani JA, Miranda WR. Ebstein : we should do better. *J Am Coll Cardiol.* 2023;81:2431-2433.

30. Stout KK, Daniels CJ, Aboulhosn JA, et al. 2018 AHA/ACC guideline for the management of adults with congenital heart disease: a report of the American College of Cardiology/American Heart Association Task Force on Clinical Practice Guidelines. *J Am Coll Cardiol.* 2019;73:e81-e192.

#### 4.3.2. Valvular Pulmonary Stenosis

1. Chen CR, Cheng TO, Huang T, et al. Percutaneous balloon valvuloplasty for pulmonic stenosis in adolescents and adults. *N Engl J Med.* 1996;335:21-25.

2. Hansen RL, Naimi I, Wang H, et al. Long-term outcomes up to 25 years following balloon pulmonary valvuloplasty: a multicenter study. *Congenit Heart Dis.* 2019;14:1037-1045.

3. Hayes CJ, Gersony WM, Driscoll DJ, et al. Second natural history study of congenital heart defects. Results of treatment of patients with pulmonary valvar stenosis. *Circulation.* 1993;87:128-37.

4. Cuyper JA, Menting ME, Opic P, et al. The unnatural history of pulmonary stenosis up to 40 years after surgical repair. *Heart.* 2017;103:273-279.

5. Deshaies C, Trottier H, Khairy P, et al. Tricuspid intervention following pulmonary valve replacement in adults with congenital heart disease. *J Am Coll Cardiol.* 2020;75:1033-1043.

6. Van den Eynde J, Callahan CP, Lo Rito M, et al. Tricuspid valve intervention at the time of pulmonary valve replacement in adults with congenital heart disease: a systematic review and meta-analysis. *J Am Heart Assoc.* 2021;10:e022909.

7. van der Linde D, Konings EE, Slager MA, et al. Birth prevalence of congenital heart disease worldwide: a systematic review and meta-analysis. *J Am Coll Cardiol.* 2011;58:2241-2247.

8. Kaul UA, Singh B, Tyagi S, et al. Long-term results after balloon pulmonary valvuloplasty in adults. *Am Heart J.* 1993;126:1152-1155.

9. Harrild DM, Powell AJ, Tran TX, et al. Long-term pulmonary regurgitation following balloon valvuloplasty for pulmonary stenosis risk factors and relationship to exercise capacity and ventricular volume and function. *J Am Coll Cardiol.* 2010;55:1041-1047.

10. Morray BH, McElhinney DB. Semilunar valve interventions for congenital heart disease: JACC state-of-the-art review. *J Am Coll Cardiol.* 2021;77:71-79.

11. Jones TK, Rome JJ, Armstrong AK, et al. Transcatheter pulmonary valve replacement reduces tricuspid regurgitation in patients with right ventricular volume/pressure overload. *J Am Coll Cardiol.* 2016;68:1525-1535.

12. Ruckdeschel E, Kim YY. Pulmonary valve stenosis in the adult patient: pathophysiology, diagnosis and management. *Heart.* 2019;105:414-422.

13. Murphy SP, Sultana S, Zern EK, et al. Multimodality imaging evaluation of diseases of the pulmonic valve and right ventricular outflow tract for the

adult cardiologist. *Circ Cardiovasc Imaging.* 2025;18:e017126.

14. Silversides CK, Veldtman GR, Crossin J, et al. Pressure half-time predicts hemodynamically significant pulmonary regurgitation in adult patients with repaired tetralogy of fallot. *J Am Soc Echocardiogr.* 2003;16:1057-1062.

15. Li W, Davlouros PA, Kilner PJ, et al. Doppler-echocardiographic assessment of pulmonary regurgitation in adults with repaired tetralogy of Fallot: comparison with cardiovascular magnetic resonance imaging. *Am Heart J.* 2004;147:165-172.

16. Stout KK, Daniels CJ, Aboulhosn JA, et al. 2018 AHA/ACC guideline for the management of adults with congenital heart disease: a report of the American College of Cardiology/American Heart Association Task Force on Clinical Practice Guidelines. *J Am Coll Cardiol.* 2019;73:e81-e192.

#### 4.3.2.1. Isolated Pulmonary Regurgitation After Repair of Pulmonary Stenosis

1. Zdradzinski MJ, Qureshi AM, Stewart R, et al. Comparison of long-term postoperative sequelae in patients with tetralogy of Fallot versus isolated pulmonic stenosis. *Am J Cardiol.* 2014;114:300-304.

2. Wang Sy, OuYang Rz, Hu Lw, et al. Right and left ventricular interactions, strain, and remodeling in repaired pulmonary stenosis patients with preserved right ventricular ejection fraction: a cardiac magnetic resonance study. *J Magn Reson Imaging.* 2020;52:129-138.

3. Egbe AC, Jain CC, Abozied O, et al. Differences in right heart function after pulmonary valve replacement in patients with pulmonary valve stenosis versus tetralogy of Fallot. *J Am Heart Assoc.* 2024;13:e034833.

4. Laflamme E, Wald RM, Roche SL, et al. Outcome and right ventricle remodelling after valve replacement for pulmonic stenosis. *Heart.* 2022;108:1290-1295.

5. Sinha S, Aboulhosn J, Asnes J, et al. Initial results from the off-label use of the SAPIEN S3 valve for percutaneous transcatheter pulmonary valve replacement: a multi-institutional experience. *Catheter Cardiovasc Interv.* 2019;93:455-463.

6. Martin MH, Meadows J, McElhinney DB, et al. Safety and feasibility of melody transcatheter pulmonary valve replacement in the native right ventricular outflow tract: a multicenter pediatric heart network scholar study. *JACC Cardiovasc Interv.* 2018;11:1642-1650.

7. Van den Eynde J, Callahan CP, Lo Rito M, et al. Tricuspid valve intervention at the time of pulmonary valve replacement in adults with congenital heart disease: a systematic review and meta-analysis. *J Am Heart Assoc.* 2021;10:e022909.

8. Jones TK, Rome JJ, Armstrong AK, et al. Transcatheter pulmonary valve replacement reduces tricuspid regurgitation in patients with right ventricular volume/pressure overload. *J Am Coll Cardiol.* 2016;68:1525-1535.

9. Deshaies C, Trottier H, Khairy P, et al. Tricuspid intervention following pulmonary valve replacement in adults with congenital heart disease. *J Am Coll Cardiol.* 2020;75:1033-1043.

10. Cuypers JA, Menting ME, Opić P, et al. The unnatural history of pulmonary stenosis up to 40 years after surgical repair. *Heart*. 2017;103:273-279.
11. Morray BH, McElhinney DB. Semilunar valve interventions for congenital heart disease: JACC state-of-the-art review. *J Am Coll Cardiol*. 2021;77:71-79.
12. Lim DS, Kim D, Aboulhosn J, et al. Congenital pulmonic valve dysfunction treated with SAPIEN 3 transcatheter heart valve (from the COMPASSION S3 Trial). *Am J Cardiol*. 2023;190:102-109.
13. Ruckdeschel E, Kim YY. Pulmonary valve stenosis in the adult patient: pathophysiology, diagnosis and management. *Heart*. 2019;105:414-422.
14. Stout KK, Daniels CJ, Aboulhosn JA, et al. 2018 AHA/ACC guideline for the management of adults with congenital heart disease: a report of the American College of Cardiology/American Heart Association Task Force on Clinical Practice Guidelines. *J Am Coll Cardiol*. 2019;73:e81-e192.

#### 4.3.3. Management of DCRV

1. Kahr PC, Alonso-Gonzalez R, Kempny A, et al. Long-term natural history and postoperative outcome of double-chambered right ventricle: experience from two tertiary adult congenital heart centres and review of the literature. *Int J Cardiol*. 2014;174:662-668.
2. Lascano ME, Schaad MS, Moodie DS, Murphy D Jr. Difficulty in diagnosing double-chambered right ventricle in adults. *Am J Cardiol*. 2001;88:816-819.
3. Pongiglione G, Freedom RM, Cook D, Rowe RD. Mechanism of acquired right ventricular outflow tract obstruction in patients with ventricular septal defect: an angiographic study. *Am J Cardiol*. 1982;50:776-780.
4. Chang MY, Liou YD, Huang JH, et al. Dynamic cardiac computed tomography characteristics of double-chambered right ventricle. *Sci Rep*. 2022;12:20607.
5. Hachiro Y, Takagi N, Koyanagi T, et al. Repair of double-chambered right ventricle: surgical results and long-term follow-up. *Ann Thorac Surg*. 2001;72:1520-1522.
6. Said SM, Burkhart HM, Dearani JA, et al. Outcomes of surgical repair of double-chambered right ventricle. *Ann Thorac Surg*. 2012;93:197-200.
7. Halder V, Ghosh S, Thingnam SKS, et al. Early and mid-term outcomes of double-chambered right ventricle repair: an 8-year experience. *Cardiol Young*. 2024;34:268-271.
8. Oliver JM, Garrido A, Gonzalez A, et al. Rapid progression of midventricular obstruction in adults with double-chambered right ventricle. *J Thorac Cardiovasc Surg*. 2003;126:711-717.
9. Alva C, Ho SY, Lincoln CR, et al. The nature of the obstructive muscular bundles in double-chambered right ventricle. *J Thorac Cardiovasc Surg*. 1999;117:1180-1188.
10. Otero-Luna A, Ghiroli S, Hsia TY, et al. Diagnosis, surgical management, and long-term outcomes of double chambered right ventricle: a rare and challenging disease in the adult population. *Prog Pediatr*. 2021;62:101417.
11. Cil E, Saraclar M, Ozkutlu S, et al. Double-chambered right ventricle - experience with 52 cases. *Int J Cardiol*. 1995;50:19-29.

12. Kveselis D, Rosenthal A, Ferguson P, et al. Long-term prognosis after repair of double-chamber right ventricle with ventricular septal-defect. *Am J Cardiol*. 1984;54:1292-1295.
13. Zeng YH, Calderone A, Rousseau-Saine N, et al. Right ventricular outflow tract obstruction in adults: a systematic review and meta-analysis. *CJC Open*. 2021;3:1153-1168.
14. Ibrahim T, Dennig K, Schwaiger M, Schömig A. Assessment of double chamber right ventricle by magnetic resonance imaging. *Circulation*. 2002;105:2692-2693.
15. Sachdeva R, Valente AM, Armstrong AK, et al. ACC/AHA/ASE/HRS/ISACHD/SCAI/SCCT/SCMR/SOPE 2020 appropriate use criteria for multimodality imaging during the follow-up care of patients with congenital heart disease: a report of the American College of Cardiology Solution Set Oversight Committee and Appropriate Use Criteria Task Force, American Heart Association, American Society of Echocardiography, Heart Rhythm Society, International Society for Adult Congenital Heart Disease, Society for Cardiovascular Angiography and Interventions, Society of Cardiovascular Computed Tomography, Society for Cardiovascular Magnetic Resonance, and Society of Pediatric Echocardiography. *J Am Coll Cardiol*. 2020;75:657-703.
16. Amano M, Izumi C, Hayama Y, et al. Surgical outcomes and postoperative prognosis beyond 10 years for double-chambered right ventricle. *Am J Cardiol*. 2015;116:1431-1435.
17. Stout KK, Daniels CJ, Aboulhosn JA, et al. 2018 AHA/ACC guideline for the management of adults with congenital heart disease: a report of the American College of Cardiology/American Heart Association Task Force on Clinical Practice Guidelines. *J Am Coll Cardiol*. 2019;73:e81-e192.

#### 4.3.4. Isolated Branch Pulmonary Artery Stenosis

1. Hafiz R, Kocaoglu M, Trout AT. Comparison of phase contrast magnetic resonance imaging and scintigraphy for determination of split pulmonary blood flow in children and young adults with congenital heart disease. *Pediatr Radiol*. 2023;53:2040-2047.
2. Hiremath G, Qureshi AM, Prieto LR, et al. Balloon angioplasty and stenting for unilateral branch pulmonary artery stenosis improve exertional performance. *JACC Cardiovasc Interv*. 2019;12:289-297.
3. Joosen RS, Frissen JPB, van den Hoogen A, et al. The effects of percutaneous branch pulmonary artery interventions on exercise capacity, lung perfusion, and right ventricular function in biventricular CHD: a systematic review. *Cardiol Young*. 2024;34:473-482.
4. Holzer RJ, Gauvreau K, Kreutzer J, et al. Balloon angioplasty and stenting of branch pulmonary arteries: adverse events and procedural characteristics: results of a multi-institutional registry. *Circ Cardiovasc Interv*. 2011;4:287-296.
5. Hascoet S, Jalal Z, Baruteau A, et al. Stenting in paediatric and adult congenital heart diseases: a French multicentre study in the current era. *Arch Cardiovasc Dis*. 2015;108:650-660.
6. Vadher AB, Shaw M, Pandey NN, et al. Stenotic lesions of pulmonary arteries: imaging evaluation using multidetector computed tomography angiography. *Imaging*. 2021;69:17-26.

7. Goo HW. Computed tomography pulmonary vascular volume ratio can be used to evaluate the effectiveness of pulmonary angioplasty in peripheral pulmonary artery stenosis. *Korean J Radiol*. 2019;20:1422-1430.
8. Kanezawa M, Shimokawahara H, Tsuji M, et al. The results of genetic analysis and clinical outcomes after stent deployment in adult patients with isolated peripheral pulmonary artery stenosis. *Eur Respir J*. 2023;62:2301511.
9. Hiremath G, Qureshi AM, Meadows J, Aggarwal V. Treatment approach to unilateral branch pulmonary artery stenosis. *Trends Cardiovasc Med*. 2021;31:179-184.
10. Goldstein BH, Kreutzer J. Transcatheter intervention for congenital defects involving the great vessels: JACC review topic of the week. *J Am Coll Cardiol*. 2021;77:80-96.
11. Patel AB, Ratnayaka K, Bergersen L. A review: percutaneous pulmonary artery stenosis therapy: state-of-the-art and look to the future. *Cardiol Young*. 2019;29:93-99.
12. Stout KK, Daniels CJ, Aboulhosn JA, et al. 2018 AHA/ACC guideline for the management of adults with congenital heart disease: a report of the American College of Cardiology/American Heart Association Task Force on Clinical Practice Guidelines. *J Am Coll Cardiol*. 2019;73:e81-e192.

#### 4.3.5. Tetralogy of Fallot

1. Egbe AC, Pislaru SV, Kothapalli S, et al. The role of echocardiography for quantitative assessment of right ventricular size and function in adults with repaired tetralogy of Fallot. *Congenit Heart Dis*. 2019;14:700-705.
2. Zdradzinski M, Elkin R, Flamm S, Krasuski R. Incremental value of cardiac magnetic resonance for assessing pulmonic valve regurgitation. *J Heart Valve Dis*. 2015;24:502-507.
3. Morray BH, McElhinney DB, Cheatham JP, et al. Risk of coronary artery compression among patients referred for transcatheter pulmonary valve implantation: a multicenter experience. *Circ Cardiovasc Interv*. 2013;6:535-542.
4. Curran L, Agrawal H, Kallianos K, et al. Computed tomography guided sizing for transcatheter pulmonary valve replacement. *Int J Cardiol Heart Vasc*. 2020;29:100523.
5. Han BK, Garcia S, Aboulhosn J, et al. Technical recommendations for computed tomography guidance of intervention in the right ventricular outflow tract: native RVOT, conduits and bioprosthetic valves: a white paper of the Society of Cardiovascular Computed Tomography (SCCT), Congenital Heart Surgeons' Society (CHSS), and Society for Cardiovascular Angiography & Interventions (SCAI). *J Cardiovasc Comput Tomogr*. 2024;18:75-99.
6. Sandhu A, Ruckdeschel E, Sauer WH, et al. Perioperative electrophysiology study in patients with tetralogy of Fallot undergoing pulmonary valve replacement will identify those at high risk of subsequent ventricular tachycardia. *Heart Rhythm*. 2018;15:679-685.
7. Brouwer C, Kapel GFL, Jongbloed MRM, et al. Noninvasive identification of ventricular tachycardia-

- related anatomical isthmuses in repaired tetralogy of Fallot: what is the role of the 12-lead ventricular tachycardia electrocardiogram. *JACC Clin Electrophysiol.* 2018;4:1308-1318.
8. Waldmann V, Bessière F, Gardey K, et al. Systematic electrophysiological study prior to pulmonary valve replacement in tetralogy of Fallot: a prospective multicenter study. *Circ Arrhythm Electrophysiol.* 2023;16:e011745.
  9. Bouyer B, Jalal Z, Daniel Ramirez F, et al. Electrophysiological study prior to planned pulmonary valve replacement in patients with repaired tetralogy of Fallot. *J Cardiovasc Electrophysiol.* 2023;34:1395-1404.
  10. Moore JP, Waldmann V, Bessiere F, et al. Age-related ventricular tachycardia substrate characteristics for repaired tetralogy of Fallot before transcatheter pulmonary valve placement. *JACC Clin Electrophysiol.* 2025;11:551-562.
  11. Kimura Y, Wallet J, Bouyer B, et al. Three-dimensional cardiac magnetic resonance allows the identification of slow-conducting anatomical isthmuses in tetralogy of Fallot. *Eur Heart J.* 2024;45:2079-2094.
  12. Moore JP, Shannon KM, Khairy P, et al. Sinus rhythm QRS morphology reflects right ventricular activation and anatomical ventricular tachycardia isthmus conduction in repaired tetralogy of Fallot. *Heart Rhythm.* 2023;20:1689-1696.
  13. Bokma JP, Winter MM, Vehmeijer JT, et al. QRS fragmentation is superior to QRS duration in predicting mortality in adults with tetralogy of Fallot. *Heart.* 2017;103:666-671.
  14. Moore JP, Su J, Shannon KM, et al. Multidetector computed tomography assessment of anatomical ventricular tachycardia isthmuses in repaired tetralogy of Fallot. *JACC Clin Electrophysiol.* 2024;10:857-866.
  15. Lee C, Choi ES, Lee CH. Long-term outcomes of pulmonary valve replacement in patients with repaired tetralogy of Fallot. *Eur J Cardiothorac Surg.* 2020;58:246-252.
  16. Bokma JP, Geva T, Sleeper LA, et al. Improved outcomes after pulmonary valve replacement in repaired tetralogy of Fallot. *J Am Coll Cardiol.* 2023;81:2075-2085.
  17. Vehmeijer JT, Koyak Z, Leerink JM, et al. Identification of patients at risk of sudden cardiac death in congenital heart disease: the PROspectiVE study on implanTABLE cardioverter defibrillator therapy and sudden cardiac death in Adults with Congenital Heart Disease (PREVENTION-ACHD). *Heart Rhythm.* 2021;18:785-792.
  18. Ghonim S, Gatzoulis MA, Ernst S, et al. Predicting survival in repaired tetralogy of Fallot: a lesion-specific and personalized approach. *JACC Cardiovasc Imaging.* 2022;15:257-268.
  19. Atallah J, Gonzalez Corcia MC, Walsh EP, et al. Ventricular arrhythmia and life-threatening events in patients with repaired tetralogy of Fallot. *Am J Cardiol.* 2020;132:126-132.
  20. Kawada S, Chakraborty P, Downar E, et al. The role of ablation in prevention of recurrent implantable cardioverter defibrillator shocks in patients with tetralogy of Fallot. *CJC Open.* 2021;3:619-626.
  21. Bessière F, Gardey K, Bouzeman A, et al. Impact of pulmonary valve replacement on ventricular arrhythmias in patients with tetralogy of Fallot and implantable cardioverter-defibrillator. *JACC Clin Electrophysiol.* 2021;7:1285-1293.
  22. Kim W, Kwak JG, Kwon HW, et al. Pulmonary valve replacement may not restore ventricular volume and functional status in patients with pulmonary regurgitation after late tetralogy of Fallot repair. *Eur J Cardiothorac Surg.* 2021;61:64-72.
  23. Jones TK, Rome JJ, Armstrong AK, et al. Transcatheter pulmonary valve replacement reduces tricuspid regurgitation in patients with right ventricular volume/pressure overload. *J Am Coll Cardiol.* 2016;68:1525-1535.
  24. Kapel GF, Reichlin T, Wijnmaalen AP, et al. Re-entry using anatomically determined isthmuses: a curable ventricular tachycardia in repaired congenital heart disease. *Circ Arrhythm Electrophysiol.* 2015;8:102-109.
  25. van Zyl M, Kapa S, Padmanabhan D, et al. Mechanism and outcomes of catheter ablation for ventricular tachycardia in adults with repaired congenital heart disease. *Heart Rhythm.* 2016;13:1449-1454.
  26. Kapel GF, Sacher F, Dekkers OM, et al. Arrhythmogenic anatomical isthmuses identified by electroanatomical mapping are the substrate for ventricular tachycardia in repaired tetralogy of Fallot. *Eur Heart J.* 2017;38:268-276.
  27. Karamlou T, Silber I, Lao R, et al. Outcomes after late reoperation in patients with repaired tetralogy of Fallot: the impact of arrhythmia and arrhythmia surgery. *Ann Thorac Surg.* 2006;81:1786-1793. discussion 1793.
  28. Sabate Rotes A, Connolly HM, Warnes CA, et al. Ventricular arrhythmia risk stratification in patients with tetralogy of Fallot at the time of pulmonary valve replacement. *Circ Arrhythm Electrophysiol.* 2015;8:110-116.
  29. Egbe AC, Najam M, Banala K, et al. Impact of atrial arrhythmia on survival in adults with tetralogy of Fallot. *Am Heart J.* 2019;218:1-7.
  30. Silka MJ, Hardy BG, Menashe VD, Morris CD. A population-based prospective evaluation of risk of sudden cardiac death after operation for common congenital heart defects. *J Am Coll Cardiol.* 1998;32:245-251.
  31. Nollert G, Fischlein T, Bouterwek S, et al. Long-term survival in patients with repair of tetralogy of Fallot: 36-year follow-up of 490 survivors of the first year after surgical repair. *J Am Coll Cardiol.* 1997;30:1374-1383.
  32. Mouws E, Roos-Hesslink JW, Bogers A, de Groot NMS. Coexistence of tachyarrhythmias in patients with tetralogy of Fallot. *Heart Rhythm.* 2018;15:503-511.
  33. Khairy P, Aboulhosn J, Gurvitz MZ, et al. Arrhythmia burden in adults with surgically repaired tetralogy of Fallot: a multi-institutional study. *Circulation.* 2010;122:868-875.
  34. Aboulhosn JA, Lluri G, Gurvitz MZ, et al. Left and right ventricular diastolic function in adults with surgically repaired tetralogy of Fallot: a multi-institutional study. *Can J Cardiol.* 2013;29:866-872.
  35. Diller GP, Kempny A, Liodakis E, et al. Left ventricular longitudinal function predicts life-threatening ventricular arrhythmia and death in adults with repaired tetralogy of Fallot. *Circulation.* 2012;125:2440-2446.
  36. Egbe AC, Adigun R, Anand V, et al. Left ventricular systolic dysfunction and cardiovascular outcomes in tetralogy of Fallot: systematic review and meta-analysis. *Can J Cardiol.* 2019;35:1784-1790.
  37. Gatzoulis MA, Balaji S, Webber SA, et al. Risk factors for arrhythmia and sudden cardiac death late after repair of tetralogy of Fallot: a multicentre study. *Lancet.* 2000;356:975-981.
  38. Khairy P, Harris L, Landzberg MJ, et al. Implantable cardioverter-defibrillators in tetralogy of Fallot. *Circulation.* 2008;117:363-370.
  39. Dickey J, Phelan C. Unrepaired tetralogy of Fallot in adulthood. *N Engl J Med.* 2020;382:e97.
  40. Valente AM, Cook S, Festa P, et al. Multimodality imaging guidelines for patients with repaired tetralogy of fallot: a report from the American Society of Echocardiography: developed in collaboration with the Society for Cardiovascular Magnetic Resonance and the Society for Pediatric Radiology. *J Am Soc Echocardiogr.* 2014;27:111-141.
  41. Sachdeva R, Valente AM, Armstrong AK, et al. ACC/AHA/ASE/HRS/ISACHD/SCAI/SCCT/SCMR/SOPE 2020 appropriate use criteria for multimodality imaging during the follow-up care of patients with congenital heart disease: a report of the American College of Cardiology Solution Set Oversight Committee and Appropriate Use Criteria Task Force, American Heart Association, American Society of Echocardiography, Heart Rhythm Society, International Society for Adult Congenital Heart Disease, Society for Cardiovascular Angiography and Interventions, Society of Cardiovascular Computed Tomography, Society for Cardiovascular Magnetic Resonance, and Society of Pediatric Echocardiography. *J Am Coll Cardiol.* 2020;75:657-703.
  42. Vitarelli A, Capotosto L, Miraldi F, et al. Biventricular interaction and aortic function in adult patients with repaired tetralogy of Fallot: a two-dimensional-three-dimensional speckle-tracking echocardiographic study. *Eur Heart J Imaging Methods Pract.* 2024;2:qyae015.
  43. Oliveira ALA, de Oliveira MEP, Guimaraes LV, et al. Evaluation of right ventricle systolic function after tetralogy of Fallot repair: a systematic review comparing cardiac magnetic resonance and global longitudinal strain. *Echocardiography.* 2023;40:4-14.
  44. Arroyo-Rodriguez C, Fritche-Salazar JF, Posada-Martinez EL, et al. Right ventricular free wall strain predicts functional capacity in patients with repaired tetralogy of Fallot. *Int J Cardiovasc Imaging.* 2020;36:595-604.
  45. Franceschi P, Balducci A, Nardi E, et al. Predictive value of cardiac magnetic resonance: new and old parameters in the natural history of repaired tetralogy of Fallot. *BMC Cardiovasc Disord.* 2024;24:15.
  46. Mayourian J, Sleeper LA, Lee JH, et al. Development and validation of a mortality risk score for repaired tetralogy of Fallot. *J Am Heart Assoc.* 2024;13:e034871.
  47. Rinaldi E, Sadeghi S, Rajpal S, et al. Utility of CT angiography for the prediction of coronary artery compression in patients undergoing transcatheter pulmonary valve replacement. *World J Pediatr Congenit Heart Surg.* 2020;11:295-303.
  48. Scherptong RW, Hazekamp MG, Mulder BJ, et al. Follow-up after pulmonary valve replacement in adults with tetralogy of Fallot: association between

QRS duration and outcome. *J Am Coll Cardiol.* 2010;56:1486-1492.

49. Park SJ, On YK, Kim JS, et al. Relation of fragmented QRS complex to right ventricular fibrosis detected by late gadolinium enhancement cardiac magnetic resonance in adults with repaired tetralogy of Fallot. *Am J Cardiol.* 2012;109:110-115.

50. Koyak Z, de Groot JR, Bouma BJ, et al. Symptomatic but not asymptomatic non-sustained ventricular tachycardia is associated with appropriate implantable cardioverter therapy in tetralogy of Fallot. *Int J Cardiol.* 2013;167:1532-1535.

51. Koyak Z, Harris L, de Groot JR, et al. Sudden cardiac death in adult congenital heart disease. *Circulation.* 2012;126:1944-1954.

52. Khairy P, Landzberg MJ, Gatzoulis MA, et al. Value of programmed ventricular stimulation after tetralogy of Fallot repair: a multicenter study. *Circulation.* 2004;109:1994-2000.

53. Khairy P. Programmed ventricular stimulation for risk stratification in patients with tetralogy of Fallot: a Bayesian perspective. *Nat Clin Pract Cardiovasc Med.* 2007;4:292-293.

54. DiLorenzo M, Hwang WT, Goldmuntz E, et al. Diastolic dysfunction in tetralogy of Fallot: comparison of echocardiography with catheterization. *Echocardiography.* 2018;35:1641-1648.

55. Dobbels B, Herregods MC, Troost E, et al. Early versus late pulmonary valve replacement in patients with transannular patch-repaired tetralogy of Fallot. *Interact Cardiovasc Thorac Surg.* 2017;25:427-433.

56. Mongeon FP, Ben Ali W, Khairy P, et al. Pulmonary valve replacement for pulmonary regurgitation in adults with tetralogy of Fallot: a meta-analysis—a report for the Writing Committee of the 2019 Update of the Canadian Cardiovascular Society Guidelines for the Management of Adults With Congenital Heart Disease. *Can J Cardiol.* 2019;35:1772-1783.

57. Wu MH, Wang JK, Chiu SN, et al. Long-term outcome of repaired tetralogy of Fallot: survival, tachyarrhythmia, and impact of pulmonary valve replacement. *Heart Rhythm.* 2022;19:1856-1863.

58. Kapel GF, Reichlin T, Wijnmaalen AP, et al. Left-sided ablation of ventricular tachycardia in adults with repaired tetralogy of Fallot: a case series. *Circ Arrhythm Electrophysiol.* 2014;7:889-897.

59. Oechslin EN, Harrison DA, Harris L, et al. Reoperation in adults with repair of tetralogy of Fallot: indications and outcomes. *J Thorac Cardiovasc Surg.* 1999;118:245-251.

60. Caldaroni F, Lo Rito M, Chessa M, et al. Surgical ablation of ventricular tachycardia in patients with repaired tetralogy of Fallot. *Eur J Cardiothorac Surg.* 2019;55:845-850.

61. Zeppenfeld K, Schalij MJ, Bartelings MM, et al. Catheter ablation of ventricular tachycardia after repair of congenital heart disease: electroanatomic identification of the critical right ventricular isthmus. *Circulation.* 2007;116:2241-2252.

62. Kapel GFL, Brouwer C, Jalal Z, et al. Slow conducting electroanatomic isthmuses: an important link between QRS duration and ventricular tachycardia in tetralogy of Fallot. *JACC Clin Electrophysiol.* 2018;4:781-793.

63. Wallet J, Kimura Y, Blom NA, et al. The R' wave in V1 and the negative terminal QRS vector in aVF

combine to a novel 12-lead ECG algorithm to identify slow conducting anatomical isthmus 3 in patients with tetralogy of Fallot. *Europace.* 2023;25:eud139.

64. Rivas-Gándara N, Dos-Subirá L, Francisco-Pascual J, et al. Substrate characterization of the right ventricle in repaired tetralogy of Fallot using late enhancement cardiac magnetic resonance. *Heart Rhythm.* 2021;18:1868-1875.

65. Van den Eynde J, Sa M, Vervoort D, et al. Pulmonary valve replacement in tetralogy of Fallot: an updated meta-analysis. *Ann Thorac Surg.* 2022;113:1036-1046.

66. Massarella D, McCrindle BW, Runeckles K, et al. Adherence to clinical practice guidelines for pulmonary valve intervention after tetralogy of Fallot repair: a nationwide cohort study. *JTCVS Open.* 2024;17:215-228.

67. Dallaire F, Wald RM, Marelli A. The role of cardiopulmonary exercise testing for decision making in patients with repaired tetralogy of Fallot. *Pediatr Cardiol.* 2017;38:1097-1105.

68. Geva T, Mulder B, Gauvreau K, et al. Preoperative predictors of death and sustained ventricular tachycardia after pulmonary valve replacement in patients with repaired tetralogy of Fallot enrolled in the IN-DICATOR cohort. *Circulation.* 2018;138:2106-2115.

69. Spiewak M, Malek LA, Petryka J, et al. The ratio of right ventricular volume to left ventricular volume reflects the impact of pulmonary regurgitation independently of the method of pulmonary regurgitation quantification. *Eur J Radiol.* 2012;81:e977-e981.

70. Pastor TA, Geva T, Lu M, et al. Relation of right ventricular dilation after pulmonary valve replacement to outcomes in patients with repaired tetralogy of Fallot. *Am J Cardiol.* 2020;125:977-981.

71. Alsaied T, Geva T, Graf JA, et al. Biventricular global function index is associated with adverse outcomes in repaired tetralogy of Fallot. *Circ Cardiovasc Imaging.* 2021;14:e012519.

72. Geva T, Wald RM, Bucholz E, et al. Long-term management of right ventricular outflow tract dysfunction in repaired tetralogy of Fallot: a scientific statement from the American Heart Association. *Circulation.* 2024;150:e689-e707.

73. Beurskens NEG, Hagdorn QAJ, Gorter TM, et al. Risk of cardiac tachyarrhythmia in patients with repaired tetralogy of Fallot: a multicenter cardiac MRI based study. *Int J Cardiovasc Imaging.* 2019;35:143-151.

74. Ghonim S, Ernst S, Keegan J, et al. Three-dimensional late gadolinium enhancement cardiovascular magnetic resonance predicts inducibility of ventricular tachycardia in adults with repaired tetralogy of Fallot. *Circ Arrhythm Electrophysiol.* 2020;13:e008321.

75. Babu-Narayan SV, Kilner PJ, Li W, et al. Ventricular fibrosis suggested by cardiovascular magnetic resonance in adults with repaired tetralogy of Fallot and its relationship to adverse markers of clinical outcome. *Circulation.* 2006;113:405-413.

76. Bonello B, Kempny A, Uebing A, et al. Right atrial area and right ventricular outflow tract akinetic length predict sustained tachyarrhythmia in repaired tetralogy of Fallot. *Int J Cardiol.* 2013;168:3280-3286.

77. Hagdorn QAJ, Vos JDL, Beurskens NEG, et al. CMR feature tracking left ventricular strain-rate predicts ventricular tachyarrhythmia, but not deterioration of

ventricular function in patients with repaired tetralogy of Fallot. *Int J Cardiol.* 2019;295:1-6.

78. Rizk J, Shehu N, Latus H, et al. Magnetic resonance imaging risk factors for ventricular arrhythmias in tetralogy of Fallot. *Pediatr Cardiol.* 2020;41:862-868.

79. Bhavnani SP, Giedrimiene D, Coleman CI, et al. The healthcare utilization and cost of treating patients experiencing inappropriate implantable cardioverter defibrillator shocks: a propensity score study. *Pacing Clin Electrophysiol.* 2014;37:1315-1323.

80. Sears SF Jr, Conti JB. Quality of life and psychological functioning of ICD patients. *Heart.* 2002;87:488-493.

81. Blalock SE, Banka P, Geva T, et al. Interstudy variability in cardiac magnetic resonance imaging measurements of ventricular volume, mass, and ejection fraction in repaired tetralogy of Fallot: a prospective observational study. *J Magn Reson Imaging.* 2013;38:829-835.

82. Greutmann M, Ruperti J, Schwitz F, et al. High variability of right ventricular volumes and function in adults with severe pulmonary regurgitation late after tetralogy of Fallot repair. *Am J Cardiol.* 2022;166:88-96.

83. Egbe AC, Pellikka PA, Afzal A, et al. Prognostic implications of left ventricular cardiomyopathy in adults with tetralogy of Fallot. *CJC Open.* 2020;2:1-7.

84. DeZorzi C, Marengo A, Valente AM. Tricuspid regurgitation in patients with tetralogy of Fallot. *J Clin Med.* 2023;12:2470.

85. Cramer JW, Ginde S, Hill GD, et al. Tricuspid repair at pulmonary valve replacement does not alter outcomes in tetralogy of Fallot. *Ann Thorac Surg.* 2015;99:899-904.

86. Deshaies C, Cottrier H, Khairy P, et al. Tricuspid intervention following pulmonary valve replacement in adults with congenital heart disease. *J Am Coll Cardiol.* 2020;75:1033-1043.

87. Kogon B, Mori M, Alsoufi B, et al. Leaving moderate tricuspid valve regurgitation alone at the time of pulmonary valve replacement: a worthwhile approach. *Ann Thorac Surg.* 2015;99:2117-2122. discussion 2122-2123.

88. Laredo M, Frank R, Waintraub X, et al. Ten-year outcomes of monomorphic ventricular tachycardia catheter ablation in repaired tetralogy of Fallot. *Arch Cardiovasc Dis.* 2017;110:292-302.

89. Harrild DM, Berul CI, Cecchin F, et al. Pulmonary valve replacement in tetralogy of Fallot: impact on survival and ventricular tachycardia. *Circulation.* 2009;119:445-451.

90. Stout KK, Daniels CJ, Aboulhosn JA, et al. 2018 AHA/ACC guideline for the management of adults with congenital heart disease: a report of the American College of Cardiology/American Heart Association Task Force on Clinical Practice Guidelines. *J Am Coll Cardiol.* 2019;73:e81-e192.

#### 4.3.6. Pulmonary Atresia With Intact Ventricular Septum

1. Schneider AW, Blom NA, Bruggemans EF, Hazekamp MG. More than 25 years of experience in managing pulmonary atresia with intact ventricular septum. *Ann Thorac Surg.* 2014;98:1680-1686.

2. John AS, Warnes CA. Clinical outcomes of adult survivors of pulmonary atresia with intact ventricular septum. *Int J Cardiol.* 2012;161:13-17.
3. Mishima A, Asano M, Sasaki S, et al. Long-term outcome for right heart function after biventricular repair of pulmonary atresia and intact ventricular septum. *Jpn J Thorac Cardiovasc Surg.* 2000;48:145-152.
4. Liang XC, Lam WW, Cheung EW, et al. Restrictive right ventricular physiology and right ventricular fibrosis as assessed by cardiac magnetic resonance and exercise capacity after biventricular repair of pulmonary atresia and intact ventricular septum. *Clin Cardiol.* 2010;33:104-110.
5. Elias P, Poh CL, du Plessis K, et al. Long-term outcomes of single-ventricle palliation for pulmonary atresia with intact ventricular septum: Fontan survivors remain at risk of late myocardial ischaemia and death. *Eur J Cardiothorac Surg.* 2018;53:1230-1236.
6. Sukhvasi A, McHugh-Grant S, Glatz AC, et al. Pulmonary atresia with intact ventricular septum: intended strategies. *J Thorac Cardiovasc Surg.* 2022;164:1277-1288.
7. Toh N, Kotani Y, Akagi T, et al. Outcomes of patients with pulmonary atresia with intact ventricular septum reaching adulthood. *Congenit Heart Dis.* 2020;15:1-11.
8. Montanaro C, Merola A, Kempny A, et al. The outcome of adults born with pulmonary atresia: high morbidity and mortality irrespective of repair. *Int J Cardiol.* 2019;280:61-66.
9. Jain CC, Egbe AC, Stephens EH, et al. Systemic venous hypertension and low output are prevalent at catheterization in adults with pulmonary atresia and intact ventricular septum regardless of repair strategy. *Semin Thorac Cardiovasc Surg.* 2022;34:1312-1319.
10. Egbe AC, Miranda WR, Connolly HM. Prognostic implications of right atrial dysfunction in adults with pulmonary atresia and intact ventricular septum. *CJC Pediatr Congenit Heart Dis.* 2022;1:23-29.

#### 4.3.7. Management of Right Ventricle-to-Pulmonary Artery Conduits

1. Morray BH, McElhinney DB, Cheatham JP, et al. Risk of coronary artery compression among patients referred for transcatheter pulmonary valve implantation: a multicenter experience. *Circ Cardiovasc Interv.* 2013;6:535-542.
2. Rinaldi E, Sadeghi S, Rajpal S, et al. Utility of CT angiography for the prediction of coronary artery compression in patients undergoing transcatheter pulmonary valve replacement. *World J Pediatr Congenit Heart Surg.* 2020;11:295-303.
3. McElhinney DB, Cheatham JP, Jones TK, et al. Stent fracture, valve dysfunction, and right ventricular outflow tract reintervention after transcatheter pulmonary valve implantation: patient-related and procedural risk factors in the US Melody Valve Trial. *Circ Cardiovasc Interv.* 2011;4:602-614.
4. Cabalka AK, Hellenbrand WE, Eicken A, et al. Relationships among conduit type, pre-stenting, and outcomes in patients undergoing transcatheter pulmonary valve replacement in the prospective North American and European melody valve trials. *JACC Cardiovasc Interv.* 2017;10:1746-1759.
5. McElhinney DB, Sondergaard L, Armstrong AK, et al. Endocarditis after transcatheter pulmonary valve replacement. *J Am Coll Cardiol.* 2018;72:2717-2728.
6. McElhinney DB, Zhang Y, Aboulhosn JA, et al. Multicenter study of endocarditis after transcatheter pulmonary valve replacement. *J Am Coll Cardiol.* 2021;78:575-589.
7. Lluri G, Levi DS, Miller E, et al. Incidence and outcome of infective endocarditis following percutaneous versus surgical pulmonary valve replacement. *Catheter Cardiovasc Interv.* 2018;91:277-284.
8. Sadeghi S, Wadia S, Lluri G, et al. Risk factors for infective endocarditis following transcatheter pulmonary valve replacement in patients with congenital heart disease. *Catheter Cardiovasc Interv.* 2019;94:625-635.
9. Egbe A, Pislaru SV, Ali MA, et al. Early Prosthetic valve dysfunction due to bioprosthetic valve thrombosis: the role of echocardiography. *JACC Cardiovasc Imaging.* 2018;11:951-958.
10. Peng LF, McElhinney DB, Nugent AW, et al. Endovascular stenting of obstructed right ventricle-to-pulmonary artery conduits: a 15-year experience. *Circulation.* 2006;113:2598-2605.
11. Zahn EM, Hellenbrand WE, Lock JE, McElhinney DB. Implantation of the melody transcatheter pulmonary valve in patients with a dysfunctional right ventricular outflow tract conduit early results from the US clinical trial. *J Am Coll Cardiol.* 2009;54:1722-1729.
12. Daily JA, Tang X, Angtuaco M, et al. Transcatheter versus surgical pulmonary valve replacement in repaired tetralogy of fallot. *Am J Cardiol.* 2018;122:498-504.
13. Georgiev S, Ewert P, Tanase D, et al. A low residual pressure gradient yields excellent long-term outcome after percutaneous pulmonary valve implantation. *JACC Cardiovasc Interv.* 2019;12:1594-1603.
14. McElhinney DB, Hellenbrand WE, Zahn EM, et al. Short- and medium-term outcomes after transcatheter pulmonary valve placement in the expanded multicenter US melody valve trial. *Circulation.* 2010;122:507-516.
15. Lurz P, Nordmeyer J, Giardini A, et al. Early versus late functional outcome after successful percutaneous pulmonary valve implantation: are the acute effects of altered right ventricular loading all we can expect? *J Am Coll Cardiol.* 2011;57:724-731.
16. Frigiola A, Tsang V, Nordmeyer J, et al. Current approaches to pulmonary regurgitation. *Eur J Cardiothorac Surg.* 2008;34:576-580. discussion 581-582.
17. Coats L, Khambadkone S, Derrick G, et al. Physiological and clinical consequences of relief of right ventricular outflow tract obstruction late after repair of congenital heart defects. *Circulation.* 2006;113:2037-2044.
18. Tanase D, Ewert P, Georgiev S, et al. Tricuspid regurgitation does not impact right ventricular remodeling after percutaneous pulmonary valve implantation. *JACC Cardiovasc Interv.* 2017;10:701-708.
19. Jones TK, Rome JJ, Armstrong AK, et al. Transcatheter pulmonary valve replacement reduces tricuspid regurgitation in patients with right ventricular volume/pressure overload. *J Am Coll Cardiol.* 2016;68:1525-1535.
20. Whiteside W, Tretter JT, Aboulhosn J, et al. Acute and midterm outcomes of transcatheter pulmonary valve replacement for treatment of dysfunctional left ventricular outflow tract conduits in patients with aortopulmonary transposition and a systemic right ventricle. *Circ Cardiovasc Interv.* 2017;10:e004730.
21. Willetts RG, Stickley J, Drury NE, et al. Four right ventricle to pulmonary artery conduit types. *J Thorac Cardiovasc Surg.* 2021;162:1324-1333.e3.
22. Callahan CP, Jegatheeswaran A, Blackstone EH, et al. Time-related risk of pulmonary conduit replacement: a Congenital Heart Surgeons' Society study. *Ann Thorac Surg.* 2022;113:623-629.
23. Jones TK, McElhinney DB, Vincent JA, et al. Long-term outcomes after melody transcatheter pulmonary valve replacement in the US investigational device exemption trial. *Circ Cardiovasc Interv.* 2022;15:e010852.
24. Han BK, Garcia S, Aboulhosn J, et al. Technical recommendations for computed tomography guidance of intervention in the right ventricular outflow tract: native RVOT, conduits, and bioprosthetic valves. *World J Pediatr Congenit Heart Surg.* 2023;14:761-791.
25. Abdelghani M, Nassif M, Blom NA, et al. Infective endocarditis after melody valve implantation in the pulmonary position: a systematic review. *J Am Heart Assoc.* 2018;7:e008163.
26. Jewgenow P, Schneider H, Bökenkamp R, et al. Subclinical thrombus formation in bioprosthetic pulmonary valve conduits. *Int J Cardiol.* 2019;281:113-118.
27. Hascoët S, Bentham JR, Giugno L, et al. Outcomes of transcatheter pulmonary SAPIEN 3 valve implantation: an international registry. *Eur Heart J.* 2024;45:198-210.
28. Baumgartner H, de Backer J, Babu-Narayan SV, et al. 2020 ESC guidelines for the management of adult congenital heart disease. *Eur Heart J.* 2021;42:563-645.
29. Lim DS, Kim D, Aboulhosn J, et al. Congenital pulmonic valve dysfunction treated with SAPIEN 3 transcatheter heart valve (from the COMPASSION S3 Trial). *Am J Cardiol.* 2023;190:102-109.
30. Stefanescu Schmidt AC, Armstrong AK, Aboulhosn JA, et al. Transcatheter pulmonary valve replacement with balloon-expandable valves: utilization and procedural outcomes from the IMPACT registry. *JACC Cardiovasc Interv.* 2024;17:231-244.
31. Kenny D, Rhodes JF, Fleming GA, et al. 3-year outcomes of the Edwards SAPIEN transcatheter heart valve for conduit failure in the pulmonary position from the COMPASSION multicenter clinical trial. *JACC Cardiovasc Interv.* 2018;11:1920-1929.
32. Stout KK, Daniels CJ, Aboulhosn JA, et al. 2018 AHA/ACC guideline for the management of adults with congenital heart disease: a report of the American College of Cardiology/American Heart Association Task Force on Clinical Practice Guidelines. *J Am Coll Cardiol.* 2019;73:e81-e192.

#### 4.4.1.1. Patients With dextro-Transposition of the Great Arteries and Atrial Switch

1. Broberg CS, van Dissel A, Minnier J, et al. Long-term outcomes after atrial switch operation for

- transposition of the great arteries. *J Am Coll Cardiol*. 2022;80:951-963.
2. Surkova E, Constantine A, Xu Z, et al. Prognostic significance of subpulmonary left ventricular size and function in patients with a systemic right ventricle. *Eur Heart J Cardiovasc Imaging*. 2023;25:58-65.
3. Lewis MJ, Van Dissel A, Kochav J, et al. Cardiac MRI predictors of adverse outcomes in adults with a systemic right ventricle. *ESC Heart Fail*. 2022;9:834-841.
4. Giardini A, Hager A, Lammers AE, et al. Ventilatory efficiency and aerobic capacity predict event-free survival in adults with atrial repair for complete transposition of the great arteries. *J Am Coll Cardiol*. 2009;53:1548-1555.
5. Dimopoulos K, Okonko DO, Diller GP, et al. Abnormal ventilatory response to exercise in adults with congenital heart disease relates to cyanosis and predicts survival. *Circulation*. 2006;113:2796-2802.
6. Inuzuka R, Diller GP, Borgia F, et al. Comprehensive use of cardiopulmonary exercise testing identifies adults with congenital heart disease at increased mortality risk in the medium term. *Circulation*. 2012;125:250-259.
7. Jensen AS, Jorgensen TH, Christersson C, et al. Cause-specific mortality in patients during long-term follow-up after atrial switch for transposition of the great arteries. *J Am Heart Assoc*. 2022;11:e023921.
8. Stout KK, Broberg CS, Book WM, et al. Chronic heart failure in congenital heart disease: a scientific statement from the American Heart Association. *Circulation*. 2016;133:770-801.
9. Ross HJ, Law Y, Book WM, et al. Transplantation and mechanical circulatory support in congenital heart disease: a scientific statement from the American Heart Association. *Circulation*. 2016;133:802-820.
10. Gyoten T, Rojas SV, Fox H, et al. Mechanical circulatory support as a bridge to candidacy in adults with transposition of the great arteries and a systemic right ventricle. *Eur J Cardiothorac Surg*. 2020.
11. Emmel M, Sreeram N, Brockmeier K, Bennink G. Superior vena cava stenting and transvenous pacemaker implantation (stent and pace) after the Mustard operation. *Clin Res Cardiol*. 2007;96:17-22.
12. Gillette PC, Wampler DG, Shannon C, Ott D. Use of cardiac pacing after the Mustard operation for transposition of the great arteries. *J Am Coll Cardiol*. 1986;7:138-141.
13. De Pasquale G, Bonassin Tempesta F, Lopes BS, et al. High prevalence of baffle leaks in adults after atrial switch operations for transposition of the great arteries. *Eur Heart J Cardiovasc Imaging*. 2017;18:531-535.
14. Albertini M, Santens B, Fusco F, et al. External validation of a risk score model for predicting major clinical events in adults after atrial switch. *J Am Heart Assoc*. 2024;13:e032174.
15. Woudstra OI, Zandstra TE, Vogel RF, et al. Clinical course long after atrial switch: a novel risk score for major clinical events. *J Am Heart Assoc*. 2021;10:e018565.
16. Ladouceur M, Van De Bruaene A, Kauling R, et al. A new score for life-threatening ventricular arrhythmias and sudden cardiac death in adults with transposition of the great arteries and a systemic right ventricle. *Eur Heart J*. 2022;43:2685-2694.
17. Schwerzmann M, Salehian O, Harris L, et al. Ventricular arrhythmias and sudden death in adults after a Mustard operation for transposition of the great arteries. *Eur Heart J*. 2009;30:1873-1879.
18. Krause U, Teubener ST, Muller MJ, et al. Fate after the Mustard procedure for d-transposition of the great arteries: impact of age, complexity, and atrial tachyarrhythmias: a single center experience. *Pediatr Cardiol*. 2023;44:1746-1753.
19. Kammeraad JA, van Deurzen CH, Sreeram N, et al. Predictors of sudden cardiac death after Mustard or Senning repair for transposition of the great arteries. *J Am Coll Cardiol*. 2004;44:1095-1102.
20. Ernst S, Babu-Narayan SV, Keegan J, et al. Remote-controlled magnetic navigation and ablation with 3D image integration as an alternative approach in patients with intra-atrial baffle anatomy. *Circ Arrhythm Electrophysiol*. 2012;5:131-139.
21. Khairy P, Vo C. Robotic magnetic-guided retrograde aortic ablation of atrioventricular nodal reentrant tachycardia in transposition of the great arteries after atrial switch. *HeartRhythm Case Rep*. 2024;10:427-431.
22. Neijenhuis RML, Regeer MV, van der Kley F, et al. Contemporary management strategies of baffle leaks in adults with a failing systemic right ventricle late after atrial switch: a case series and literature overview. *J Cardiovasc Dev Dis*. 2023;10:129.
23. Bradley EA, Cai A, Cheatham SL, et al. Mustard baffle obstruction and leak - how successful are percutaneous interventions in adults? *Prog Pediatr Cardiol*. 2015;39:157-163.
24. Poterucha JT, Taggart NW, Johnson JN, et al. Intravascular and hybrid intraoperative stent placement for baffle obstruction in transposition of the great arteries after atrial switch. *Catheter Cardiovasc Interv*. 2017;89:306-314.
25. Michel E, Orozco Hernandez E, Enter D, et al. Bridge to transplantation with long-term mechanical assist devices in adults with transposition of the great arteries. *Artif Organs*. 2019;43:90-96.
26. Kharbanda RK, Moore JP, Lloyd MS, et al. Cardiac resynchronization therapy for adult patients with a failing systemic right ventricle: a multicenter study. *J Am Heart Assoc*. 2022;11:e025121.
27. Hayes CJ, Gersony WM. Arrhythmias after the Mustard operation for transposition of the great arteries: a long-term study. *J Am Coll Cardiol*. 1986;7:133-137.
28. Scognamiglio G, Fusco F, Hankel TC, et al. Safety and efficacy of non-vitamin K antagonist oral anticoagulants for prevention of thromboembolism in adults with systemic right ventricle: results from the NOTE international registry. *Int J Cardiol*. 2021;322:129-134.
29. Woudstra OI, Kuijpers JM, Jongbloed MRM, et al. Medication in adults after atrial switch for transposition of the great arteries: clinical practice and recommendations. *Eur Heart J Cardiovasc Pharmacother*. 2022;8:77-84.
30. Fusco F, Scognamiglio G, Abbate M, et al. Dapagliflozin in patients with a failing systemic right ventricle: results from the DAPA-SERVE trial. *JACC Heart Fail*. 2024;12:789-791.
31. Zandstra TE, Nederend M, Jongbloed MRM, et al. Sacubitril/valsartan in the treatment of systemic right ventricular failure. *Heart*. 2021;107:1725-1730.
32. Cohen MS, Eidem BW, Cetta F, et al. Multimodality imaging guidelines of patients with transposition of the great arteries: a report from the American Society of Echocardiography. Developed in collaboration with the Society for Cardiovascular Magnetic Resonance and the Society of Cardiovascular Computed Tomography. *J Am Soc Echocardiogr*. 2016;29:571-621.
33. Diller GP, Babu-Narayan S, Li W, et al. Utility of machine learning algorithms in assessing patients with a systemic right ventricle. *Eur Heart J Cardiovasc Imaging*. 2019;20:925-931.
34. Fusco F, Scognamiglio G, Sorice D, et al. Biventricular performance in adults with a systemic right ventricle: new insights from myocardial work analysis. *Int J Cardiovasc Imaging*. 2024;40:1067-1079.
35. Cifra B, Cordina RL, Gauthier N, et al. Cardiopulmonary exercise test interpretation across the lifespan in congenital heart disease: a scientific statement from the American Heart Association. *J Am Heart Assoc*. 2025:e038200.
36. Budts W, Pielles GE, Roos-Hesselin JW, et al. Recommendations for participation in competitive sport in adolescent and adult athletes with congenital heart disease (CHD): position statement of the sports cardiology & exercise section of the European Association of Preventive Cardiology (EAPC), the European Society of Cardiology (ESC) working group on adult congenital heart disease and the sports cardiology, physical activity and prevention working group of the Association for European Paediatric and Congenital Cardiology (AEPC). *Eur Heart J*. 2020;41:4191-4199.
37. Buys R, Van De Bruaene A, Budts W, et al. In adults with atrial switch operation for transposition of the great arteries low physical activity relates to reduced exercise capacity and decreased perceived physical functioning. *Acta Cardiol*. 2012;67:49-57.
38. Khairy P, Landzberg MJ, Gatzoulis MA, et al. Transvenous pacing leads and systemic thromboemboli in patients with intracardiac shunts: a multicenter study. *Circulation*. 2006;113:2391-2397.
39. Albertini L, Kawada S, Nair K, Harris L. Incidence and clinical predictors of early and late complications of implantable cardioverter-defibrillators in adults with congenital heart disease. *Can J Cardiol*. 2023;39:236-245.
40. Babu-Narayan SV, Goktekin O, Moon JC, et al. Late gadolinium enhancement cardiovascular magnetic resonance of the systemic right ventricle in adults with previous atrial redirection surgery for transposition of the great arteries. *Circulation*. 2005;111:2091-2098.
41. Vejstrup N, Sorensen K, Mattsson E, et al. Long-term outcome of mustard/senning correction for transposition of the great arteries in Sweden and Denmark. *Circulation*. 2015;132:633-638.
42. Kakarla J, Crossland DS, Murray S, et al. An unmet need: arrhythmia detection by implantable loop recorder in the systemic right ventricle. *Europace*. 2023;25:eua304.
43. Vehmeijer JT, Brouwer TF, Limpens J, et al. Implantable cardioverter-defibrillators in adults with congenital heart disease: a systematic review and meta-analysis. *Eur Heart J*. 2016;37:1439-1448.
44. Khairy P, Harris L, Landzberg MJ, et al. Sudden death and defibrillators in transposition of the great arteries with intra-atrial baffles: a multicenter study. *Circ Arrhythm Electrophysiol*. 2008;1:250-257.

45. Menachem JN, Golbus JR, Molina M, et al. Successful cardiac transplantation outcomes in patients with adult congenital heart disease. *Heart*. 2017;103:1449-1454.
46. Menachem JN, Swaminathan AC, Bashore TM, et al. Initial experience of left ventricular assist device support for adult patients with transposition of the great vessels. *Congenit Heart Dis*. 2015;10:382-386.
47. Maly J, Netuka I, Besik J, et al. Bridge to transplantation with long-term mechanical assist device in adults after the Mustard procedure. *J Heart Lung Transplant*. 2015;34:1177-1181.
48. Harper AR, Crossland DS, Perri G, et al. Is alternative cardiac surgery an option in adults with congenital heart disease referred for thoracic organ transplantation? *Eur J Cardiothorac Surg*. 2013;43:344-351.
49. Krishnathasan K, Dimopoulos K, Duncan N, et al. Advanced heart failure in adult congenital heart disease: the role of renal dysfunction in management and outcomes. *Eur J Prev Cardiol*. 2023;30:1335-1342.
50. Warnes CA. Transposition of the great arteries. *Circulation*. 2006;114:2699-2709.
51. Furuta A, Shinkawa T, Okugi S, et al. Tricuspid valve replacement provides better long-term survival and tricuspid valve function than repair in patients with systemic right ventricle. *JTCVS Open*. 2023;15:382-393.
52. Khairy P, Aboulhosn J, Broberg CS, et al. Thromboprophylaxis for atrial arrhythmias in congenital heart disease: a multicenter study. *Int J Cardiol*. 2016;223:729-735.
53. Yin Y, Dimopoulos K, Shimada E, et al. Early and late effects of cardiac resynchronization therapy in adult congenital heart disease. *J Am Heart Assoc*. 2019;8:e012744.
54. Ladouceur M, Segura de la Cal T, Gaye B, et al. Effect of medical treatment on heart failure incidence in patients with a systemic right ventricle. *Heart*. 2021;107:1384-1389.
55. Zaragoza-Macias E, Zaidi AN, Dendukuri N, Marelli A. Medical therapy for systemic right ventricles: a systematic review (part 1) for the 2018 AHA/ACC guideline for the management of adults with congenital heart disease: a report of the American College of Cardiology/American Heart Association Task Force on Clinical Practice Guidelines. *Circulation*. 2019;139:e801-e813.
56. Dore A, Houde C, Chan KL, et al. Angiotensin receptor blockade and exercise capacity in adults with systemic right ventricles: a multicenter, randomized, placebo-controlled clinical trial. *Circulation*. 2005;112:2411-2416.
57. Therrien J, Provost Y, Harrison J, et al. Effect of angiotensin receptor blockade on systemic right ventricular function and size: a small, randomized, placebo-controlled study. *Int J Cardiol*. 2008;129:187-192.
58. Robinson B, Heise CT, Moore JW, et al. Afterload reduction therapy in patients following intraatrial baffle operation for transposition of the great arteries. *Pediatr Cardiol*. 2002;23:618-623.
59. van der Bom T, Winter MM, Bouma BJ, et al. Effect of valsartan on systemic right ventricular function: a double-blind, randomized, placebo-controlled pilot trial. *Circulation*. 2013;127:322-330.
60. Misra A, Rodriguez-Monserrate CP, Gauvreau K, et al. Propensity score analysis of possible medication effects on outcomes in patients with systemic right ventricles. *JACC Adv*. 2025;4:101443.
61. Greutmann M, Tobler D, Engel R, et al. Effect of phosphodiesterase-5 inhibition on SystEmic Right VEtricular size and function - a multi-center, double-blind, randomized, placebo-controlled trial - SERVE. *Eur J Heart Fail*. 2023;25:1105-1114.
62. Fusco F, Scognamiglio G, Merola A, et al. Safety and efficacy of sacubitril/valsartan in patients with a failing systemic right ventricle: a prospective single-center study. *Circ Heart Fail*. 2023;16:e009848.
63. Stout KK, Daniels CJ, Aboulhosn JA, et al. 2018 AHA/ACC guideline for the management of adults with congenital heart disease: a report of the American College of Cardiology/American Heart Association Task Force on Clinical Practice Guidelines. *J Am Coll Cardiol*. 2019;73:e81-e192.

#### 4.4.1.2. Arterial Switch Operation

1. Fricke TA, Buratto E, Weintraub RG, et al. Long-term outcomes of the arterial switch operation. *J Thorac Cardiovasc Surg*. 2022;163:212-219.
2. Jacquemyn X, Van den Eynde J, Schuermans A, et al. Neo-aortic regurgitation detected by echocardiography after arterial switch operation: a systematic review and meta-analysis. *JACC Adv*. 2024;3:100878.
3. Lang SM, Crawford RL, Shivaram P, et al. Feasibility of transthoracic echocardiography evaluation of pulmonary arteries following arterial switch operation. *Pediatr Cardiol*. 2018;39:1523-1529.
4. Warmerdam EG, Westenberg JJM, Voskuil M, et al. Comparison of four-dimensional flow MRI, two-dimensional phase-contrast MRI and echocardiography in transposition of the great arteries. *Pediatr Cardiol*. 2024;45(8):1627-1635.
5. Noel CV, Krishnamurthy R, Masand P, et al. Myocardial stress perfusion MRI: experience in pediatric and young-adult patients following arterial switch operation utilizing regadenoson. *Pediatr Cardiol*. 2018;39:1249-1257.
6. Engele LJ, Mulder BJM, Schoones JW, et al. The coronary arteries in adults after the arterial switch operation: a systematic review. *J Cardiovasc Dev Dis*. 2021;8:102.
7. Batteux C, Abakka S, Gaudin R, et al. Three-dimensional geometry of coronary arteries after arterial switch operation for transposition of the great arteries and late coronary events. *J Thorac Cardiovasc Surg*. 2021;161:1396-1404.
8. Legendre A, Losay J, Touchot-Kone A, et al. Coronary events after arterial switch operation for transposition of the great arteries. *Circulation*. 2003;108(Suppl 1):II186-II190.
9. Ou P, Khraiche D, Celermajer DS, et al. Mechanisms of coronary complications after the arterial switch for transposition of the great arteries. *J Thorac Cardiovasc Surg*. 2013;145:1263-1269.
10. Lim RS, Lefkovits J, Menahem S. Long-term coronary artery complications following the arterial switch operation for transposition of the great arteries—a scoping review. *World J Pediatr Congenit Heart Surg*. 2025;21501351241311280.
11. Sengupta A, Carreon CK, Gauvreau K, et al. Growth of the neo-aortic root and prognosis of transposition

of the great arteries. *J Am Coll Cardiol*. 2024;83:516-527.

12. van der Palen RLF, van der Bom T, Dekker A, et al. Progression of aortic root dilatation and aortic valve regurgitation after the arterial switch operation. *Heart*. 2019;105:1732-1740.
13. Schuwerk R, Freitag-Wolf S, Krupickova S, et al. Ventricular and atrial function and deformation is largely preserved after arterial switch operation. *Heart*. 2021;107:1644-1650.
14. Devlin PJ, Jegatheeswaran A, Williams WG, et al. Late survival and patient-perceived health status of the Congenital Heart Surgeons' Society dextro-Transposition of the Great Arteries Cohort. *Ann Thorac Surg*. 2019;108:1447-1455.
15. Kiener A, Kelleman M, McCracken C, et al. Long-term survival after arterial versus atrial switch in d-Transposition of the great arteries. *Ann Thorac Surg*. 2018;106:1827-1833.
16. Broberg CS, van Dissel A, Minnier J, et al. Long-term outcomes after atrial switch operation for transposition of the great arteries. *J Am Coll Cardiol*. 2022;80:951-963.
17. Gaur L, Cedars A, Diller GP, et al. Management considerations in the adult with surgically modified d-transposition of the great arteries. *Heart*. 2021;107:1613-1619.
18. Kirzner J, Pirmohamed A, Ginns J, Singh HS. Long-term management of the arterial switch patient. *Curr Cardiol Rep*. 2018;20:68.
19. Santens B, Van De Bruene A, De Meester P, et al. Outcome of arterial switch operation for transposition of the great arteries. A 35-year follow-up study. *Int J Cardiol*. 2020;316:94-100.
20. Sobczak-Budlewska K, Łubisz M, Moll M, et al. 30 years' experience with the arterial switch operation: risk of pulmonary stenosis and its impact on post-operative prognosis. *Cardiol Young*. 2023;33:1550-1555.
21. Moe TG, Bardo DME. Long-term outcomes of the arterial switch operation for D-transposition of the great arteries. *Prog Cardiovasc Dis*. 2018;61:360-364.
22. Kasmi L, Calderon J, Montreuil M, et al. Neuro-cognitive and psychological outcomes in adults with dextro-transposition of the great arteries corrected by the arterial switch operation. *Ann Thorac Surg*. 2018;105:830-836.
23. Hovels-Gurich HH, Lebherz C, Korte B, et al. Socio-demographic parameters and non-cardiac comorbidity related to self-perceived quality of life in young adults after neonatal arterial switch operation for transposition of the great arteries. *Heart Vessels*. 2023;38:570-580.
24. Fedchenko M, Mandalenakis Z, Giang KW, et al. Long-term outcomes after myocardial infarction in middle-aged and older patients with congenital heart disease—a nationwide study. *Eur Heart J*. 2021;42:2577-2586.
25. Agarwal A, Thombly R, Broberg CS, et al. Age- and lesion-related comorbidity burden among US adults with congenital heart disease: a population-based study. *J Am Heart Assoc*. 2019;8:e013450.
26. Otto CM, Nishimura RA, Bonow RO, et al. 2020 ACC/AHA guideline for the management of patients with valvular heart disease: a report of the American College of Cardiology/American Heart Association

Joint Committee on Clinical Practice Guidelines. *J Am Coll Cardiol*. 2021;77:e25-e197.

27. Breinholt JP, John S. Management of the adult with arterial switch. *Methodist DeBakey Cardiovasc J*. 2019;15:133-137.

28. van der Palen RLF, Blom NA, Kuipers IM, et al. Long-term outcome after the arterial switch operation: 43 years of experience. *Eur J Cardiothorac Surg*. 2021;59:968-977.

29. Belhadjer Z, Soulat G, Ladouceur M, et al. Neopulmonary outflow tract obstruction assessment by 4D flow MRI in adults with transposition of the great arteries after arterial switch operation. *J Magn Reson Imaging*. 2020;51:1699-1705.

30. Marin Rodriguez C, Lancharro Zapata A, Rodriguez Ogando A, et al. [Quality of 3D magnetic resonance imaging of coronary arteries in patients with D-transposition of the great arteries after the Jatene switch procedure]. *Radiologia*. 2015;57:326-332.

31. Cohen MS, Eidem BW, Cetta F, et al. Multimodality imaging guidelines of patients with transposition of the great arteries: a report from the American Society of Echocardiography. Developed in collaboration with the Society for Cardiovascular Magnetic Resonance and the Society of Cardiovascular Computed Tomography. *J Am Soc Echocardiogr*. 2016;29:571-621.

32. Virani SS, Newby LK, Arnold SV, et al. 2023 AHA/ACC/ACCP/ASPC/NLA/PCNA guideline for the management of patients with chronic coronary disease: a report of the American Heart Association/American College of Cardiology Joint Committee on Clinical Practice Guidelines. *J Am Coll Cardiol*. 2023;82:833-955.

33. Koubský K, Gebauer R, Tláškal T, et al. Long-term survival and freedom from coronary artery reintervention after arterial switch operation for transposition of the great arteries: a population-based nationwide study. *J Am Heart Assoc*. 2021;10:e020479.

34. Wang SY, Zeng QY, Zhang L, et al. Impact of coronary artery anatomy in arterial switch operation: in-hospital and post-discharge outcomes. *Curr Med Sci*. 2022;42:642-649.

35. Morgan CT, Mertens L, Grotenhuis H, et al. Understanding the mechanism for branch pulmonary artery stenosis after the arterial switch operation for transposition of the great arteries. *Eur Heart J Cardiovasc Imaging*. 2017;18:180-185.

36. Alkattan HN, Diraneyya OM, Elmontaser HA, et al. The behavior of residual pulmonary artery gradient after arterial switch operation: a longitudinal data analysis. *J Card Surg*. 2020;35:2927-2933.

37. Miller S, Kozik D, Kurtz JD. Prevalence of branch pulmonary artery reintervention following the arterial switch operation. *World J Pediatr Congenit Heart Surg*. 2024;15:60-64.

38. Warmerdam EG, Magni F, Leiner T, et al. Echocardiography and MRI parameters associated with exercise capacity in patients after the arterial switch operation. *J Cardiol*. 2020;76:280-286.

39. Lee J, Abdullah Shahbah D, El-Said H, et al. Pulmonary artery interventions after the arterial switch operation: unique and significant risks. *Congenit Heart Dis*. 2019;14:288-296.

40. Joosen RS, Voskuil M, Krings GJ, et al. The impact of unilateral pulmonary artery stenosis on right

ventricular to pulmonary arterial coupling in patients with transposition of the great arteries. *Catheter Cardiovasc Interv*. 2024;103:943-948.

41. Ruckdeschel E, Kim YY. Pulmonary valve stenosis in the adult patient: pathophysiology, diagnosis and management. *Heart*. 2019;105:414-422.

42. Iannacone EM, Lau C Jr, Soletti G, et al. Aortic valve-sparing root replacement or Bentall? *Ann Cardiothorac Surg*. 2023;12:168-178.

43. Isselbacher EM, Preventza O, Hamilton Black III J, et al. 2022 ACC/AHA guideline for the diagnosis and management of aortic disease: a report of the American Heart Association/American College of Cardiology Joint Committee on Clinical Practice Guidelines. *J Am Coll Cardiol*. 2022;80:e223-e393.

44. Stout KK, Daniels CJ, Aboulhosn JA, et al. 2018 AHA/ACC guideline for the management of adults with congenital heart disease: a report of the American College of Cardiology/American Heart Association Task Force on Clinical Practice Guidelines. *J Am Coll Cardiol*. 2019;73:e81-e192.

#### 4.4.1.3. Patients With d-TGA and Rastelli Repair

1. Kreutzer C, De Vive J, Oppido G, et al. Twenty-five-year experience with rastelli repair for transposition of the great arteries. *J Thorac Cardiovasc Surg*. 2000;120:211-223.

2. Egbe AC, Miranda WR, Stephens EH, et al. Right ventricular systolic dysfunction in adults with anatomic repair of d-transposition of great arteries. *Am J Cardiol*. 2023;192:101-108.

3. Furuta A, Yamagishi M, Matsumura G, et al. Long-term surgical results of transposition of the great arteries with left ventricular outflow tract obstruction. *J Cardiothorac Surg*. 2022;17:111.

4. Rastelli GC, Ongley PA, Davis GD, Kirklin JW. Surgical repair for pulmonary valve atresia with coronary-pulmonary artery fistula: report of case. *Mayo Clin Proc*. 1965;40:521-527.

5. Rastelli GC, McGoon DC, Wallace RB. Anatomic correction of transposition of the great arteries with ventricular septal defect and subpulmonary stenosis. *J Thorac Cardiovasc Surg*. 1969;58:545-552.

6. Brown JW, Ruzmetov M, Huynh D, et al. Rastelli operation for transposition of the great arteries with ventricular septal defect and pulmonary stenosis. *Ann Thorac Surg*. 2011;91:188-193. discussion 193-194.

7. Horer J, Schreiber C, Dworak E, et al. Long-term results after the Rastelli repair for transposition of the great arteries. *Ann Thorac Surg*. 2007;83:2169-2175.

8. Villemin O, Belli E, Ladouceur M, et al. Impact of anatomic characteristics and initial biventricular surgical strategy on outcomes in various forms of double-outlet right ventricle. *J Thorac Cardiovasc Surg*. 2016;152:698-706.e3.

9. Weixler V, Gaal J, Murin P, et al. Repair of complex transposition of great arteries: what is the best technique to avoid outflow tract obstructions? *Eur J Cardiothorac Surg*. 2024;65:ezae094.

10. Dearani JA, Danielson GK, Puga FJ, et al. Late follow-up of 1095 patients undergoing operation for complex congenital heart disease utilizing pulmonary ventricle to pulmonary artery conduits. *Ann Thorac Surg*. 2003;75:399-410. ; discussion 410-411.

11. Liu R, Li S, Yan J, et al. Fate of transposition of the great arteries with pulmonary stenosis after double-

root translocation, Rastelli, and Réparation à l'Étage Ventriculaire. *J Thorac Cardiovasc Surg*. 2023;166:1189-1199.e4.

12. Patloori SCS, Kawada S, Chakraborty P, et al. Arrhythmias in adult patients after Rastelli surgery: a single-centre experience. *Cardiol Young*. 2024:1-5.

13. Hazekamp MG, Neuvzhay T, Sojak V, Nikaidoh vs réparation à l'etage ventriculaire vs Rastelli. *Semin Thorac Cardiovasc Surg Pediatr Card Surg Annu*. 2018;21:58-63.

14. Nikaidoh H. Aortic translocation and biventricular outflow tract reconstruction. A new surgical repair for transposition of the great arteries associated with ventricular septal defect and pulmonary stenosis. *J Thorac Cardiovasc Surg*. 1984;88:365-372.

15. Seese L, Castrillon CD, Da Silva LDF, et al. Optimizing surgical selection for transposition with left ventricular outflow tract obstruction. *Ann Thorac Surg*. 2024;117:370-377.

16. Kari FA, Bohnens H, Bierbach B, et al. Repair of complex transposition of great arteries: up to 30 years of follow-up. *Ann Thorac Surg*. 2020;109:555-565.

17. An K, Li S, Yan J, Wang X, Hua Z. Transposition of the great arteries, ventricular septal defect, and pulmonary stenosis: modified REV versus rastelli. *Pediatr Cardiol*. 2021;42:762-767.

18. Lecompte Y, Neveux JY, Leca F, et al. Reconstruction of the pulmonary outflow tract without prosthetic conduit. *J Thorac Cardiovasc Surg*. 1982;84:727-733.

19. Seese L, Turbendian HK, Thibault D, et al. Utilization and outcomes of the Nikaidoh, rastelli, and REV procedures: an analysis of The Society of Thoracic Surgeons Congenital Heart Surgery Database. *Ann Thorac Surg*. 2022;114:800-808.

20. Cohen MS, Eidem BW, Cetta F, et al. Multimodality imaging guidelines of patients with transposition of the great arteries: a report from the American Society of Echocardiography. Developed in collaboration with the Society for Cardiovascular Magnetic Resonance and the Society of Cardiovascular Computed Tomography. *J Am Soc Echocardiogr*. 2016;29:571-621.

21. McElhinney DB, Benson LN, Eicken A, et al. Infective endocarditis after transcatheter pulmonary valve replacement using the Melody valve: combined results of 3 prospective North American and European studies. *Circ Cardiovasc Interv*. 2013;6:292-300.

22. Abdelghani M, Nassif M, Blom NA, et al. Infective endocarditis after melody valve implantation in the pulmonary position: a systematic review. *J Am Heart Assoc*. 2018;7:e008163.

23. Malekzadeh-Milani S, Ladouceur M, Patel M, et al. Incidence and predictors of Melody(R) valve endocarditis: a prospective study. *Arch Cardiovasc Dis*. 2015;108:97-106.

#### 4.4.2. Management of CCTGA

1. Egbe AC, Miranda WR, Connolly HM. Role of echocardiography for assessment of cardiac remodeling in congenitally corrected transposition of great arteries. *Circ Cardiovasc Imaging*. 2022;15:e013477.

2. Diller GP, Radojevic J, Kempny A, et al. Systemic right ventricular longitudinal strain is reduced in adults with transposition of the great arteries, relates to subpulmonary ventricular function, and predicts

adverse clinical outcome. *Am Heart J.* 2012;163:859-866.

3. Egbe AC, Miranda WR, Jain CC, Connolly HM. Prognostic implications of progressive systemic ventricular dysfunction in congenitally corrected transposition of great arteries. *JACC Cardiovasc Imaging.* 2022;15:566-574.

4. Grewal J, Crean A, Garceau P, et al. Subaortic right ventricular characteristics and relationship to exercise capacity in congenitally corrected transposition of the great arteries. *J Am Soc Echocardiogr.* 2012;25:1215-1221.

5. Diller GP, Okonko D, Uebing A, et al. Cardiac resynchronization therapy for adult congenital heart disease patients with a systemic right ventricle: analysis of feasibility and review of early experience. *Eurpace.* 2006;8:267-272.

6. El Assaad I, Burke BJ, Cummins K, et al. Arrhythmia burden in congenitally corrected transposition of the great arteries: does treatment pathway matter? *Heart Rhythm.* 2025;22(12):3300-3307.

7. Tseng WC, Huang CN, Chiu SN, et al. Long-term outcomes of arrhythmia and distinct electrophysiological features in congenitally corrected transposition of the great arteries in an Asian cohort. *Am Heart J.* 2021;231:73-81.

8. Abdelrehim AA, Stephens EH, Miranda WR, et al. Systemic atrioventricular valve surgery in patients with congenitally corrected transposition of the great vessels. *J Am Coll Cardiol.* 2023;82:2197-2208.

9. Egbe AC, Miranda WR, Katta RR, et al. Determinants of aerobic capacity after tricuspid valve replacement in congenitally corrected transposition of great arteries. *JACC Adv.* 2022;1:100027.

10. Hofferberth SC, Alexander ME, Mah DY, et al. Impact of pacing on systemic ventricular function in L-transposition of the great arteries. *J Thorac Cardiovasc Surg.* 2016;151:131-138.

11. Andi K, Abozied O, Miranda WR, et al. Clinical benefits of angiotensin receptor-nephrilysin inhibitor in adults with congenital heart disease. *Int J Cardiol.* 2023;387:131152.

12. Zandstra TE, Nederend M, Jongbloed MRM, et al. Sacubitril/valsartan in the treatment of systemic right ventricular failure. *Heart.* 2021;107:1725-1730.

13. Buber J, McElhinney DB, Valente AM, et al. Tricuspid valve regurgitation in congenitally corrected transposition of the great arteries and a left ventricle to pulmonary artery conduit. *Ann Thorac Surg.* 2015;99:1348-1356.

14. Van Praagh R, Papagiannis J, Grunenfelder J, et al. Pathologic anatomy of corrected transposition of the great arteries: medical and surgical implications. *Am Heart J.* 1998;135:772-785.

15. Barrios PA, Zia A, Pettersson G, et al. Outcomes of treatment pathways in 240 patients with congenitally corrected transposition of great arteries. *J Thorac Cardiovasc Surg.* 2021;161:1080-1093.e4.

16. Winter MM, van der Plas MN, Bouma BJ, et al. Mechanisms for cardiac output augmentation in patients with a systemic right ventricle. *Int J Cardiol.* 2010;143:141-146.

17. Iriart X, Le Quellenec S, Pillois X, et al. Heart rate response during exercise predicts exercise tolerance in adults with transposition of the great arteries and

atrial switch operation. *Int J Cardiol.* 2020;299:116-122.

18. Winter MM, van der Bom T, de Vries LC, et al. Exercise training improves exercise capacity in adult patients with a systemic right ventricle: a randomized clinical trial. *Eur Heart J.* 2012;33:1378-1385.

19. Stout KK, Daniels CJ, Aboulhosn JA, et al. 2018 AHA/ACC guideline for the management of adults with congenital heart disease: a report of the American College of Cardiology/American Heart Association Task Force on Clinical Practice Guidelines. *J Am Coll Cardiol.* 2019;73:e81-e192.

#### 4.4.3. Truncus Arteriosus

1. Hrfi A, Ismail M, Mohammed MHA, et al. Outcome of truncus arteriosus repair: 20 years of single-center experience comparing early versus late surgical repair. *Cardiol Young.* 2022;32:1289-1295.

2. Naimo PS, Konstantinov IE. Surgery for truncus arteriosus: contemporary practice. *Ann Thorac Surg.* 2021;111:1442-1450.

3. Naimo PS, Bell D, Fricke TA, et al. Truncus arteriosus repair: a 40-year multicenter perspective. *J Thorac Cardiovasc Surg.* 2020;15:S0022-5223.

4. Guariento A, Doulamis IP, Staffa SJ, et al. Long-term outcomes of truncus arteriosus repair: A modulated renewal competing risks analysis. *J Thorac Cardiovasc Surg.* 2022;163:224-236.e226.

5. McElhinney DB, Driscoll DA, Emanuel BS, Goldmuntz E. Chromosome 22q11 deletion in patients with truncus arteriosus. *Pediatr Cardiol.* 2003;24:569-573.

6. Naimo PS, Fricke TA, Yong MS, et al. Outcomes of truncus arteriosus repair in children: 35 Years of experience from a single institution. *Semin Thorac Cardiovasc Surg.* 2016;28:500-511.

#### 4.4.4. Double-Outlet Right Ventricle

1. Yim D, Dragulescu A, Ide H, et al. Essential modifiers of double outlet right ventricle: revisit with endocardial surface images and 3-dimensional print models. *Circ Cardiovasc Imaging.* 2018;11:e006891.

2. Stoica S, Kreuzer M, Dorobantu DM, et al. Aortic root translocation and en bloc rotation of the outflow tracts surgery for complex forms of transposition of the great arteries and double outlet right ventricle: a multicenter study. *J Thorac Cardiovasc Surg.* 2022;164:1249-1260.

3. Li S, Ma K, Hu S, et al. Surgical outcomes of 380 patients with double outlet right ventricle who underwent biventricular repair. *J Thorac Cardiovasc Surg.* 2014;148:817-824.

4. Vigil C, Lasso A, Ghosh RM, et al. Modeling tool for rapid virtual planning of the intracardiac baffle in double-outlet right ventricle. *Ann Thorac Surg.* 2021;111:2078-2083.

#### 4.4.5. Fontan Palliation of Single-Ventricle

##### Physiology

1. Lewis MJ, Reardon LC, Aboulhosn J, et al. Morbidity and mortality in adult Fontan patients after heart or combined heart-liver transplantation. *J Am Coll Cardiol.* 2023;81:2161-2171.

2. Berg CJ, Bauer BS, Hageman A, et al. Mortality risk stratification in Fontan patients who underwent heart transplantation. *Am J Cardiol.* 2017;119:1675-1679.

3. Kim YY, Lluri G, Haeffele C, et al. Hepatocellular carcinoma in survivors after Fontan operation: a case-control study. *Eur Heart J.* 2024;45:1477-1480.

4. Nii M, Inuzuka R, Inai K, et al. Incidence and expected probability of liver cirrhosis and hepatocellular carcinoma after Fontan operation. *Circulation.* 2021;144:2043-2045.

5. Surrey LF, Russo P, Rychik J, et al. Prevalence and characterization of fibrosis in surveillance liver biopsies of patients with Fontan circulation. *Hum Pathol.* 2016;57:106-115.

6. Zaidi SJ, Penk J, Schweig L, et al. Added value of live 3-dimensional transesophageal echocardiography during procedures in Fontan patients. *Pediatr Cardiol.* 2020;41:1370-1375.

7. Egbe AC, Connolly HM, McLeod CJ, et al. Thrombotic and embolic complications associated with atrial arrhythmia after Fontan operation: role of prophylactic therapy. *J Am Coll Cardiol.* 2016;68:1312-1319.

8. Van den Eynde J, Possner M, Alahdab F, et al. Thromboprophylaxis in patients with Fontan circulation. *J Am Coll Cardiol.* 2023;81:374-389.

9. Kawamatsu N, Ishizu T, Machino-Ohtsuka T, et al. Direct oral anticoagulant use and outcomes in adult patients with Fontan circulation: a multicenter retrospective cohort study. *Int J Cardiol.* 2021;327:74-79.

10. Poh CL, Celermajer DS, Grigg LE, et al. Pacemakers are associated with a higher risk of late death and transplantation in the Fontan population. *Int J Cardiol.* 2019;282:33-37.

11. Egbe AC, Connolly HM, Niaz T, McLeod CJ. Outcome of direct current cardioversion for atrial arrhythmia in adult Fontan patients. *Int J Cardiol.* 2016;208:115-119.

12. Kodama Y, Kuraoka A, Ishikawa Y, et al. Outcome of patients with functional single ventricular heart after pacemaker implantation: what makes it poor, and what can we do? *Heart Rhythm.* 2019;16:1870-1874.

13. Chubb H, Bulic A, Mah D, et al. Impact and modifiers of ventricular pacing in patients with single ventricle circulation. *J Am Coll Cardiol.* 2022;80:902-914.

14. Scheffers LE, Helbing WA, Pereira T, et al. Leg-focused high-weight resistance training improves ventricular stroke volume, exercise capacity and strength in young patients with a Fontan circulation. *Eur J Prev Cardiol.* 2024;31:389-399.

15. Turquetto ALR, Dos Santos MR, Agostinho DR, et al. Aerobic exercise and inspiratory muscle training increase functional capacity in patients with univentricular physiology after Fontan operation: a randomized controlled trial. *Int J Cardiol.* 2021;330:50-58.

16. Moore JP, Shannon KM, Fish FA, et al. Catheter ablation of supraventricular tachyarrhythmia after extracardiac Fontan surgery. *Heart Rhythm.* 2016;13:1891-1897.

17. Moore BM, Anderson R, Nisbet AM, et al. Ablation of atrial arrhythmias after the atriopulmonary Fontan procedure: mechanisms of arrhythmia and outcomes. *JACC Clin Electrophysiol.* 2018;4:1338-1346.

18. Goldberg DJ, Zak V, Goldstein BH, et al. Results of the FUEL trial. *Circulation.* 2020;141:641-651.

19. Hebert A, Mikkelsen UR, Thilen U, et al. Bosentan improves exercise capacity in adolescents and adults after Fontan operation: the TEMPO (Treatment With Endothelin Receptor Antagonist in Fontan Patients, a Randomized, Placebo-Controlled, Double-Blind Study Measuring Peak Oxygen Consumption) study. *Circulation*. 2014;130:2021-2030.
20. Mavroudis C, Deal BJ, Backer CL, et al. Maxwell Chamberlain Memorial Paper for congenital heart surgery. 111 Fontan conversions with arrhythmia surgery: surgical lessons and outcomes. *Ann Thorac Surg*. 2007;84:1457-1465; discussion 1465-1466.
21. Poh CL, Cochrane A, Galati JC, et al. Ten-year outcomes of Fontan conversion in Australia and New Zealand demonstrate the superiority of a strategy of early conversion. *Eur J Cardiothorac Surg*. 2016;49:530-535. discussion 535.
22. Book WM, Gerardin J, Saraf A, et al. Clinical phenotypes of Fontan failure: implications for management. *Congenit Heart Dis*. 2016;11:296-308.
23. Alsaied T, Rathod RH, Aboulhosn JA, et al. Reaching consensus for unified medical language in Fontan care. *ESC Heart Fail*. 2021;8:3894-3905.
24. Schumacher KR, Cedars A, Allen K, et al. Achieving consensus: severity-graded definitions of Fontan-associated complications to characterize Fontan circulatory failure. *J Card Fail*. 2024;30:1595-1603.
25. Griffeth EM, Burchill LJ, Dearani JA, et al. Optimizing referral timing of patients with Fontan circulatory failure for heart transplant. *Transplant Proc*. 2023;55:417-425.
26. Lubert AM, Cedars A, Almond CS, et al. Considerations for advanced heart failure consultation in individuals with Fontan circulation: recommendations from ACTION. *Heart*. 2023;16(2):e010123.
27. Alsaied T, Possner M, Lubert AM, et al. Relation of magnetic resonance elastography to Fontan failure and portal hypertension. *Am J Cardiol*. 2019;124:1454-1459.
28. Goldberg DJ, Surrey LF, Glatz AC, et al. Hepatic fibrosis is universal following Fontan operation, and severity is associated with time from surgery: a liver biopsy and hemodynamic study. *J Am Heart Assoc*. 2017;6:e004809.
29. Ohuchi H, Hayama Y, Nakajima K, et al. Incidence, predictors, and mortality in patients with liver cancer after Fontan operation. *J Am Heart Assoc*. 2021;10:e016617.
30. Possner M, Gordon-Walker T, Egbe AC, et al. Hepatocellular carcinoma and the Fontan circulation: clinical presentation and outcomes. *Int J Cardiol*. 2021;322:142-148.
31. Tellez L, Rodriguez de Santiago E, Minguez B, et al. Prevalence, features and predictive factors of liver nodules in Fontan surgery patients: the VALDIG Fontliver prospective cohort. *J Hepatol*. 2020;72:702-710.
32. Silva-Sepulveda JA, Fonseca Y, Vodkin I, et al. Evaluation of Fontan liver disease: correlation of transjugular liver biopsy with magnetic resonance and hemodynamics. *Congenit Heart Dis*. 2019;14:600-608.
33. Serai SD, Tsiou Y, Wilkins BJ, et al. MR elastography-based staging of liver fibrosis in Fontan procedure associated liver disease is confounded by effects of venous congestion. *Clin Radiol*. 2022;77:e776-e782.
34. Gatzoulis MA, Munk MD, Williams WG, Webb GD. Definitive palliation with cavopulmonary or aortopulmonary shunts for adults with single ventricle physiology. *Heart*. 2000;83:51-57.
35. Deshaies C, Hamilton RM, Shohoudi A, et al. Thromboembolic risk after atriopulmonary, lateral tunnel, and extracardiac conduit Fontan surgery. *J Am Coll Cardiol*. 2019;74:1071-1081.
36. Stephenson EA, Lu M, Berul CI, et al. Arrhythmias in a contemporary Fontan cohort: prevalence and clinical associations in a multicenter cross-sectional study. *J Am Coll Cardiol*. 2010;56:890-896.
37. Balling G, Vogt M, Kaemmerer H, et al. Intracardiac thrombus formation after the Fontan operation. *J Thorac Cardiovasc Surg*. 2000;119:745-752.
38. Fyfe DA, Kline CH, Sade RM, Gillette PC. Transesophageal echocardiography detects thrombus formation not identified by transthoracic echocardiography after the Fontan operation. *J Am Coll Cardiol*. 1991;18:1733-1737.
39. Sandler KL, Markham LW, Mah ML, et al. Optimizing CT angiography in patients with Fontan physiology: single-center experience of dual-site power injection. *Clin Radiol*. 2014;69:e562-e567.
40. Boggs R, Dibert T, Co-Vu J, et al. Optimized computed tomography angiography protocol for the evaluation of thrombus in patients with Fontan anatomy. *Pediatr Cardiol*. 2020;41:1601-1607.
41. Opatowsky AR, Carazo M, Singh MN, et al. Creatinine versus cystatin C to estimate glomerular filtration rate in adults with congenital heart disease: results of the Boston Adult Congenital Heart Disease Biobank. *Am Heart J*. 2019;214:142-155.
42. Van Hassel G, Rivrud SCS, Timmerman FJ, et al. Iron deficiency in patients with a Fontan circulation and its impact on exercise capacity. *Open Heart*. 2024;11:e002693.
43. Munsterman ID, Duijnhouwer AL, Kendall TJ, et al. The clinical spectrum of Fontan-associated liver disease: results from a prospective multimodality screening cohort. *Eur Heart J*. 2019;40:1057-1068.
44. Vaikunth SS, Higgins JP, Concepcion W, et al. Does liver biopsy accurately measure fibrosis in Fontan-associated liver disease? A comparison of liver biopsy pre-combined heart and liver transplant and liver explant post-transplant. *Clin Transplant*. 2020;34:e14120.
45. Egbe AC, Connolly HM, Niaz T, et al. Prevalence and outcome of thrombotic and embolic complications in adults after Fontan operation. *Am Heart J*. 2017;183:10-17.
46. Pessotti CF, Jatene MB, Jatene IB, et al. Comparative trial of the use of antiplatelet and oral anticoagulant in thrombosis prophylaxis in patients undergoing total cavopulmonary operation with extracardiac conduit: echocardiographic, tomographic, scintigraphic, clinical and laboratory analysis. *Rev Bras Cir Cardiovasc*. 2014;29:595-605.
47. Konstantinov IE, Puga FJ, Alexi-Meskishvili VV. Thrombosis of intracardiac or extracardiac conduits after modified Fontan operation in patients with azygous continuation of the inferior vena cava. *Ann Thorac Surg*. 2001;72:1641-1644.
48. Yang H, Veldtman GR, Bouma BJ, et al. Non-vitamin K antagonist oral anticoagulants in adults with a Fontan circulation: are they safe. *Open Heart*. 2019;6:e000985.
49. Ankola AA, Anderson BR, Choudhury TA, et al. Early thromboprophylaxis initiation is associated with reduced Fontan thromboses in the early postoperative period. *Semin Thorac Cardiovasc Surg*. 2021;33:806-813.
50. Alsaied T, Alsidawi S, Allen CC, et al. Strategies for thromboprophylaxis in Fontan circulation: a meta-analysis. *Heart*. 2015;101:1731-1737.
51. Iyengar AJ, Winlaw DS, Galati JC, et al. No difference between aspirin and warfarin after extracardiac Fontan in a propensity score analysis of 475 patients. *Eur J Cardiothorac Surg*. 2016;50:980-987.
52. Al-Jazairi AS, Al Alshaykh HA, Di Salvo G, et al. Assessment of late thromboembolic complications post-fontan procedure in relation to different antithrombotic regimens: 30-years' follow-up experience. *Ann Pharmacother*. 2019;53:786-793.
53. Ohuchi H, Yasuda K, Miyazaki A, et al. Prevalence and predictors of haemostatic complications in 412 Fontan patients: their relation to anticoagulation and haemodynamics. *Eur J Cardiothorac Surg*. 2015;47:511-519.
54. Assaad IE, Pastor T, O'Leary E, et al. Atrial pacing in Fontan patients: the effect of transvenous lead on clot burden. *Heart Rhythm*. 2021;18:1860-1867.
55. Kochav JD, Rosenbaum M, Kochav SM, et al. Effect of ventricular pacing on morbidity in adults after Fontan repair. *Am J Cardiol*. 2020;125:1263-1269.
56. Egbe AC, Huntley GD, Connolly HM, et al. Outcomes of cardiac pacing in adult patients after a Fontan operation. *Am Heart J*. 2017;194:92-98.
57. Poh CL, d'Udekem Y. Life after surviving Fontan surgery: a meta-analysis of the incidence and predictors of late death. *Heart Lung Circ*. 2018;27:552-559.
58. Cohen MI, Wernovsky G, Vetter VL, et al. Sinus node function after a systematically staged Fontan procedure. *Circulation*. 1998;98:II352-358; discussion II358-359.
59. Khairy P, Fernandes SM, Mayer JE Jr, et al. Long-term survival, modes of death, and predictors of mortality in patients with Fontan surgery. *Circulation*. 2008;117:85-92.
60. Giannakoulas G, Dimopoulos K, Yuksel S, et al. Atrial tachyarrhythmias late after Fontan operation are related to increase in mortality and hospitalization. *Int J Cardiol*. 2012;157:221-226.
61. Lin JH, Kean AC, Cordes TM. The risk of thromboembolic complications in Fontan patients with atrial flutter/fibrillation treated with electrical cardioversion. *Pediatr Cardiol*. 2016;37:1351-1360.
62. Yousef N, Philips M, Shetty I, et al. Transesophageal echocardiography of intracardiac thrombus in congenital heart disease and atrial flutter: the importance of thorough examination of the Fontan. *Pediatr Cardiol*. 2014;35:1099-1107.
63. Reardon LC, DePasquale EC, Tarabay J, et al. Heart and heart-liver transplantation in adults with failing Fontan physiology. *Clin Transplant*. 2018;32:e13329.

- 64.** Sganga D, Hollander SA, Vaikunth S, et al. Comparison of combined heart–liver vs heart-only transplantation in pediatric and young adult Fontan recipients. *J Heart Lung Transplant.* 2021;40:298-306.
- 65.** Vaikunth SS, Ortega-Legaspi JM, Conrad DR, et al. Mortality and morbidity after combined heart and liver transplantation in the failing Fontan: an updated dual center retrospective study. *Clin Transplant.* 2024;38:e15302.
- 66.** O’Leary ET, Gauvreau K, Alexander ME, et al. Dual-site ventricular pacing in patients with Fontan physiology and heart block: does it mitigate the detrimental effects of single-site ventricular pacing? *JACC Clin Electrophysiol.* 2018;4:1289-1297.
- 67.** Sutherland N, Jones B, d’Udekem Y. Should we recommend exercise after the Fontan procedure? *Heart Lung Circ.* 2015;24:753-768.
- 68.** Cordina RL, O’Meagher S, Karmali A, et al. Resistance training improves cardiac output, exercise capacity and tolerance to positive airway pressure in Fontan physiology. *Int J Cardiol.* 2013;168:780-788.
- 69.** Scheffers LE, Berg L, Ismailova G, et al. Physical exercise training in patients with a Fontan circulation: a systematic review. *Eur J Prev Cardiol.* 2021;28:1269-1278.
- 70.** Kawada S, Chakraborty P, Roche L, et al. Role of amiodarone in the management of atrial arrhythmias in adult Fontan patients. *Heart.* 2021;107:1062-1068.
- 71.** Khairy P, Van Hare GF, Balaji S, et al. PACES/HRS expert consensus statement on the recognition and management of arrhythmias in adult congenital heart disease: developed in partnership between the Pediatric and Congenital Electrophysiology Society (PACES) and the Heart Rhythm Society (HRS). *Can J Cardiol.* 2014;30:e1-e63.
- 72.** Agasthi P, Jain CC, Egbe AC, et al. Clinical outcomes of percutaneous Fontan stenting in adults. *Can J Cardiol.* 2023;39:1358-1365.
- 73.** Hagler DJ, Miranda WR, Haggerty BJ, et al. Fate of the Fontan connection: mechanisms of stenosis and management. *Congenit Heart Dis.* 2019;14:571-581.
- 74.** Kavin U, Shahrier A, Bandisode VM, et al. Fontan conduit stent-angioplasty and progression of Fontan-associated liver disease. *Pediatr Cardiol.* 2024;46:372-378.
- 75.** Ovroutski S, Ewert P, Alexi-Meskishvili V, et al. Dilatation and stenting of the Fontan pathway: impact of the stenosis treatment on chronic ascites. *J Interv Cardiol.* 2008;21:38-43.
- 76.** Dori Y, Glatz AC, Hanna BD, et al. Acute effects of embolizing systemic-to-pulmonary arterial collaterals on blood flow in patients with superior cavopulmonary connections: a pilot study. *Circ Cardiovasc Interv.* 2013;6:101-106.
- 77.** Tan W, Small A, Gallotti R, et al. Peripheral venous pressure accurately predicts central venous pressure in the adult Fontan circulation. *Int J Cardiol.* 2021;326:77-80.
- 78.** Krishnan US, Lamour JM, Hsu DT, et al. Management of aortopulmonary collaterals in children following cardiac transplantation for complex congenital heart disease. *J Heart Lung Transplant.* 2004;23:564-569.
- 79.** Goldberg DJ, Zak V, Goldstein BH, et al. Results of the FUEL Trial. *Circulation.* 2020;141:641-651.
- 80.** Goldberg DJ, French B, McBride MG, et al. Impact of oral sildenafil on exercise performance in children and young adults after the Fontan operation: a randomized, double-blind, placebo-controlled, crossover trial. *Circulation.* 2011;123:1185-1193.
- 81.** Cedars AM, Saef J, Peterson LR, et al. Effect of ambrisentan on exercise capacity in adult patients after the Fontan procedure. *Am J Cardiol.* 2016;117:1524-1532.
- 82.** Mori H, Park IS, Yamagishi H, et al. Sildenafil reduces pulmonary vascular resistance in single ventricular physiology. *Int J Cardiol.* 2016;221:122-127.
- 83.** Giardini A, Balducci A, Specchia S, et al. Effect of sildenafil on haemodynamic response to exercise and exercise capacity in Fontan patients. *Eur Heart J.* 2008;29:1681-1687.
- 84.** Deal BJ, Mavroudis C, Backer CL, et al. Comparison of anatomic isthmus block with the modified right atrial maze procedure for late atrial tachycardia in Fontan patients. *Circulation.* 2002;106:575-579.
- 85.** Hiramatsu T, Iwata Y, Matsumura G, et al. Impact of Fontan conversion with arrhythmia surgery and pacemaker therapy. *Eur J Cardiothorac Surg.* 2011;40:1007-1010.
- 86.** Weinstein S, Cua C, Chan D, Davis JT. Outcome of symptomatic patients undergoing extracardiac Fontan conversion and cryoablation. *J Thorac Cardiovasc Surg.* 2003;126:529-536.
- 87.** Said SM, Burkhart HM, Schaff HV, et al. Fontan conversion: identifying the high-risk patient. *Ann Thorac Surg.* 2014;97:2115-2121; discussion 2121-2122.
- 88.** King G, Ayer J, Celermajer D, et al. Atrioventricular valve failure in Fontan palliation. *J Am Coll Cardiol.* 2019;73:810-822.
- 89.** Sugimoto K, Hirata Y, Hirahara N, et al. Mid-term result of atrioventricular valve replacement in patients with a single ventricle. *Interact Cardiovasc Thorac Surg.* 2018;27:895-900.
- 90.** Liu VJ, Yong MS, d’Udekem Y, et al. Outcomes of atrioventricular valve operation in patients with Fontan circulation. *Ann Thorac Surg.* 2015;99:1632-1638.
- 91.** Menon SC, Dearani JA, Cetta F. Long-term outcome after atrioventricular valve surgery following modified Fontan operation. *Cardiol Young.* 2011;21:83-88.
- 92.** Stout KK, Daniels CJ, Aboulhosn JA, et al. 2018 AHA/ACC guideline for the management of adults with congenital heart disease: a report of the American College of Cardiology/American Heart Association Task Force on Clinical Practice Guidelines. *J Am Coll Cardiol.* 2019;73:e81-e192.

#### 4.4.5.1. HLHS/Norwood Repair

- 1.** d’Udekem Y, Iyengar AJ, Galati JC, et al. Redefining expectations of long-term survival after the Fontan procedure: twenty-five years of follow-up from the entire population of Australia and New Zealand. *Circulation.* 2014;130:S32-S38.
- 2.** King G, Ayer J, Celermajer D, et al. Atrioventricular valve failure in Fontan palliation. *J Am Coll Cardiol.* 2019;73:810-822.
- 3.** Newburger JW, Sleeper LA, Bellinger DC, et al. Early developmental outcome in children with hypoplastic left heart syndrome and related anomalies: the single ventricle reconstruction trial. *Circulation.* 2012;125:2081-2091.

#### 4.4.6. Eisenmenger Syndrome

- 1.** D’Alto M, Romeo E, Argiento P, et al. Hemodynamics of patients developing pulmonary arterial hypertension after shunt closure. *Int J Cardiol.* 2013;168:3797-3801.
- 2.** Lowe BS, Therrien J, Ionescu-Iltu R, et al. Diagnosis of pulmonary hypertension in the congenital heart disease adult population impact on outcomes. *J Am Coll Cardiol.* 2011;58:538-546.
- 3.** Huang JB, Liu YL, Yu CT, et al. Lung biopsy findings in previously inoperable patients with severe pulmonary hypertension associated with congenital heart disease. *Int J Cardiol.* 2011;151:76-83.
- 4.** Klingler JR, Elliott CG, Levine DJ, et al. Therapy for pulmonary arterial hypertension in adults: update of the CHEST guideline and expert panel report. *Chest.* 2019;155:565-586.
- 5.** Pi H, Kosanovich CM, Handen A, et al. Outcomes of pulmonary arterial hypertension are improved in a specialty care center. *Chest.* 2020;158:330-340.
- 6.** Liu Y, Li Y, Zhang J, et al. Pregnancy outcomes of women with Eisenmenger syndrome: a single-center study. *Int J Cardiol.* 2023;374:35-41.
- 7.** Sharma B, Sikka P, Chopra S, et al. Pregnancy in Eisenmenger syndrome: a case series from a tertiary care hospital of Northern India. *Cardiol Young.* 2023;33:2185-2189.
- 8.** Zhang Q, Zhu F, Shi G, et al. Maternal outcomes among pregnant women with congenital heart disease-associated pulmonary hypertension. *Circulation.* 2023;147:549-561.
- 9.** Galie N, Beghetti M, Gatzoulis MA, et al. Bosentan therapy in patients with Eisenmenger syndrome: a multicenter, double-blind, randomized, placebo-controlled study. *Circulation.* 2006;114:48-54.
- 10.** Gatzoulis MA, Landzberg M, Beghetti M, et al. Evaluation of macitentan in patients with Eisenmenger Syndrome. *Circulation.* 2019;139:51-63.
- 11.** Mukhopadhyay S, Nathani S, Yusuf J, et al. Clinical efficacy of phosphodiesterase-5 inhibitor tadalafil in Eisenmenger syndrome randomized, placebo-controlled, double-blind crossover study. *Congenit Heart Dis.* 2011;6:424-431.
- 12.** Sun YJ, Yang T, Zeng WJ, et al. Impact of sildenafil on survival of patients with Eisenmenger syndrome. *J Clin Pharmacol.* 2013;53:611-618.
- 13.** Hou Y, Wen L, Shu T, et al. Efficacy and safety of pulmonary vasodilators in the patients with Eisenmenger syndrome: a meta-analysis of randomized controlled trials. *Pulm Circ.* 2021;11:20458940211015823.
- 14.** D’Alto M, Romeo E, Argiento P, et al. Bosentan-sildenafil association in patients with congenital heart disease-related pulmonary arterial hypertension and Eisenmenger physiology. *Int J Cardiol.* 2012;155:378-382.
- 15.** Mohammed S, Vijayvergiya R, Malhotra S, Rohit MK. A randomized, double-blind, placebo-controlled study to evaluate sildenafil, ambrisentan combination therapy in pulmonary hypertension, particularly of Eisenmenger syndrome. *Indian Heart J.* 2021;73:633-636.
- 16.** Diller GP, Dimopoulos K, Broberg CS, et al. Presentation, survival prospects, and predictors of death in Eisenmenger syndrome: a combined retrospective

- and case-control study. *Eur Heart J*. 2006;27:1737-1742.
17. Cantor WJ, Harrison DA, Moussadji JS, et al. Determinants of survival and length of survival in adults with Eisenmenger syndrome. *Am J Cardiol*. 1999;84:677-681.
18. Khairy P. Arrhythmias in adults with congenital heart disease: what the practicing cardiologist needs to know. *Can J Cardiol*. 2019;35:1698-1707.
19. Becker-Grunic T, Klose H, Ehlken N, et al. Efficacy of exercise training in pulmonary arterial hypertension associated with congenital heart disease. *Int J Cardiol*. 2013;168:375-381.
20. Martinez-Quintana E, Miranda-Calderin G, Ugarte-Lopetegui A, Rodriguez-Gonzalez F. Rehabilitation program in adult congenital heart disease patients with pulmonary hypertension. *Congenit Heart Dis*. 2010;5:44-50.
21. Chon MK, Cho KI, Cha KS, et al. Effects of long-term iloprost treatment on right ventricular function in patients with Eisenmenger syndrome. *J Cardiol*. 2017;69:741-746.
22. D'Alto M, Constantine A, Balint OH, et al. The effects of parenteral prostacyclin therapy as add-on treatment to oral compounds in Eisenmenger syndrome. *Eur Respir J*. 2019;54:1901401.
23. Sandoval J, Santos LE, Cordova J, et al. Does anticoagulation in Eisenmenger syndrome impact long-term survival? *Congenit Heart Dis*. 2012;7:268-276.
24. Diller GP, Korten MA, Bauer UM, et al. Current therapy and outcome of Eisenmenger syndrome: data of the German National Register for congenital heart defects. *Eur Heart J*. 2016;37:1449-1455.
25. Oechslin E, Mebus S, Schulze-Neick I, et al. The adult patient with Eisenmenger Syndrome: a medical update after Dana Point part III: specific management and surgical aspects. *Curr Cardiol Rev*. 2010;6:363-372.
26. Shohtsu A, Takeuchi S, Inoue T. Surgical indications and results for congenital cardiac anomalies associated with left to right shunt and severe pulmonary hypertension. *Jpn Circ J*. 1976;40:629-632.
27. Blackstone EH, Kirklin JW, Bradley EL, et al. Optimal age and results in repair of large ventricular septal defects. *J Thorac Cardiovasc Surg*. 1976;72:661-679.
28. Balzer DT, Kort HW, Day RW, et al. Inhaled nitric oxide as a preoperative test (INOP Test I): the INOP Test Study Group. *Circulation*. 2002;106(12 Suppl 1):I76-I81.
29. Khairy P, Van Hare GF, Balaji S, et al. PACES/HRS expert consensus statement on the recognition and management of arrhythmias in adult congenital heart disease. *Heart Rhythm*. 2014;11:e102-e165.
30. Khairy P, Landzberg MJ, Gatzoulis MA, et al. Transvenous pacing leads and systemic thromboemboli in patients with intracardiac shunts: a multicenter study. *Circulation*. 2006;113:2391-2397.
31. van Dissel AC, D'Alto M, Farro A, et al. Improved risk prediction using a refined European guidelines instrument in pulmonary arterial hypertension related to congenital heart disease. *Am J Cardiol*. 2024;223:28-34.
32. Kempny A, Dimopoulos K, Uebing A, et al. Reference values for exercise limitations among adults with congenital heart disease. Relation to activities of daily life single centre experience and review of published data. *Eur Heart J*. 2012;33:1386-1396.
33. Moons P, Luyckx K, Thomet C, et al. Physical functioning, mental health, and quality of life in different congenital heart defects: comparative analysis in 3538 patients from 15 countries. *Can J Cardiol*. 2021;37:215-223.
34. Dimopoulos K, Inuzuka R, Goletto S, et al. Improved survival among patients with Eisenmenger syndrome receiving advanced therapy for pulmonary arterial hypertension. *Circulation*. 2010;121:20-25.
35. Arnott C, Strange G, Bullock A, et al. Pulmonary vasodilator therapy is associated with greater survival in Eisenmenger syndrome. *Heart*. 2017. heartjnl-2017-311876.
36. Kempny A, Hjortshøj CS, Gu H, et al. Predictors of death in contemporary adult patients with Eisenmenger Syndrome: a multicenter study. *Circulation*. 2017;135:1432-1440.
37. Humbert M, Kovacs G, Hoeper MM, et al. 2022 ESC/ERS guidelines for the diagnosis and treatment of pulmonary hypertension. *Eur Heart J*. 2022;43:3618-3731.
38. Diller GP, Alonso-Gonzalez R, Kempny A, et al. B-type natriuretic peptide concentrations in contemporary Eisenmenger syndrome patients: predictive value and response to disease targeting therapy. *Heart*. 2012;98:736-742.
39. Van De Bruaene A, De Meester P, Voigt JU, et al. Worsening in oxygen saturation and exercise capacity predict adverse outcome in patients with Eisenmenger syndrome. *Int J Cardiol*. 2013;168:1386-1392.
40. Mehta LS, Warnes CA, Bradley E, et al. Cardiovascular considerations in caring for pregnant patients: a scientific statement from the American Heart Association. *Circulation*. 2020;141:e884-e903.
41. Kevane B, Allen S, Walsh K, et al. Dual endothelin-1 receptor antagonism attenuates platelet-mediated derangements of blood coagulation in Eisenmenger syndrome. *J Thromb Haemost*. Published May 26, 2018. <https://doi.org/10.1111/jth.14159>
42. Bedan M, Grimm D, Wehland M, et al. A focus on macitentan in the treatment of pulmonary arterial hypertension. *Basic Clin Pharmacol Toxicol*. 2018;123:103-113.
43. Luna-Lopez R, Segura de la Cal T, Sarnago Cebada F, et al. Triple vasodilator therapy in pulmonary arterial hypertension associated with congenital heart disease. *Heart*. 2024;110:346-352.
44. Drakopoulou M, Nashat H, Kempny A, et al. Arrhythmias in adult patients with congenital heart disease and pulmonary arterial hypertension. *Heart*. 2018;104:1963-1969.
45. Nashat H, Kempny A, Harries C, et al. A single-centre, placebo-controlled, double-blind randomised cross-over study of nebulised iloprost in patients with Eisenmenger syndrome: a pilot study. *Int J Cardiol*. 2020;299:131-135.
46. Broberg CS, Ujita M, Prasad S, et al. Pulmonary arterial thrombosis in Eisenmenger syndrome is associated with biventricular dysfunction and decreased pulmonary flow velocity. *J Am Coll Cardiol*. 2007;50:634-642.
47. Daliento L, Somerville J, Presbitero P, et al. Eisenmenger syndrome. Factors relating to deterioration and death. *Eur Heart J*. 1998;19:1845-1855.
48. Ammash N, Warnes CA. Cerebrovascular events in adult patients with cyanotic congenital heart disease. *J Am Coll Cardiol*. 1996;28:768-772.
49. Jensen AS, Broberg CS, Rydman R, et al. Impaired right, left, or biventricular function and resting oxygen saturation are associated with mortality in Eisenmenger Syndrome: a clinical and cardiovascular magnetic resonance study. *Circ Cardiovasc Imaging*. 2015;8:e00359.
50. Hjortshøj CMS, Kempny A, Jensen AS, et al. Past and current cause-specific mortality in Eisenmenger syndrome. *Eur Heart J*. 2017;38:2060-2067.
51. Connolly SJ, Ezekowitz MD, Yusuf S, et al. Dabigatran versus warfarin in patients with atrial fibrillation. *N Engl J Med*. 2009;361:1139-1151.
52. Khairy P, Aboulhosn J, Broberg CS, et al. Thromboprophylaxis for atrial arrhythmias in congenital heart disease: a multicenter study. *Int J Cardiol*. 2016;223:729-735.
53. Martinez-Sande JL, Minguito-Carazo C, Gonzalez-Melchor L. Leadless pacemaker implantation in Eisenmenger syndrome. *Rev Esp Cardiol (Engl Ed)*. 2023;76:211.
54. Khairy P, Mondésert B, Mongeon FP, et al. Leadless atrioventricular synchronous pacing in Eisenmenger syndrome. *HeartRhythm Case Reports*. 2021;7:538-541.
55. Rosenkranz S, Ghofrani HA, Beghetti M, et al. Riociguat for pulmonary arterial hypertension associated with congenital heart disease. *Heart*. 2015;101:1792-1799.
- #### 4.5.1. Anomalous Aortic Origin of a Coronary Artery
1. Nagashima K, Hiro T, Fukamachi D, et al. Anomalous origin of the coronary artery coursing between the great vessels presenting with a cardiovascular event (J-CONOMALY Registry). *Eur Heart J Cardiovasc Imaging*. 2020;21:222-230.
2. Albrecht MH, Varga-Szemes A, Schoepf UJ, et al. Diagnostic accuracy of noncontrast self-navigated free-breathing MR angiography versus CT angiography: a prospective study in pediatric patients with suspected anomalous coronary arteries. *Acad Radiol*. 2019;26:1309-1317.
3. Cheezum MK, Ghoshhajra B, Bittencourt MS, et al. Anomalous origin of the coronary artery arising from the opposite sinus: prevalence and outcomes in patients undergoing coronary CTA. *Eur Heart J Cardiovasc Imaging*. 2017;18:224-235.
4. Molossi S, Agrawal H, Mery CM, et al. Outcomes in anomalous aortic origin of a coronary artery following a prospective standardized approach. *Circ Cardiovasc Interv*. 2020;13:e008445.
5. Wang TKM, Dong T, Cremer PC, et al. Utility of positron emission tomography myocardial perfusion imaging for identifying ischemia and guiding

treatment in patients with anomalous coronary arteries. *J Nucl Cardiol.* 2023;30:781-789.

6. Blomjous MSH, Budde RPJ, Bekker MWA, et al. Clinical outcome of anomalous coronary artery with interarterial course in adults: single-center experience combined with a systematic review. *Int J Cardiol.* 2021;335:32-39.

7. Warner ED, Gulati A, Halpern E, et al. Clinical outcomes in adult patients with an anomalous right coronary artery from the left sinus of valsalva. *Am J Cardiol.* 2023;204:122-129.

8. Gräni C, Benz DC, Steffen DA, et al. Outcome in middle-aged individuals with anomalous origin of the coronary artery from the opposite sinus: a matched cohort study. *Eur Heart J.* 2017;38:2009-2016.

9. Jiang MX, Blackstone EH, Karamlou T, et al. Anomalous aortic origin of a coronary artery in adults. *Ann Thorac Surg.* 2021;112:1299-1305.

10. Finocchiaro G, Behr ER, Tanzarella G, et al. Anomalous coronary artery origin and sudden cardiac death: clinical and pathological insights from a national pathology registry. *JACC Clin Electrophysiol.* 2019;5:516-522.

11. Angelini P. Imaging approaches for coronary artery anomalies: purpose and techniques. *Curr Cardiol Rep.* 2019;21:101.

12. Baumgartner H, de Backer J, Babu-Narayan SV, et al. 2020 ESC guidelines for the management of adult congenital heart disease. *Eur Heart J.* 2021;42:563-645.

13. Gentile F, Castiglione V, De Caterina R. Coronary artery anomalies. *Circulation.* 2021;144:983-996.

14. Eckart RE, Scoville SL, Campbell CL, et al. Sudden death in young adults: a 25-year review of autopsies in military recruits. *Ann Intern Med.* 2004;141:829-834.

15. Gaudino M, Di Franco A, Arbustini E, et al. Management of adults with anomalous aortic origin of the coronary arteries: state-of-the-art review. *J Am Coll Cardiol.* 2023;82:2034-2053.

16. Noel C. Cardiac stress MRI evaluation of anomalous aortic origin of a coronary artery. *Congenit Heart Dis.* 2017;12:627-629.

17. Doan TT, Molossi S, Sachdeva S, et al. Dobutamine stress cardiac MRI is safe and feasible in pediatric patients with anomalous aortic origin of a coronary artery (AAOCA). *Int J Cardiol.* 2021;334:42-48.

18. Verheijen D, Egorova AD, Jongbloed MRM, et al. Fractional flow reserve in anomalous aortic origin of coronary arteries to evaluate hemodynamic

consequences of high risk anatomical features. *Eur Heart J.* 2023;44(Suppl 2):ehad655.1913.

19. Eckart RE, Jones SOT, Shry EA, et al. Sudden death associated with anomalous coronary origin and obstructive coronary disease in the young. *Cardiol Rev.* 2006;14:161-163.

20. Taylor AJ, Rogan KM, Virmani R. Sudden cardiac death associated with isolated congenital coronary artery anomalies. *J Am Coll Cardiol.* 1992;20:640-647.

21. Krasuski RA, Magyar D, Hart S, et al. Long-term outcome and impact of surgery on adults with coronary arteries originating from the opposite coronary cusp. *Circulation.* 2011;123:154-162.

22. Stout KK, Daniels CJ, Aboulhosn JA, et al. 2018 AHA/ACC guideline for the management of adults with congenital heart disease: a report of the American College of Cardiology/American Heart Association Task Force on Clinical Practice Guidelines. *J Am Coll Cardiol.* 2019;73:e81-e192.

#### 4.5.2. Anomalous Coronary Artery Arising From the Pulmonary Artery

1. Ling Y, Bhusan S, Fan Q, Tang M. Midterm outcome after surgical correction of anomalous left coronary artery from the pulmonary artery. *J Cardiothorac Surg.* 2016;11:137.

2. Guenther TM, Sherazee EA, Wisneski AD, et al. Anomalous origin of the right coronary artery from the pulmonary artery: a systematic review. *Ann Thorac Surg.* 2020;110:1063-1071.

3. Yau JM, Singh R, Halpern EJ, Fischman D. Anomalous origin of the left coronary artery from the pulmonary artery in adults: a comprehensive review of 151 adult cases and a new diagnosis in a 53-year-old woman. *Clin Cardiol.* 2011;34:204-210.

4. Chahal NK, Horak JG, Thalji NK, et al. Left coronary artery reimplantation for repair of anomalous origin of the left coronary artery from the pulmonary artery in an adult. *J Cardiothorac Vasc Anesth.* 2023;37:2098-2108.

#### 4.5.3. Coronary Artery Fistula

1. Yildiz A, Okcun B, Peker T, et al. Prevalence of coronary artery anomalies in 12,457 adult patients who underwent coronary angiography. *Clin Cardiol.* 2010;33:E60-E64.

2. Al-Hijji M, El Sabbagh A, El Hajj S, et al. Coronary artery fistulas: indications, techniques, outcomes, and complications of transcatheter fistula closure. *JACC Cardiovasc Interv.* 2021;14:1393-1406.

3. Said SM, Burkhart HM, Schaff HV, et al. Late outcome of repair of congenital coronary artery fistulas—a word of caution. *J Thorac Cardiovasc Surg.* 2013;145:455-460.

4. Valente AM, Lock JE, Gauvreau K, et al. Predictors of long-term adverse outcomes in patients with congenital coronary artery fistulae. *Circ Cardiovasc Interv.* 2010;3:134-139.

#### 4.6. Vascular Rings and Pulmonary Artery Slings

1. Madueme PC. Computed tomography and magnetic resonance imaging of vascular rings and other things: a pictorial review. *Pediatr Radiol.* 2022;52:1839-1848.

2. Rato J, Zidere V, François K, et al. Post-operative outcomes for vascular rings: a systematic review and meta-analysis. *J Pediatr Surg.* 2023;58:1744-1753.

3. Porcaro F, Ciliberti P, Petreschi F, et al. Long term respiratory morbidity in patients with vascular rings: a review. *Ital J Pediatr.* 2023;49:24.

4. Stoica SC, Lockowandt U, Coulden R, et al. Double aortic arch masquerading as asthma for thirty years. *Respiration.* 2002;69:92-95.

5. Lone GN, Rathore SS, Malik JA, et al. Double aortic arch masquerading as bronchial asthma for five decades. *Asian Cardiovasc Thorac Ann.* 2012;20:338-340.

6. Lodeweges JE, Dikkers FG, Mulder BJM, et al. The natural and unnatural history of congenital aortic arch abnormalities evaluated in an adult survival cohort. *Can J Cardiol.* 2019;35:438-445.

7. Parker JM, Cary-Freitas B, Berg BW. Symptomatic vascular rings in adulthood: an uncommon mimic of asthma. *J Asthma.* 2000;37:275-280.

8. Ctori E, Crucean A, Pinkey B, et al. Morphology of vascular ring arch anomalies influences prognosis and management. *Arch Dis Child.* 2021;106:477-483.

---

**KEY WORDS** ACC/AHA clinical practice guideline, adult congenital heart disease, aortic coarctation, aortic valve stenosis, cardiac catheterization, cardiac surgical procedures, congenital heart disease, cor triatriatum, coronary vessel anomalies, diagnostic imaging, discrete subaortic stenosis, ductus arteriosus, patent, Ebstein anomaly, follow-up studies, heart defects, congenital, heart septal defects, ventricular, mortality, pulmonary valve stenosis, reoperation, surgery, survival rate, tetralogy of Fallot, therapy, transposition of great vessels, treatment outcome, ventricular outflow obstruction

**APPENDIX 1. AUTHOR RELATIONSHIPS WITH INDUSTRY AND OTHER ENTITIES—2025 ACC/AHA/HRS/ISACHD/SCAI GUIDELINE FOR THE MANAGEMENT OF ADULTS WITH CONGENITAL HEART DISEASE**

<b>Committee Member</b>	<b>Employment</b>	<b>Consultant</b>	<b>Speakers Bureau</b>	<b>Ownership/ Partnership/ Principal</b>	<b>Personal Research</b>	<b>Institutional, Organizational, or Other Financial Benefit</b>	<b>Expert Witness</b>
Michelle Gurvitz (Chair)	Harvard Medical School—Associate Professor of Pediatrics, Program Director, Adult Congenital Heart Disease Fellowship; Boston Children's Hospital—Wellbeing Director, Department of Cardiology	None	None	None	NOT RELEVANT ■ NIH*	None	None
Eric V. Krieger (Co-Vice Chair)	University of Washington—Professor of Medicine, Director, Seattle Adult Congenital Heart Service, Director, Adult Congenital Heart Disease Fellowship	None	None	None	None	None	None
Stephanie Fuller (Co-Vice Chair)	University of Pennsylvania Perelman School of Medicine—Professor of Clinical Surgery; The Children's Hospital of Philadelphia—Program Director, Congenital Cardiothoracic Surgery	RELEVANT ■ Edwards Lifesciences ■ W.L. Gore & Associates	None	None	None	None	None
Jamil A. Aboulhosn	UCLA—Professor of Clinical Medicine, Streisand Chair in Cardiology	NOT RELEVANT ■ Siemens Medical Solutions USA RELEVANT ■ Edwards Lifesciences* ■ Medtronic USA* ■ Zoll Medical	None	None	RELEVANT ■ Venus MedTech*	None	None
Elisa A. Bradley	The Pennsylvania State University—Associate Professor, Department of Medicine, Division of Cardiology, Associate Professor, Department of Cellular and Molecular Physiology	None	None	None	None	None	None
Jonathan Buber	University of Washington—Professor of Medicine	None	None	None	None	None	None
Curt J. Daniels	The Ohio State University Nationwide Children's Hospital—Shepard Professor of Cardiovascular Medicine Section Chief, Columbus Ohio Adult Congenital Heart Program	RELEVANT ■ Medtronic USA*	None	None	None	NOT RELEVANT ■ ABIM	None
Leslie L. Davis	University of North Carolina, Chapel Hill—Associate Professor, Acute, Tertiary and Specialty Care Innovations Division, School of Nursing	None	None	None	NOT RELEVANT ■ AANP* ■ UNC-Chapel Hill-REHEARSe (PI)*	NOT RELEVANT ■ AANP ■ ACC ■ AHA ■ Nursing Clinics of North America ■ PCNA ■ The Journal for Nurse Practitioners*	None
Steven DeMaio	Hollister Group—Editor; American College of Physicians—Medical Editor	None	None	None	None	None	None

Continued on the next page

## APPENDIX 1. CONTINUED

Committee Member	Employment	Consultant	Speakers Bureau	Ownership/ Partnership/ Principal	Personal Research	Institutional, Organizational, or Other Financial Benefit	Expert Witness
Konstantinos Dimopoulos	Royal Brompton Hospital, Guys St Thomas NHS Trust—Cardiologist	RELEVANT ■ Janssen Biotech	None	None	None	NOT RELEVANT ■ Aristotle University of Thessaloniki† ■ Beijing Science and Technology Innovation Medical Development Foundation* ■ Birmingham Childrens Hospital, ■ Hospital for Sick Children, University of Toronto ■ National and Kapodistrian University of Athens ■ Università degli Studi di Bari Aldo Moro ■ Università degli Studi di Verona RELEVANT ■ Janssen Biotech	None
Alexander Egbe	Mayo Clinic—Professor of Medicine	None	None	None	None	None	None
Tracy R. Geoffrion	Duke University Medical Center—Associate Professor of Surgery, Surgical Director of Adult Congenital Heart Disease	None	None	None	NOT RELEVANT ■ AATS Foundation* ■ Herma Heart Institute* ■ Project Bubaloo*	None	None
Anitha John	George Washington University School of Medicine and Health Sciences—Professor of Pediatrics; Children's National Hospital—Medical Director, Washington Adult Congenital Heart Program	None	None	None	NOT RELEVANT ■ PCORI*	None	None
Paul Khairy	Montreal Heart Institute—Professor of Medicine, Université de Montréal, Scientific Director, Adult Congenital Heart Center, Endowed Chair in Congenital Heart Disease and Electrophysiology	None	None	None	NOT RELEVANT ■ Hamilton Health Sciences (DSMB) RELEVANT ■ Bayer*	NOT RELEVANT ■ ACC ■ ISACHD† RELEVANT ■ M-Health Solutions*	None
Yuli Y. Kim	University of Pennsylvania Perelman School of Medicine—Associate Professor of Medicine (Cardiovascular Medicine), Medical Director of the Philadelphia Adult Congenital Heart Center	NOT RELEVANT ■ Adult Congenital Heart Association† ■ Merck	None	None	None	NOT RELEVANT ■ ABIM ■ ISACHD† ■ JACC	None
Michelle M. Kittleson	Cedars-Sinai Heart Institute—Cardiologist	None	None	None	None	None	None

Continued on the next page

**APPENDIX 1. CONTINUED**

<b>Committee Member</b>	<b>Employment</b>	<b>Consultant</b>	<b>Speakers Bureau</b>	<b>Ownership/ Partnership/ Principal</b>	<b>Personal Research</b>	<b>Institutional, Organizational, or Other Financial Benefit</b>	<b>Expert Witness</b>
Jacqueline Kreutzer	University of Pittsburgh—Professor of Pediatrics, Division Director, Cardiology; UPMC Children’s Hospital of Pittsburgh—Peter and Ada Rossin Endowed Chair in Pediatric Cardiology, Co-Director of the Heart Institute	RELEVANT <ul style="list-style-type: none"> <li>■ Medtronic USA</li> </ul>	None	None	RELEVANT <ul style="list-style-type: none"> <li>■ Edwards Lifesciences*</li> <li>■ Medtronic USA*</li> </ul>	None	None
Matthew J. Lewis	Columbia University Medical Center—Co-Director of the Adult Single Ventricle Clinic, Director of the Adult Congenital Heart Disease Research Program	NOT RELEVANT <ul style="list-style-type: none"> <li>■ ACC</li> </ul>	None	None	NOT RELEVANT <ul style="list-style-type: none"> <li>■ David Geffen School of Medicine at UCLA</li> <li>■ NewYork-Presbyterian/ Columbia University Medical Center*</li> <li>■ NHLBI (Co-PI)*</li> <li>■ NHLBI (PI)*</li> <li>■ PCORI (PI)*</li> </ul>	NOT RELEVANT <ul style="list-style-type: none"> <li>■ NHLBI (Co-investigator)*</li> </ul>	None
Jonathan N. Menachem	Vanderbilt University—Associate Professor of Medicine, Division of Cardiovascular Medicine, Associate Director of Heart Transplantation, Director of Advanced Congenital Cardiac Therapies	None	None	None	None	None	None
Jeremy P. Moore	UCLA—Clinical Professor, Pediatrics	NOT RELEVANT <ul style="list-style-type: none"> <li>■ ACC</li> <li>■ AltaThera Pharmaceutical</li> <li>■ Children’s Mercy Hospital</li> </ul> RELEVANT <ul style="list-style-type: none"> <li>■ Biosense Webster</li> </ul>	RELEVANT <ul style="list-style-type: none"> <li>■ Abbott Laboratories</li> </ul>	None	None	None	None
Kathryn A. Osteen	Baylor University Louise Herrington School of Nursing—Clinical Professor, Associate Dean for the Pre-Licensure Program	None	None	None	None	NOT RELEVANT <ul style="list-style-type: none"> <li>■ The Children’s Heart Foundation†</li> <li>■ CHPHC†</li> </ul>	None
Puja B. Parikh	Stony Brook University Renaissance School of Medicine—Associate Professor of Medicine; Stony Brook University Medical Center—Director, Transcatheter Aortic Valve Replacement Program	None	RELEVANT <ul style="list-style-type: none"> <li>■ Medtronic</li> </ul>	None	RELEVANT <ul style="list-style-type: none"> <li>■ Abbott Laboratories (PI)</li> <li>■ Edwards Lifesciences (PI)</li> </ul>	None	None
Arwa Saidi	University of Florida—Professor	None	None	None	NOT RELEVANT <ul style="list-style-type: none"> <li>■ PCORI*</li> </ul>	None	None
Katherine B. Saliccioli	Baylor College of Medicine—Assistant Professor of Internal Medicine and Pediatrics; Program Director, Adult Congenital Heart Disease Fellowship	None	None	None	None	None	None
Rachel L. Schunder‡	American Heart Association/ American College of Cardiology—Science & Health Advisor, Guidelines	None	None	None	None	None	None

*Continued on the next page*

## APPENDIX 1. CONTINUED

Committee Member	Employment	Consultant	Speakers Bureau	Ownership/ Partnership/ Principal	Personal Research	Institutional, Organizational, or Other Financial Benefit	Expert Witness
Anne Marie Valente	Boston Children's Hospital—Director of the Boston Adult Congenital Heart Disease Program; Brigham and Women's Hospital—Co-Director, Pregnancy and Cardiovascular Disease Program; Harvard Medical School—Professor	NOT RELEVANT ■ ACCF*	None	None	None	NOT RELEVANT ■ Elsevier* ■ NHLBI*	None
Rachel M. Wald	University Health Network—Research Director, Adult Congenital Cardiac Clinic, Division of Cardiology, Peter Munk Cardiac Centre; University of Toronto—Professor	None	None	None	None	None	None

This table represents all relationships of committee members with industry and other entities that were reported by authors, including those not deemed to be relevant to this document, at the time this document was under development. The table does not necessarily reflect relationships with industry at the time of publication. A person is deemed to have a significant interest in a business if the interest represents ownership of  $\geq 5\%$  of the voting stock or share of the business entity, or ownership of  $\geq \$5,000$  of the fair market value of the business entity; or if funds received by the person from the business entity exceed 5% of the person's gross income for the previous year. Relationships that exist with no financial benefit are also included for the purpose of transparency. Relationships in this table are modest unless otherwise noted. Please refer to <https://www.acc.org/guidelines/about-guidelines-and-clinical-documents/relationships-with-industry-policy> for definitions of disclosure categories or additional information about the AHA/ACC Disclosure Policy for Writing Committees.

\*Significant relationship.

†No financial benefit.

‡Rachel L. Schunder is an AHA/ACC joint staff member and acts as the Science & Health Advisor for the ACC/AHA/HRS/ISACHD/SCAI Guideline for Adult Congenital Heart Disease. No relevant relationships to report. Nonvoting author on measures and not included/counted in the RWI balance for this committee.

AANP indicates American Association of Nurse Practitioners; AATS, American Association of Thoracic Surgery; ABIM, American Board of Internal Medicine; ACC, American College of Cardiology; ACCF, American College of Cardiology Foundation; AHA, American Heart Association; CHPHC, Congenital Heart Public Health Consortium; DSMB, data safety monitoring board; HRS, Heart Rhythm Society; ISACHD, International Society for Adult Congenital Heart Disease; JACC, *Journal of the American College of Cardiology*; KANPNM, Kentucky Association of Nurse Practitioners & Nurse-Midwives; MI, myocardial infarction; NCDR, National Cardiovascular Data Registry; NHLBI, National Heart, Lung, and Blood Institute; NIH, National Institutes of Health; NPACE, Nurse Practitioners Associates for Continuing Education; PCNA, Preventive Cardiovascular Nurses Association; PCORI, Patient-Centered Outcomes Research Institute; PI, principal investigator; SCAI, Society for Cardiovascular Angiography and Intervention; UCLA, University of California, Los Angeles; and UNC, University of North Carolina.

**APPENDIX 2. REVIEWER RELATIONSHIPS WITH INDUSTRY AND OTHER ENTITIES—2025 ACC/AHA/HRS/ISACHD/SCAI GUIDELINE FOR THE MANAGEMENT OF ADULTS WITH CONGENITAL HEART DISEASE**

Reviewer	Representation	Employment	Consultant	Speakers Bureau	Ownership/ Partnership/ Principal	Personal Research	Institutional, Organizational, or Other Financial Benefit	Expert Witness
Karen Stout, Chair	AHA/ACC ACHD Guideline Peer Review Committee	University of Washington—Associate Chief, Division of Cardiology and Professor, Internal Medicine and Pediatrics	None	None	None	None	None	None
Rafael Alonso-Gonzalez	AHA/ACC ACHD Guideline Peer Review Committee	University of Toronto—Assistant Professor, Department of Medicine; Toronto General Hospital—Director, ACHD Program	None	None	None	None	None	None
Luke Burchill	AHA/ACC ACHD Guideline Peer Review Committee	Mayo Clinic—Cardiologist	None	None	None	None	None	None
Rachael Cordina	AHA/ACC ACHD Guideline Peer Review Committee	HRI—Assistant Professor; Royal Prince Alfred Hospital—Staff Specialist; Aboriginal Health Service Redfern—Consultant Cardiologist	None	■ Johnson & Johnson	None	None	None	None
Stephen J. Dolgner	AHA/ACC ACHD Guideline Peer Review Committee	Baylor College of Medicine—Assistant Professor	None	None	None	None	None	None
Valeria Duarte	AHA/ACC ACHD Guideline Peer Review Committee	Houston Methodist Hospital—Cardiologist	None	None	None	None	None	None
Edward Hickey	AHA/ACC ACHD Guideline Peer Review Committee	Baylor College of Medicine—Congenital Heart Surgeon and Associate Professor of Surgery	■ Abbott Laboratories	None	None	None	None	None
Daniel S. Levi	AHA/ACC ACHD Guideline Peer Review Committee, representing SCAI	UCLA Health—Professor of Pediatrics	<ul style="list-style-type: none"> <li>■ Abbott Laboratories*</li> <li>■ B. Braun Interventional Systems*</li> <li>■ Balt USA</li> <li>■ Edwards Lifesciences*</li> <li>■ Inceptus Medical</li> <li>■ Medtronic</li> <li>■ Okami Medical</li> </ul>	None	None	None	None	None
Jeannette Lin	AHA/ACC ACHD Guideline Peer Review Committee	David Geffen School of Medicine at UCLA—Clinical Professor of Medicine	None	None	None	None	None	None
David C. Mauchley	AHA/ACC ACHD Guideline Peer Review Committee	University of Washington—Associate Professor of Surgery	None	None	None	None	None	None
Paula Miller	AHA/ACC ACHD Guideline Peer Review Committee	Adult Congenital Heart Association—Senior Education Manager	None	None	None	None	None	None

Continued on the next page

## APPENDIX 2. CONTINUED

Reviewer	Representation	Employment	Consultant	Speakers Bureau	Ownership/ Partnership/ Principal	Personal Research	Institutional, Organizational, or Other Financial Benefit	Expert Witness
Alexander Sasha Opatowsky	AHA/ACC ACHD Guideline Peer Review Committee	University of Cincinnati—Professor, Department of Pediatrics; Cincinnati Children’s—Director, ACHD Program	None	None	None	■ NHLBI (PI)*	■ Adult Congenital Heart Association† ■ Conquering CHD† ■ Fontan Outcomes Network† ■ ISACHD†	None
Andrew Pistner	AHA/ACC ACHD Guideline Peer Review Committee	University of Washington—Assistant Professor	None	None	None	None	None	None
Anitra W. Romfh	AHA/ACC ACHD Guideline Peer Review Committee	Stanford University School of Medicine—Clinical Associate Professor	None	None	None	None	None	None
Ada Stefanescu Schmidt	AHA/ACC ACHD Guideline Peer Review Committee	Massachusetts General Hospital—Interventional Cardiologist	None	None	None	■ Edward Lifesciences* ■ Occlutech*	■ Edward Lifesciences* ■ Medtronic* ■ Quidel	None
Zachary Steinberg	AHA/ACC ACHD Guideline Peer Review Committee	UW Medicine—Associate Professor, Medicine	■ Abbott Laboratories ■ B. Braun Medical* ■ Medtronic*	None	None	None	None	None
Karen Stout	AHA/ACC ACHD Guideline Peer Review Committee	University of Washington—Professor	None	None	None	None	None	None
Daniel Tobler	AHA/ACC ACHD Guideline Peer Review Committee, representing ISACHD	Universität Basel—Professor; University Hospital Basel—Cardiologist	None	None	None	None	None	None
Shane F. Tsai	AHA/ACC ACHD Guideline Peer Review Committee, representing HRS	University of Nebraska Medical Center—Associate Professor, Chief of Cardiovascular Medicine	None	■ Medtronic	None	None	■ Biosense Webster	None
Fred Ming-Chieh Wu	AHA/ACC ACHD Guideline Peer Review Committee	Harvard Medical School—Assistant Professor of Pediatrics; Boston Children’s Hospital—Cardiologist	None	None	None	■ Additional Ventures (PI)*	■ AARCC* ■ ACHA ■ AORN Foundation (Board of Directors) ■ ISACHD	None

This table represents all reviewers’ relationships with industry and other entities that were reported at the time of peer review, including those not deemed to be relevant to this document, at the time this document was under review. The table does not necessarily reflect relationships with industry at the time of publication. A person is deemed to have a significant interest in a business if the interest represents ownership of  $\geq 5\%$  of the voting stock or share of the business entity, or ownership of  $\geq \$5,000$  of the fair market value of the business entity; or if funds received by the person from the business entity exceed 5% of the person’s gross income for the previous year. Relationships that exist with no financial benefit are also included for the purpose of transparency. Relationships in this table are modest unless otherwise noted. Please refer to <https://www.acc.org/guidelines/about-guidelines-and-clinical-documents/relationships-with-industry-policy> for definitions of disclosure categories or additional information about the ACC/AHA Disclosure Policy for Writing Committees.

\*Significant relationship.

†No financial benefit.

AARCC indicates Alliance for Adult Research in Congenital Cardiology; ACC, American College of Cardiology; ACHA, Adult Congenital Heart Association; ACHD, adult congenital heart disease; AHA, American Heart Association; AORN, Association of periOperative Registered Nurses; CHD, congenital heart disease; HRI, Heart Research Institute; HRS, Heart Rhythm Society; ISACHD, International Society for Adult Congenital Heart Disease; NHLBI, National Heart, Lung, and Blood Institute; SCAI, Society for Cardiovascular Angiography & Interventions; UCLA, University of California, Los Angeles; and UW, University of Washington.